

Zeitschrift: Schweizer Archiv für Tierheilkunde SAT : die Fachzeitschrift für Tierärztinnen und Tierärzte = Archives Suisses de Médecine Vétérinaire
ASMV : la revue professionnelle des vétérinaires

Herausgeber: Gesellschaft Schweizer Tierärztinnen und Tierärzte

Band: 133 (1991)

Heft: 3

Artikel: Comparison of bronchoalveolar lavage and respiratory secretion cytology in horses with histologically diagnosed pulmonary disease

Autor: Winder, N.C. / Grüning, G. / Hermann, M.

DOI: <https://doi.org/10.5169/seals-589165>

Nutzungsbedingungen

Die ETH-Bibliothek ist die Anbieterin der digitalisierten Zeitschriften auf E-Periodica. Sie besitzt keine Urheberrechte an den Zeitschriften und ist nicht verantwortlich für deren Inhalte. Die Rechte liegen in der Regel bei den Herausgebern beziehungsweise den externen Rechteinhabern. Das Veröffentlichen von Bildern in Print- und Online-Publikationen sowie auf Social Media-Kanälen oder Webseiten ist nur mit vorheriger Genehmigung der Rechteinhaber erlaubt. [Mehr erfahren](#)

Conditions d'utilisation

L'ETH Library est le fournisseur des revues numérisées. Elle ne détient aucun droit d'auteur sur les revues et n'est pas responsable de leur contenu. En règle générale, les droits sont détenus par les éditeurs ou les détenteurs de droits externes. La reproduction d'images dans des publications imprimées ou en ligne ainsi que sur des canaux de médias sociaux ou des sites web n'est autorisée qu'avec l'accord préalable des détenteurs des droits. [En savoir plus](#)

Terms of use

The ETH Library is the provider of the digitised journals. It does not own any copyrights to the journals and is not responsible for their content. The rights usually lie with the publishers or the external rights holders. Publishing images in print and online publications, as well as on social media channels or websites, is only permitted with the prior consent of the rights holders. [Find out more](#)

Download PDF: 15.07.2025

ETH-Bibliothek Zürich, E-Periodica, <https://www.e-periodica.ch>

COMPARISON OF BRONCHOALVEOLAR LAVAGE AND RESPIRATORY SECRETION CYTOLOGY IN HORSES WITH HISTOLOGICALLY DIAGNOSED PULMONARY DISEASE

N. C. WINDER¹, G. GRÜNIG¹, M. HERMANN², R. VON FELLEBERG¹

SUMMARY

Equine bronchoalveolar lavage (BAL) fluid collected from 70 horses and respiratory secretions (RS) obtained from 61 of these horses were evaluated cytologically and grouped according to the histological diagnosis of the lungs from which they were obtained. The histological categories included: normal lung (8 horses); pulmonary eosinophilic infiltration (9 horses); interstitial pneumonia (5 horses); pulmonary hemorrhage (5 horses); and mild (12 horses), moderate (7 horses) and severe (24 horses) chronic small airway disease.

In horses with pulmonary disease, all BAL samples and all but one RS sample differed cytologically to those obtained from normal horses; however, the type and severity of the pulmonary disease could not always be determined using either BAL or RS cytology.

There was a positive association between the percentage of neutrophils in BAL and the neutrophil scores in RS specimens; there was no positive association between other cell types.

KEY WORDS: horses — bronchoalveolar lavage — respiratory secretions — cytology — histology

INTRODUCTION

Few studies have compared respiratory secretion (RS) and bronchoalveolar lavage (BAL) cytology with pulmonary histology in horses. *Larson and Busch* (1985) found little rela-

VERGLEICHENDE ZYTOLOGISCHE BEURTEILUNG VON BRONCHOALVEOLÄR-LAVAGEFLÜSSIGKEIT UND VON BRONCHIALSEKRET BEI PFERDEN MIT HISTOLOGISCH DIAGNOSTIZIERTER LUNGENKRANKHEIT

Bronchoalveolär-Lavageflüssigkeit (BAL) wurde von 70 Pferden und Bronchialsekret (BS) von 61 Individuen der gleichen Gruppe gesammelt, cytologisch beurteilt und den histologisch gestellten Diagnosen zugeordnet. Folgende Veränderungen wurden festgestellt: normale Lungen (8 Pferde); eosinophile Lungeninfiltration (9 Pferde); interstitielle Pneumonie (5 Pferde); Lungenbluten (5 Pferde); geringgradige (12 Pferde), mittelgradige (7 Pferde) und schwergradige (24 Pferde) chronische Lungenkrankheit. Alle BAL-Proben und, mit einer Ausnahme, auch alle BS-Proben der kranken Pferde unterschieden sich cytologisch von den Proben gesunder.

Die Art und das Ausmass der Lungenveränderung konnte jedoch nicht immer mittels cytologischer Untersuchung von BAL oder BS ermittelt werden. Es bestand eine Parallelität zwischen dem prozentualen Anteil an Neutrophilen Granulozyten in der BAL und dem geschätzten Anteil derselben Zellen im BS. Bei den anderen Zellarten waren keine Beziehungen feststellbar.

SCHLÜSSELWÖRTER: Pferde — bronchoalveolär Lavage — Bronchialsekret — Zytologie — Histologie

tionship between tracheobronchial lavage cytology and pulmonary histology in individual horses. Contrarily, in a study using a combination of diagnostic aids, including lung biopsy and post mortem examination, *Mair* (1987) concluded that tracheal lavage was a valuable aid to the diagnosis of chronic

pulmonary diseases. In addition, he suggested that BAL probably offers little advantage over tracheal lavage in routine clinical assessment of equine chronic pulmonary diseases. A recent study found that horses with moderate and severe chronic small airway disease and pulmonary hemorrhage could be consistently identified by cytological evaluation of RS; however, horses with mild chronic small airway disease, pulmonary eosinophilic infiltration and interstitial pneumonia did not always have RS cytology which differed from that of normal horses (Winder et al., 1989).

In a study of horses with histologically diagnosed small airway disease, BAL cytology was found to be a useful aid in determining the severity of the pulmonary disease (Viel, 1983). In another study, BAL was considered to be more of an aid in evaluating equine chronic lung disease than transtracheal aspirates (Derksen et al., 1989). As well, this study found no significant correlation between transtracheal aspiration and BAL cytology.

The purpose of this study was to compare RS and BAL cytological samples obtained from lungs with various histological diagnoses.

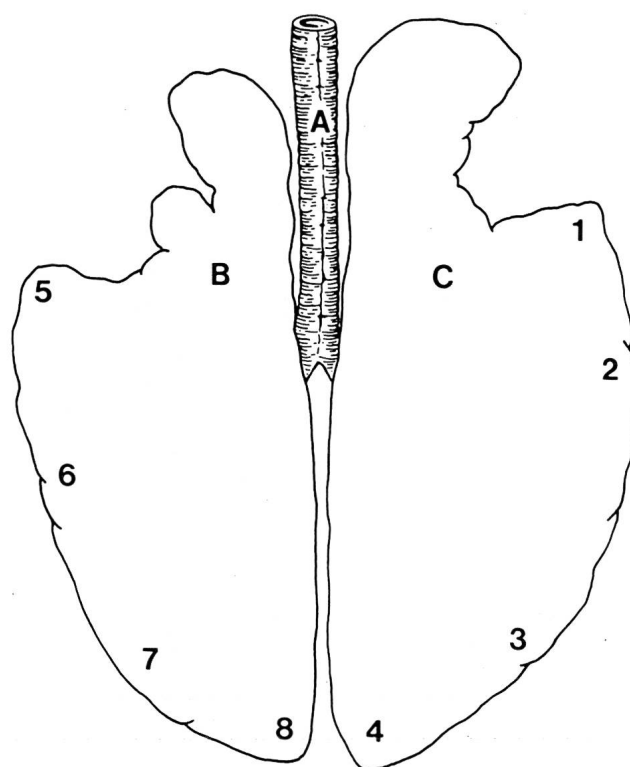
ANIMALS, MATERIALS AND METHODS

Patients: Bronchoalveolar lavage fluid and RS were obtained from 14 live horses. Bronchoalveolar lavage was performed in 56 horses lungs approximately 40 minutes after slaughter; RS were obtained from 47 of these lungs.

Cytological specimens: In live horses, BAL was performed as described (Viel, 1983). Briefly, the horses were sedated using xylazine/morphine. A flexible fiberoptic endoscope was advanced to the carina. Surface anaesthesia was carried out using approximately 50 to 100 ml of 1% lidocaine. The endoscope was advanced into a caudal bronchus until it could not be moved any further. Then, two 250 ml aliquots of pre-warmed (37 °C) 0.9% saline were infused into the lung and aspirated immediately using a vacuum of -7 to -9 mm/Hg. The lavage procedure was repeated in the other lung.

In slaughtered horses, the excised lungs were placed horizontally on a table and the trachea was opened as far as the major bronchi. Respiratory secretions were gently lifted or aspirated with a syringe and two to five direct smears were made. For BAL a polyethylene tube (6 mm in diameter) was advanced into either the right or left bronchus and then down a secondary bronchus until resistance was met. This was approximately 5 cm from the peripheral margin of the lung. Two 60 ml aliquots of warm (37 °C) phosphate buffered saline (PBS) containing 0.02% EDTA were infused into the lung using a syringe attached to the end of the tubing. Infusion of PBS

Fig. 1: Schematic representation of the equine lower respiratory tract depicting the areas which underwent bronchoalveolar lavage: A- trachea; B- left lung; C- right lung; 1, 2, 3, 4, 5, 6, 7, 8- areas of lung lavaged.



resulted in inflation of the lung parenchyma so that a bulge was clearly visible. However, in lungs with severe chronic small airway disease in which there was pulmonary overinflation, it was usually not possible to inflate the parenchyma. In addition, PBS often flowed back up the primary bronchus before the total amount of PBS could be infused. At the start of this study, PBS was collected by aspirating the lavage fluid with a 60 ml syringe. However, columnar epithelial cells were also aspirated in large numbers. Thus, lavage fluid was later collected by removing the syringe from the end of the polyethylene tubing and by withdrawing the tubing approximately 1 cm until the lavage fluid flowed back on its own through the tubing into a clean glass jar.

Lungs were not used if blood had been aspirated into both bronchi. Sometimes BAL was performed in only one lung if blood had been aspirated into the other lung. The lung areas lavaged are depicted in Figure 1.

Cytological examination: For RS, smears were stained with May-Grünwald-Giemsa stain and examined at 40x, 100x, and 1000x magnification. The occurrence of neutrophils, eosino-

phils, mast cells, lymphocytes and macrophages was scored semi-quantitatively: 1- cell type not seen; 2- very few cells; 3- widely scattered cells; 4- moderate numbers of cells; 5- moderate to many cells; 6- many cells; 7- massive numbers of cells.

The BAL fluid was filtered through a single layer of gauze. Bronchoalveolar lavage fluid from slaughtered horses was centrifuged at 400 g for 10 minutes. The cell pellets were resuspended in fetal calf serum and smears were made directly onto clean glass slides. For cytological evaluation of BAL fluid from live horses, 10 ml of lavage fluid was centrifuged at 400 g for 10 minutes. The cell pellet was resuspended in 10 ml RPMI 1640 medium (Gibco Ltd, Scotland). Cytocentrifuge (Cytospin Shandon, Instrumentgesellschaft, Zürich) smears were made by spinning 300 to 500 µl of the cell suspension and 50 µl of horse serum at 100 g for 10 minutes. Two smears for each lung were prepared. Throughout this study, BAL fluid collected from each lung area was processed separately to compare possible cytological differences between lung areas; however, the mean cell score of areas lavaged was used for statistical analysis. All preparations were stained with May-Grünwald-Giemsa and differential cell counts were performed by counting 400 cells at 1000x magnification. Cells counted included macrophages, neutrophils, eosinophils, mast cells and lymphocytes. At the beginning of this study, many epithelial cells had been aspirated from the bronchial/bronchiolar mucosa. Thus, it was felt that a representative cytological sample was not reflected by including these cells in the differential cell counts.

For both RS and BAL, cell scoring was performed by the same person and without knowledge of the histological diagnoses. Cytological results from RS and BAL were grouped according to the histological diagnosis of the lungs from which they were obtained.

Tissues: Pulmonary specimens were obtained from 70 horses approximately 40 minutes after slaughter. After visual and physical examination of the lungs, lung specimens were collected from the cranial, ventral, dorsal and caudal regions, from areas with gross lesions and from tissue in lavaged areas. Specimens were fixed in 10 per cent phosphate buffered formalin, embedded in paraffin, sectioned at 3 to 5 microns and stained with hematoxylin and eosin.

Sections were examined at magnifications of 40, 100, 200, 400 and 1000 times. Based on the predominant pulmonary histology, lungs were placed into one of the following categories (Winder, 1987): normal lung; pulmonary eosinophilic infiltration; interstitial pneumonia; pulmonary hemorrhage; mild, moderate and severe chronic small airway disease.

Statistical analysis: For statistical analysis the Statview 512+ system (Feldman and Gagnon, 1986) was used. Means of numbers of the different cell types in differential cell counts from BAL fluid were compared by analysis of variance and multiple comparisons using the method of least significant difference. For comparison of occurrences of various frequencies of the different cell types in RS, the chi-square test for association was used. In contingency tables with expected frequencies of less than one or with more than 20 percent of expected frequencies falling below five, rows and/or columns were combined such that requirements for contingency tables were met (Remington and Schork, 1970). In contingency tables with more than one degree of freedom, the error probability was corrected employing the Bonferroni-Holm test procedure (Essl, 1987) for testing the association within pairs of rows. For all analyses, $P < 0.05$ was considered significant.

RESULTS

Evaluation of 70 equine lungs resulted in the following histological categories: normal lung – 8 horses; pulmonary eosinophilic infiltration – 9 horses; interstitial pneumonia – 5 horses; pulmonary hemorrhage – 5 horses; mild, moderate and severe chronic small airway disease – 12, 7 and 24 horses, respectively.

There were no histological lesions in lungs categorized as normal. Lungs with mild eosinophilic infiltration had multifocal areas of atelectasis in anteroventral regions and predominantly mononuclear cell infiltration of collapsed and slightly thickened alveolar septa. Mild to moderate goblet cell hyperplasia was observed in bronchi and there was mild infiltration of eosinophils around bronchi, bronchioles and in alveolar septa. In 2 horses with severe eosinophilic infiltration there were multifocal subpleural nodules consisting of either parasitic larvae or calcified material in the centre surrounded by a layer of lymphocytes, eosinophils and finally a fibrous capsule. Moderate chronic bronchointerstitial pneumonia with infiltration of lymphocytes and eosinophils also was observed. The third horse in this category had severe eosinophilic bronchointerstitial pneumonia in the right anteroventral region. Horses with interstitial pneumonia had either acute interstitial pneumonia (2 horses) or chronic bronchointerstitial pneumonia (3 horses, one of which had lesions localized to the anteroventral regions). Five horses had pulmonary hemorrhage with lesions in the caudal lung lobes similar to those described for horses with exercise-induced pulmonary hemorrhage (EIPH, O'Callaghan et al., 1987). In addition, three horses with pulmonary eosinophilic infiltration, one horse with chronic bronchointerstitial pneumonia and two horses

Table 1: Mean differential cell counts and SEM of BAL fluid obtained from horses with various pulmonary histological diagnoses.

Histological (No) diagnosis	Neutrophils ± SEM	Eosinophils ± SEM	Mast cells ± SEM	Lymphocytes ± SEM	Macrophages ± SEM
Normal (8)	4.6 ± 0.9 ^a	0.2 ± 0.1 ^a	4.8 ± 0.5 ^a	28.7 ± 2.9 ^a	61.7 ± 2.7 ^a
Eosinophilic infiltration (9)	5.4 ± 1.9 ^a	2.1 ± 0.8 ^b	5.9 ± 1.1 ^a	38.0 ± 2.6	48.6 ± 2.8 ^b
Interstitial pneumonia (5)	22.2 ± 4.2	0.1 ± 0.1 ^a	1.7 ± 0.6 ^b	30.5 ± 1.9 ^a	45.5 ± 3.2 ^b
Pulmonary hemorrhage (5)	3.4 ± 1.6 ^a	0.1 ± 0.1 ^a	3.4 ± 0.6	30.0 ± 5.1	63.2 ± 6.7 ^a
Mild CSAD (12)	13.1 ± 2.7 ^a	0.1 ± 0.1 ^a	2.5 ± 0.4 ^b	41.9 ± 3.2 ^b	42.4 ± 2.9 ^b
Moderate CSAD (7)	20.7 ± 4.7 ^a	0.2 ± 0.2 ^a	3.9 ± 0.9	38.4 ± 1.7	36.8 ± 4.0 ^b
Severe CSAD (24)	46.0 ± 5.0 ^b	0.3 ± 0.1 ^a	1.7 ± 0.3 ^b	25.7 ± 2.3	26.3 ± 2.9 ^b

CSAD-chronic small airway disease.

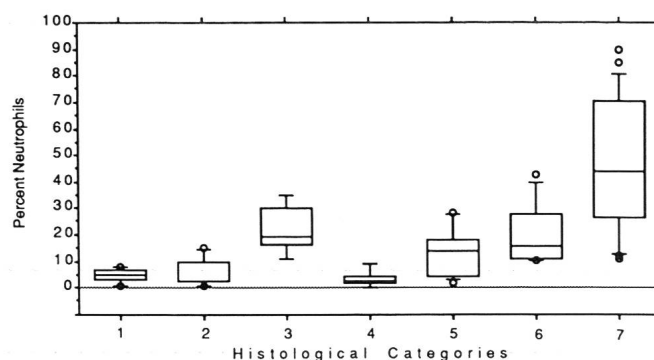
In each column means with different superscripts (a and b) differ statistically ($P < 0.05$).

with moderate chronic small airway disease had pulmonary hemorrhage. Horses with chronic small airway disease were divided into three groups i.e. mild, moderate and severe lesions as described by Viel (1983).

Bronchoalveolar lavage cytology: The means and standard error of means (SEM) of the differential cell counts obtained from BAL for each of the histological categories are shown in table 1. On a group basis, normal horses and horses with pulmonary hemorrhage had the highest percentage of macrophages in differential cell counts; however, horses with pulmonary hemorrhage had hemosiderocytes. A significantly higher percentage of eosinophils was observed in differential cell counts from the group of horses with pulmonary eosinophilic infiltration in comparison to all other categories. On a group basis, horses with mild chronic small airway disease had more lymphocytes in differential cell counts obtained from BAL fluid than normal horses and than horses with interstitial pneumonia. Figure 2 shows that although horses with moderate chronic small airway disease tended to have a higher percentage of neutrophils in BAL samples than horses with mild chronic small airway disease, there was overlapping of neutrophil percentages between the two groups and thus no significant difference. The group with severe chronic small airway disease had significantly more neutrophils and significantly fewer macrophages than all other groups.

On an individual basis, horses with pulmonary eosinophilic infiltration could be differentiated from normal horses by either a higher percentage of eosinophils (5 horses) or a higher percentage of lymphocytes (4 horses). Although not statistically significant on a group basis, each horse with interstitial pneumonia had a higher percentage of neutrophils in the differential cell count than normal horses. On an individual

Fig. 2: The percentage of neutrophils in BAL obtained from lungs with various histological diagnoses (box and whisker plots): 1- normal lung (n=8); 2- eosinophilic infiltration (n=9); 3- interstitial pneumonia (n=5); 4- pulmonary hemorrhage (n=5); 5- mild chronic small airway disease (n=12); 6- moderate chronic small airway disease (n=7); 7- severe chronic small airway disease (n=24). The box marks the 25th, 50th (= median) and 75th percentiles and the ends of the whiskers represent the 5th and 95th percentiles.



basis, horses with mild chronic small airway disease had either more neutrophils (7 horses) and/or more lymphocytes (7 horses) than normal horses. Each horse with moderate and severe chronic small airway disease had a higher percentage of neutrophils in differential cell counts than normal horses; however, individual differential cell counts for horses with interstitial pneumonia and mild, moderate and severe chronic small airway disease often overlapped.

In two horses with severe chronic small airway disease in which BAL was performed before slaughter, the percentage of neutrophils varied greatly between the right and left lungs (7 versus 60 % and 41 versus 88 %); however, the histological

BRONCHOALVEOLAR LAVAGE AND RESPIRATORY SECRETION CYTOLOGY

Table 2: Mean cell scores and SEM of RS samples obtained from horses with various pulmonary histological diagnoses.

Histological diagnosis (No.)	Neutrophils ± SE	Eosinophils ± SE	Mast cells ± SE	Lymphocytes ± SE	Macrophages ± SE
Normal (6)	3.2 ± 0.4 ^a	2.0 ± 0.4 ^a	3.0 ± 0	3.5 ± 0.5 ^a	4.8 ± 0.8
Eosinophilic infiltration (8)	4.1 ± 0.6 ^a	3.1 ± 0.3 ^b	2.9 ± 0.2	3.6 ± 0.4	5.4 ± 0.3
Interstitial pneumonia (4)	6.2 ± 0.5	1.5 ± 0.5 ^a	2.8 ± 0.2	4.0 ± 0	5.2 ± 0.5
Pulmonary hemorrhage (3)	4.3 ± 1.2 ^a	2.0 ± 0.6 ^a	2.7 ± 0.3	3.3 ± 0.7 ^a	5.0 ± 0.6
Mild CSAD (9)	5.4 ± 0.5	1.9 ± 0.3 ^a	2.4 ± 0.2	4.3 ± 0.4	5.0 ± 0.4
Moderate CSAD (6)	6.5 ± 0.3	1.7 ± 0.4 ^a	2.2 ± 0.2	4.2 ± 0.2	4.8 ± 0.3
Severe CSAD (22)	7.0 ± 0.1 ^b	1.9 ± 0.2 ^a	2.2 ± 0.2	4.6 ± 0.1 ^b	4.9 ± 0.2

CSAD-chronic small airway disease.

Cell scores: 1- cell type not seen; 2- very few cells; 3- widely scattered cells; 4- moderate numbers of cells; 5- moderate to many cells; 6- many cells; 7- massive numbers of cells.

In each column means with different superscripts (a and b) differ statistically ($P < 0.05$).

lesions were similar in both lungs. In one horse with chronic bronchointerstitial pneumonia localized to the anteroventral regions and one horse with severe eosinophilic infiltration restricted to the anteroventral region of one lung, differential cell counts varied between regions lavaged. This was also true for five lungs in which the intensity of the lesions varied between lobes. Each differential cell count correlated well with the histology of the lung region from which it was obtained. However, by pooling the individual lavage samples for each lung, a dilution of specific cell types (e. g. neutrophils or eosinophils) resulted in a poorer correlation with the histological diagnosis.

There was no difference in differential cell counts performed on lavage fluid collected in live horses and those performed on lavage fluid obtained after slaughter.

Respiratory secretions: Table 2 depicts the mean cell scores and SEM of RS for each histological category. On a group basis, horses with severe chronic small airway disease had significantly more neutrophils and lymphocytes in RS than normal horses. As a group, horses with pulmonary eosinophilic infiltration had significantly more eosinophils in RS than normal horses.

On an individual basis, horses with interstitial pneumonia and moderate and severe chronic small airway disease had more neutrophils in RS than normal horses. All horses with mild chronic small airway disease except one had more neutrophils in RS samples than normal horses. Each horse with pulmonary eosinophilic infiltration had RS cytology which differed from that of normal horses; however, it did not always indicate that these horses had increased numbers of pulmonary eosinophils

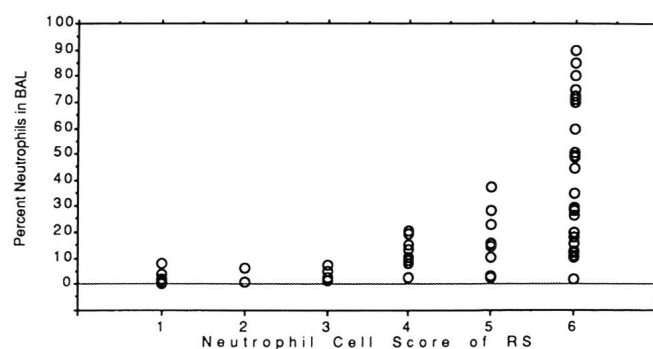
since only three out of nine had high eosinophil scores. The other 6 horses had either high neutrophil scores (3 horses) or hemosiderocytes (3 horses) in RS samples. Hemosiderocytes were also observed in RS from all horses with pulmonary hemorrhage, one horse with interstitial pneumonia and two horses with moderate chronic small airway disease.

It is evident in Figure 3 that there tended to be a positive association between the percentage of neutrophils in BAL samples and the neutrophil scores in RS specimens.

DISCUSSION

The results of this study indicate that RS cytology is often a useful aid in identifying horses with pulmonary disease; how-

Fig. 3: The relationship between neutrophil cell score in RS and the percentage of neutrophils in BAL fluid: 1- very few cells; 2- widely scattered cells; 3- moderate numbers of cells; 4- moderate to many cells; 5- many cells; 6- massive numbers of cells.



ever, it cannot be used to determine the type of pulmonary lesions present and it may not always identify horses with mild chronic small airway disease and pulmonary eosinophilic infiltration. This is in agreement with the results of an earlier study (Winder et al., 1989). In addition, it is not possible to evaluate the severity of disease since horses with mild, moderate and severe chronic small airway disease often had overlapping neutrophil scores. Hemosiderocytes were consistently observed in both BAL and RS cytological samples obtained from horses with pulmonary hemorrhage. Thus, RS appears to contain a representative sample of cells from the lower airways since histological evidence of pulmonary hemorrhage was invariably observed in and around small and terminal bronchioles in the caudodorsal region. This is in contrast to the study by Derksen et al. (1989) which reported that out of nine horses with hemosiderocytes in BAL samples, only four had hemosiderocytes in transtracheal aspirates.

Both BAL and RS cytological samples obtained from horses with pulmonary eosinophilic infiltration identified these horses as having an abnormal pulmonary status; however, an increase in eosinophils in the cytological samples was not always observed and thus the type of lung histology could not be determined from either BAL or RS cytology.

Significantly more lymphocytes were observed in RS samples from horses with severe chronic small airway disease than normal. This was not true for BAL samples from these horses. This may have been due to the difference in scoring systems used i. e. a semi-quantitative scoring system for RS specimens and a quantitative system for BAL samples.

The BAL cytological results obtained from normal horses in this study most closely resemble those reported by Viel (1983). In his study, pulmonary diagnoses were also determined histologically. Viel (1983) concluded that the information obtained from histological evaluation of the lungs was by far the most valuable reference when assessing BAL results. Macrophage and lymphocyte percentages in differential cell counts obtained from BAL performed in clinically healthy horses appear to have the widest variation in previously published literature (Derksen et al., 1985; Mair et al., 1987; Derksen et al., 1989). Viel (1983) showed that conventional means of assessing pulmonary status were of little aid in detecting subclinical chronic airway diseases. The nitrogen washout test is perhaps the only test able to detect subclinical pulmonary changes (Spörri and Denac, 1970; Muylle and Oyaert, 1973; Viel, 1983). Thus, some of the horses assessed as healthy in previous studies (Derksen et al., 1985; 1989) may have had subclinical disease which perhaps would explain the rather high percentage of lymphocytes reported.

As in Viel's (1983) study, on a group basis horses with mild chronic small airway disease had significantly more lymphocytes in differential cell counts from BAL fluid than normal horses. Similarly, an increase in the percentage of neutrophils and a decrease in the percentage of macrophages generally was seen as the severity of the disease increased. Although, on a group basis, horses with mild and moderate chronic small airway disease could be differentiated from horses with severe chronic small airway disease, on an individual basis the severity of the chronic small airway disease could not always be determined based on BAL cytology.

Interestingly, the percentage of neutrophils in BAL cytological samples obtained from six horses with severe chronic small airway disease was less than 24% (range 11 to 23%). In addition, in differential cell counts of BAL fluid obtained before slaughter in two horses with severe chronic small airway disease, the percentage of neutrophils differed greatly from one lung to the other. Why there was such a high fluctuation in the percentage of neutrophils in BAL differential cell counts from horses with severe chronic small airway disease is unknown. Perhaps, it is a question of what areas in the lung are lavaged. In this study, it was observed that the lung parenchyma in horses with severe chronic small airway disease was often difficult to inflate by infusing PBS and that the PBS often flowed back up the primary bronchus before the full amount had been instilled. Perhaps due to airway obstruction or bronchiolar constriction, much of the lavage fluid did not reach the alveolar spaces. Thus, only bronchi and bronchioles, containing massive numbers of neutrophils were lavaged.

Lavage of specific lung areas or simply knowing where the lavage fluid is going would be an asset in evaluating pulmonary disease in horses, especially in cases with focal lesions. In this study it was sometimes observed that combining the fluid from all areas lavaged in lungs with focal lesions resulted in a dilution of certain cell types that would have otherwise aided in a more specific diagnosis. As well, if all areas of the lung are not lavaged, a focal lesion may be missed entirely. Other researchers have reported that in lungs with focal lesions, BAL may be of limited value in diagnosing respiratory disease (Sweeney et al., 1988).

In this study, there was a positive correlation between the number of neutrophils in BAL differential cell counts and the amount of neutrophils in RS. This is in contrast to the study of Derksen et al. (1989); however, their study used horses in which the pulmonary status was assessed clinically. Thus, perhaps some of the horses included in the control group had subclinical lung disease which would explain the high per-

centage of neutrophils observed in transtracheal specimens and the rather high percentage of lymphocytes reported in BAL samples. There was no correlation between other cell types in BAL and RS specimens in this study. This indicates that the cytological pictures presented by BAL and RS differ and that each must be interpreted individually when used as an aid in diagnosing pulmonary disease.

In conclusion, both BAL and RS cytology appear to be useful aids in the detection of equine pulmonary disease although the type and severity of disease cannot always be determined by either method. Bronchoalveolar lavage cytology is probably a better aid in the diagnosis of mild or subclinical chronic small airway disease than cytological examination of RS. This is especially true in horses which have little or no RS available for sampling. In most instances, however, procurement and examination of RS may be easier for the practitioner to perform and thus RS cytology remains a useful tool for detecting pulmonary disease in the horse.

REFERENCES

Derksen F. J., Scott J. S., Miller D. C., Slocombe R. F., Robinson N. E. (1985): Bronchoalveolar lavage in ponies with recurrent airway obstruction (heaves). *Am. Rev. Respir. Dis.* 132, 1066–1070. — Derksen F. J., Brown C. M., Sonea I., Darien B. J., Robinson N. E. (1989): Comparison of transtracheal aspirate and bronchoalveolar lavage cytology in 50 horses with chronic lung disease. *Equine Vet. J.* 21, 23–26. — Essl A. (1987): Statistische Methoden in der Tierproduktion. Österreichischer Agrarverlag, Wien, pp. 104–105, 253. — Feldman D. S., Gagnon J. (1986): Brainpower Inc., 24009 Ventura Boulevard, Calabasa, California. — Larson V. L., Busch R. H. (1985): Equine tracheobronchial lavage: Comparison of lavage cytologic and pulmonary histopathologic findings. *Am. J. Vet. Res.* 46, 144–146. — Mair T. S., Stokes C. R., Bourne F. J. (1987): Cellular content of secretions obtained by lavage from different levels of the equine respiratory tract. *Equine Vet. J.* 19, 458–462. — Mair T. S. (1987): Value of tracheal aspirates in the diagnosis of chronic pulmonary diseases in the horse. *Equine Vet. J.* 19, 463–465. — Muylle E., Oyaert W. (1973): Lung function tests in obstructive pulmonary disease in horses. *Equine Vet. J.* 5, 37–44. — O'Callaghan M. W., Pascoe J. R., Tyler W. S., Mason D. K. (1987): Exercise-induced pulmonary haemorrhage in the horse: results of a detailed clinical, post mortem and imaging study. V. Microscopic observations. *Equine Vet. J.* 19, 411–418. — Remington R. D., Schork M. A. (1970): Statistics with Applications to the Biological and Health Sciences. Prentice-Hall, Inc., Englewood Cliffs, New Jersey. — Spörri H., Denac M.: Der Stickstoffeinwaschungstest im Dienste der Lungenfunktionsprüfung. *Zbl. Vet. Med. A* 17, 845–856 (1970). — Sweeney C. R., Rossier Y., Ziemer E. L. (1988): Bronchoalveolar lavage in the horse. *Proc. Am. Assoc. Eq. Pract.* p. p. 669–670 (1988). — Viel L. (1983): Structural-functional correlations of the lung in horses with small airway disease. PhD Thesis, Guelph, Ontario, Canada. —

Winder N. C. (1987): Chronic small airway disease in the horse: Pathologic and immunohistochemical studies. *Vet. med. Diss.* Zürich. — Winder N. C., Grünig G., Hermann M., Howald B., von Fellenberg R. (1989): Comparison of respiratory secretion cytology and pulmonary histology in horses. *Zbl. Vet. Med. A* 36, 32–38.

Etude cytologique comparative des liquides de lavages broncho-alvéolaires et des sécrétions bronchiques chez des chevaux souffrants de maladies pulmonaires diagnostiquées histologiquement

Du liquide de lavages broncho-alvéolaires (BAL) de 70 chevaux et des sécrétions bronchiques (BS) de 61 de ces chevaux ont été prélevés et étudiés cytologiquement, puis classés en groupes selon les résultats histologiques. On constate les diagnostics suivants: poumons normaux (8 chevaux); infiltrations éosinophiles du tissu pulmonaire (9 chevaux); pneumonies interstitielles (5 chevaux); hémorragies pulmonaires (5 chevaux); maladies pulmonaires chroniques faibles (12 chevaux), moyennes (7 chevaux), graves (24 chevaux).

Tous les prélèvements de BAL et de BS (sauf un) effectués chez des chevaux malades sont différents cytologiquement de ceux effectués chez des chevaux sains.

Cependant la cytologie de BAL ou de BS ne permet pas toujours de déterminer le type et la gravité de la maladie pulmonaire. On constate une corrélation nette entre le nombre de neutrophiles dans BAL et dans BS, tandis qu'on en constate aucune pour les autres types de cellules.

Studio comparativo citologico di liquido broncoalveolare e del secreto bronchiale nei cavalli con malattia polmonare diagnosticata istologicamente

I liquidi dei lavaggi broncoalveolari di 70 cavalli e i secreti bronchiali di 61 individui dello stesso gruppo furono raccolti, citologicamente studiati e classificati secondo le diagnosi istologiche. Sono state constatate le seguenti alterazioni: polmoni normali (8 cavalli); infiltrazione di eosinofili nei polmoni (9 cavalli); polmonite interstiziale (5 cavalli); emorragia polmonare (5 cavalli); malattia polmonare leggera (12 cavalli), media (7 cavalli) e grave cronica (24 cavalli).

Tutti i prelievi dei lavaggi broncoalveolari e, con una sola eccezione, anche i secreti bronchiali dei cavalli malati differivano citologicamente dai prelievi dei cavalli sani. Il tipo e la gravità della malattia però non poterono essere sempre determinati mediante analisi citologica dei lavaggi broncoalveolari e secreti bronchiali.