

Zeitschrift: Schweizer Archiv für Tierheilkunde SAT : die Fachzeitschrift für Tierärztinnen und Tierärzte = Archives Suisses de Médecine Vétérinaire
ASMV : la revue professionnelle des vétérinaires

Herausgeber: Gesellschaft Schweizer Tierärztinnen und Tierärzte

Band: 132 (1990)

Heft: 8

Artikel: Acute serous pancreatitis ("edematous pancreatitis") in slaughtered pigs

Autor: Marcato, P.S. / Della Salda, L. / Lollini, L.

DOI: <https://doi.org/10.5169/seals-593573>

Nutzungsbedingungen

Die ETH-Bibliothek ist die Anbieterin der digitalisierten Zeitschriften auf E-Periodica. Sie besitzt keine Urheberrechte an den Zeitschriften und ist nicht verantwortlich für deren Inhalte. Die Rechte liegen in der Regel bei den Herausgebern beziehungsweise den externen Rechteinhabern. Das Veröffentlichen von Bildern in Print- und Online-Publikationen sowie auf Social Media-Kanälen oder Webseiten ist nur mit vorheriger Genehmigung der Rechteinhaber erlaubt. [Mehr erfahren](#)

Conditions d'utilisation

L'ETH Library est le fournisseur des revues numérisées. Elle ne détient aucun droit d'auteur sur les revues et n'est pas responsable de leur contenu. En règle générale, les droits sont détenus par les éditeurs ou les détenteurs de droits externes. La reproduction d'images dans des publications imprimées ou en ligne ainsi que sur des canaux de médias sociaux ou des sites web n'est autorisée qu'avec l'accord préalable des détenteurs des droits. [En savoir plus](#)

Terms of use

The ETH Library is the provider of the digitised journals. It does not own any copyrights to the journals and is not responsible for their content. The rights usually lie with the publishers or the external rights holders. Publishing images in print and online publications, as well as on social media channels or websites, is only permitted with the prior consent of the rights holders. [Find out more](#)

Download PDF: 08.07.2025

ETH-Bibliothek Zürich, E-Periodica, <https://www.e-periodica.ch>

phocytes and a corresponding depression of the CD4+:CD8+ ratio. In contrast, cats with short-term FIV-infection (5–6 months) developed antibody responses to the T-dependent immunogen that did not differ significantly from those of matched control cats. Therefore, the observation that immunosuppressed cats infected with FIV do not show clinical symptoms may be explained by the lack of secondary infectious agents in SPF facilities. FIV infection has attracted interest as a model for human AIDS. The reasons for this are that FIV is a lentivirus related to HIV, that the

natural course of disease is similar to that of human AIDS, that cats are readily available and that the infection can easily be transmitted under experimental conditions.

There is no evidence of FIV being a threat to public health. This was concluded from studies showing that FIV does not replicate in lymphocyte cultures from other species; and that antibodies to FIV could not be detected in veterinarians and animal care personnel with prolonged exposure to sick cats.

Library of the Faculty of Veterinary Medicine, State University, Utrecht

SEARCHING LITERATURE FOR VETERINARY PATHOLOGY. I. HOW TO TACKLE THE AVALANCHE OF PERIODICAL LITERATURE IN THE FIELD OF PATHOLOGY

A. H. H. M. Mathijsen, Th. A. M. Elsinghorst

An overview is given of journals publishing articles of interest for the (veterinary) pathologist. The sheer number of these journals and the articles they contain forces to apply modern methods of information retrieval. Next to online retrieval, subscribing to SDI-services or using Current Contents (in paper or electronic form), the consultation of databases on CD-ROM and subsequent downloading of search results offer elegant solutions to conquer seemingly unsurmountable mountains of paper.

In order to reach optimal solutions for local needs a close cooperation between the library and the clinics, laboratories and research departments is essential. A new type of intermediary is evolving: a member of an endusers group being a specialist in a certain branch of (veterinary) medicine and familiar with literature search. The required qualities of this «intermediary/documentalist» are:

– Knowledge of the discipline of the regarding user group.

– Knowledge of the specific needs of the different members of the user group in connection with their diagnostic tasks and their research projects.

– Knowledge of the contents and the structure of databases.

– Knowledge of conversion programmes.

This new type of intermediary can fill the gap between the general information resource manager/librarian and the enduser oriented database searcher.

The impression is that the export of specialized and well selected files into the working and teaching area of academic departments can improve the understanding of bibliographic characteristics of staff-members and students and can promote the rational use of the library resources. As an example an elaboration will be given of a veterinary pathology file, installed in the dissection room of the Department of Veterinary Pathology of Utrecht, as an aid in Diagnostic Pathology (part II, next presentation).

Ist. Patologia Generale e Anatomia Patologica Veterinaria, Università di Bologna, Italia

ACUTE SEROUS PANCREATITIS («EDEMATOUS PANCREATITIS») IN SLAUGHTERED PIGS

P. S. Marcato, L. Della Salda, L. Lollini, L. Zaghini

An acute serous pancreatitis has been described in slaughtered pigs since 1977 (8). In this report the histologic and ultrastructural pancreatic changes are characterized and the main pathogenetic factor is demonstrated.

Material and methods

A post mortem examination of 21,719 pigs (average body wt. 164.4 Kg) was carried out in the same abattoir. Before slaughtering the pigs were fasted (only water was available) up to 40 hours (15,678) and up to 60 hours (5,775). 226 pigs were slaughtered after protracted fasting (± 70 hours). Organs fixed in Carson's formalin were: pancreas with edema (82), control pancreas (12), liver and gastric lymphnodes. Paraffin sections were stained with HE, Masson trichrome, and PAS. Ultrathin sections of pancreas fixed in glutaraldehyde were stained with uranyl acetate and lead citrate and examined with a Zeiss EM 109.

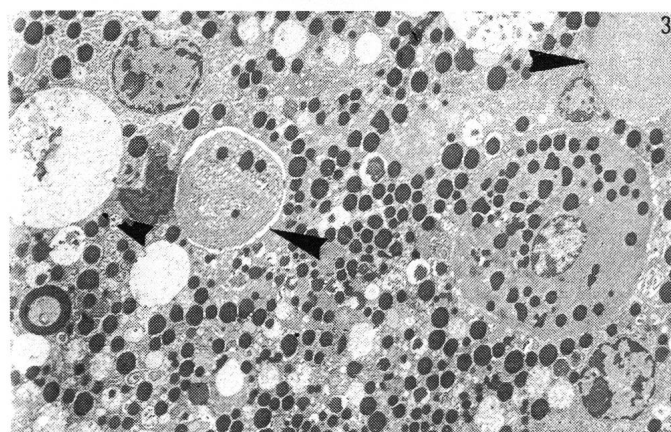
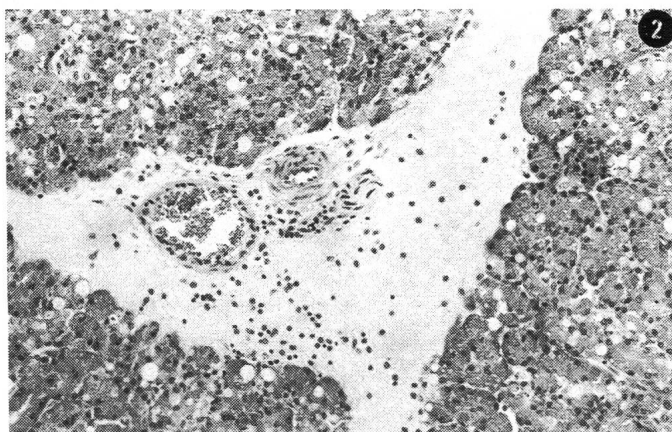
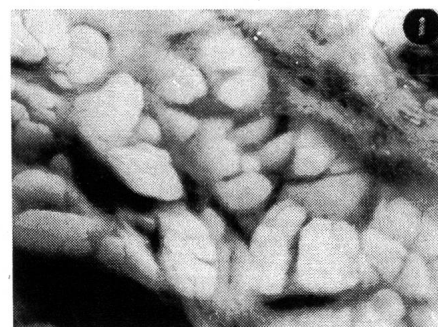Results

Diffuse subcapsular and interlobular edema (fig. 1) was found in the pancreas of pigs from different stock-farms. The incidence but not the severity of the lesions varied greatly in relation to the fasting-period before slaughter (Table 1): very low (0.06%) in 15,678 pigs fasted up to 40 hours, increased (2.3%) in 5,775 pigs fasted up to 60 hours. The incidence reached 36.8% in 266 pigs slaughtered after protracted fasting (± 70 hours). No gross lesions were seen in other organs.

Histologic pancreatic changes consisted in an acute interstitial serous inflammation. The interlobular stroma was distended by an acidophilic and weakly PAS positive exudate with scattered mononuclear cells and neutrophils (fig. 2). Multifocal alteration of single or grouped acinar cells was constantly noted. Affected cells were filled with zymogen granules and contained a single large vacuole, or occasionally, multiple small vacuoles. Many acinar vacuolated cells bordered the interlobular edematous interstitium. The large cell vacuole appeared empty or included an irregular corpuscle and few

Table 1. Incidence of pancreatitis in slaughtered pigs in relation with pre-slaughter fasting

Pre-slaughter fasting	Number	Edematous slaughtered	% pancreatitis
(<40h	15.678	10	0.06
40-60h	5.775	135	2.3
±70h	266	98	36.8



zymogen granules. The islets of Langerhans were generally spared although single-cell vacuolation was occasionally seen. The liver was affected and the gastric lymph nodes exhibited a lymphoid hyperplasia.

Ultrastructurally, the single-vacuolated acinar cells had a focal abnormal dilation of the rough endoplasmic reticulum with eventual disruption and coalescence to form a large membrane bound space. The latter contained disintegrated cellular material and recognizable organelles, some zymogen granules (on one occasion variable amounts of amyloid fibrils). The remaining area of the vacuole was clear and the limiting membrane had many internally-attached ribosomes (fig. 3). The nucleus was laterally displaced and infrequently disrupted. Mitochondria were generally well preserved. The multiple small vacuoles, occasionally found in acinar cells, seemed derived from dilation and vesiculation of endoplasmic reticulum due to the ingress of water.

Discussion

The type of pancreatitis illustrated here corresponds to the interstitial, serous or edematous, mild pancreatitis in humans (2). It is an infrequent spontaneous lesion in animals (3, 4), although very often induced in laboratory animals by lower doses of toxic chemicals (5). A pancreatic edema with more severe degeneration and necrosis of the pancreas was induced in pigs with T-2 toxin, a trichothecene mycotoxin (6).

In our material the pancreatitis is associated with acinar cell injury leading to autophagy (intracisternal sequestration) (7). Autophagy results from release or activation of pancreatic enzymes, and is a major mechanism in the induction of pancreatitis (2). Although

autophagic vacuoles are normally seen in scattered acinar cells, their number increase in proportion to the severity of injury. Moreover interstitial autophagic vacuole extrusion of enzymes and cell debris forms a powerful stimulus for inflammation.

Our cases of pancreatitis are significantly associated only with fasting of pigs before slaughter. A great rise in incidence, from 2.3% to 36.8%, was obtained in 266 pigs by protracted fasting (± 70 hours): the slaughter of animals, transported to the abattoir on Saturday, was delayed to Tuesday.

Semi-fasting or total fasting are reputed key factors in increasing acinar cell autophagy (4, 8, 9). The autophagic extrusion of damaging enzymes may well be the ultimate cause of pancreatitis (2). The increased vagal tone by fasting may also contribute to vasodilation and edema (10). Nevertheless we are doubtful that fasting alone can explain the onset of pancreatitis in slaughtered pigs. Other unknown, environmental and/or species-specific factors could be implicated.

References

1. Marcato P. S. et al. (1977): *Atti S.I.S. VET.* 31, 689.
2. Longnecker D. S. (1982): *Amer. J. Pathol.* 107, 99.
3. Kast A. (1967): «Bauchspeicheldrüse» in Joest's Handbuch d. spez. path. Anat. d. Haustiere. 3. Aufl. Band VI. Parey, Berlin.
4. Rosiers G. et al. (1973): *Vlaams Diergenesk. Tijds.* 42, 461.
5. Longnecker D. S. (1977): *Environ. Health. Perspec.* 20, 105.
6. Pang V. F. et al. (1986): *Vet. Pathol.* 23, 210.
7. Ghadially F. N. (1988): *Ultrastructural pathology of the cell and matrix.* Butterworths, London.
8. Lazarus S. L. et al. (1965): *Arch. Path.* 80, 135.
9. Nevalainen T. J., Janigan D. T. (1974): *Virchows Arch. Zellpathol.* 15, 107.
10. Francini F., Losano G. (1985): *Elementi di fisiologia dell'uomo.* UTET, Torino.