

Zeitschrift: Acta Tropica
Herausgeber: Schweizerisches Tropeninstitut (Basel)
Band: 45 (1988)
Heft: 1

Artikel: Does dexamethasone suppress the Mazzotti reaction in patients with onchocerciasis?
Autor: Stingl, P. / Pierce, P.F. / Connor, D.H.
DOI: <https://doi.org/10.5169/seals-314060>

Nutzungsbedingungen

Die ETH-Bibliothek ist die Anbieterin der digitalisierten Zeitschriften auf E-Periodica. Sie besitzt keine Urheberrechte an den Zeitschriften und ist nicht verantwortlich für deren Inhalte. Die Rechte liegen in der Regel bei den Herausgebern beziehungsweise den externen Rechteinhabern. Das Veröffentlichen von Bildern in Print- und Online-Publikationen sowie auf Social Media-Kanälen oder Webseiten ist nur mit vorheriger Genehmigung der Rechteinhaber erlaubt. [Mehr erfahren](#)

Conditions d'utilisation

L'ETH Library est le fournisseur des revues numérisées. Elle ne détient aucun droit d'auteur sur les revues et n'est pas responsable de leur contenu. En règle générale, les droits sont détenus par les éditeurs ou les détenteurs de droits externes. La reproduction d'images dans des publications imprimées ou en ligne ainsi que sur des canaux de médias sociaux ou des sites web n'est autorisée qu'avec l'accord préalable des détenteurs des droits. [En savoir plus](#)

Terms of use

The ETH Library is the provider of the digitised journals. It does not own any copyrights to the journals and is not responsible for their content. The rights usually lie with the publishers or the external rights holders. Publishing images in print and online publications, as well as on social media channels or websites, is only permitted with the prior consent of the rights holders. [Find out more](#)

Download PDF: 03.07.2025

ETH-Bibliothek Zürich, E-Periodica, <https://www.e-periodica.ch>

¹ National Leprosy Training Centre, P.O. Box 17, Wau, Southern Sudan

² Present address: Department for Infectious and Tropical Diseases, University of Munich, Munich, Federal Republic of Germany – Lechbruckerstrasse 10, D-8924 Steingaden, FRG

³ Division of Infectious Diseases, Georgetown University Hospital, Washington, D.C. 20007, USA

⁴ Department of Infectious and Parasitic Disease Pathology, Armed Forces Institute of Pathology (AFIP), Washington, D.C. 20306-6000, USA

⁵ Present address: 7029 Maple Avenue, Chevy Chase, Md. 20815, USA

⁶ Tulane University School of Medicine, New Orleans, Louisiana 70012, USA

Does dexamethasone suppress the Mazzotti reaction in patients with onchocerciasis?

P. STINGL^{1, 2}, P. F. PIERCE^{3, 4}, D. H. CONNOR^{4, 5}, D. W. GIBSON⁴, T. STRAESSLE¹, M. A. ROSS^{4, 6}, J. L. RIBAS⁴

Summary

The Mazzotti reaction is a frequent complication in patients with onchocerciasis being treated with diethylcarbamazine (DEC); and more severe manifestations of this reaction may be unacceptable in many patients. It has recently been demonstrated that prednisone modifies the severity of this reaction and reduces the microfilaricidal activity of DEC. A clinical trial was performed at the National Leprosy Training Center in Wau, Sudan, to evaluate the clinical and histologic effect of the use of corticosteroids in patients receiving DEC. Administration of a *low* dose of dexamethasone (3 mg/day), begun *after* onset of the Mazzotti reaction, modifies the progression of the Mazzotti reaction without interfering with the microfilaricidal efficacy of DEC. *Pretreatment* with low-dose dexamethasone – prior to beginning DEC therapy – prevents the development of the Mazzotti reaction and greatly reduces the microfilaricidal activity. Administration of diphenhydramine, *after* onset of the Mazzotti reaction, has no effect on the course and intensity of the Mazzotti reaction nor on microfilaricidal activity. We recommend that low-dose corticosteroids be administered in conjunction with DEC – *after* onset of the Mazzotti reaction – and that they be tapered rapidly.

Key words: onchocerciasis; Mazzotti reaction; diethylcarbamazine; dexamethasone; diphenhydramine.

Correspondence: Dr. Dean W. Gibson, Department of Infectious and Parasitic Disease Pathology, Armed Forces Institute of Pathology, Washington, D.C. 20306-6000, USA

Introduction

Diethylcarbamazine (DEC) has been the primary drug therapy for the treatment of onchocerciasis for nearly four decades since its introduction (Mazzotti, 1948). The principal adverse effect has been termed the Mazzotti reaction and is characterized by one or more of the following: pruritus, skin rash, eye complications, glandular reactions, cardiovascular symptoms, musculo-skeletal pain, headache, or vertigo (Mazzotti, 1948; Satti and Kirk, 1957; Fuglsang and Anderson, 1974; Bryceson et al., 1977). Corticosteroids have been reported to suppress the Mazzotti reaction (Fuglsang and Anderson, 1974; Anderson and Fuglsang, 1978; Awadzi et al., 1982; Titanji et al., 1983); under the regimens in those studies, however, the microfilaricidal efficacy of the DEC was greatly reduced.

We report here studies of the effects of administering dexamethasone – *after* onset of the Mazzotti reaction vs. before DEC therapy is begun – on the subsequent course of the Mazzotti reaction and also on the microfilaricidal efficacy of the DEC therapy in patients with onchocerciasis. Both clinical and histopathologic changes are reported for the various regimens. The mechanism by which DEC causes the Mazzotti reaction is re-examined in view of these findings.

Patients in this study lived in villages in Bahr El Ghazal Province of southern Sudan, where numerous earlier studies have shown onchocerciasis to be hyperendemic (Cruickshank, 1936; Satti and Kirk, 1957; Kirk et al., 1959; Haseeb et al., 1962; Abdalla, 1974; Enarson, 1977; El Sheikh, 1985; Ghalib et al., 1985; Kaneene et al., 1985; Satti, 1985; Williams et al., 1985a, b; Stingl, 1986). Patients in the present study were among nearly 200 onchocerciasis patients under various treatment regimens at the National Leprosy Training Centre (NLTC) in Wau, Sudan; results have been previously presented for a subgroup of onchocerciasis patients with leprosy who received oral DEC (without steroids) and regular dapsone therapy for leprosy (Stingl and Stingl, 1982), and for a subgroup that received a topical DEC “patch test” (Stingl et al., 1984).

Materials and Methods

Sixteen patients were admitted to the NLTC for treatment with DEC. There were nine men and seven women, ranging in age from 18 to 38 years (Table 1). All patients lived in hyperendemic villages of Bahr El Ghazal province, and all were found to have onchocerciasis on clinical and parasitological examination. Three of the 16 patients were being followed for leprosy.

Skin snips were taken from the outer canthus, scapula, iliac crest, and calf with a Walser-type corneoscleral punch. The snips were weighed on a torsion balance and incubated in physiologic saline. Microfilariae that had emerged into the incubation medium were counted at 24 h, and the tissue parasitic burden (microfilariae per mg of skin; mf/mg) was calculated. The aggregate microfilarial density (AMD) was determined by adding densities at the four sites (Awadzi et al., 1980).

Biopsy specimens of skin were taken through areas of clinical change, fixed in formalin, and sent to the Armed Forces Institute of Pathology, Washington, DC, for histopathologic study. The specimens were embedded in paraffin and cut at section thicknesses of 6 μ m. Slides were stained with

hematoxylin and eosin, Giemsa, and Russell-Movat procedures, as previously described (Connor et al., 1970, 1985; Gibson et al., 1976, 1980).

All sixteen patients received an equivalent total dosage of 3.225 g DEC over 14 days, according to the following regimen:

Day No.:	1	2	3	4	5	6 through 14 [entire 14-day course]
mg DEC:	25	50	100	150	200	300 (× 9days) [3225 mg DEC, total dosage]

These patients were treated randomly with one of three regimens (groups A, B, and C), to modify their response to DEC:

Group A: Three patients (Nos. 1–3) received dexamethasone, 1.5 mg BID, for three days prior to receiving the initial oral dose of 25 mg DEC; and dexamethasone was continued for an additional 3 days, while DEC was increased in a stepwise manner (regimen above). A skin biopsy specimen was taken from one patient in group A: patient 3 at day 5.

Group B: Seven patients (Nos. 4–10) receiving DEC had dexamethasone initiated after the onset of symptoms consistent with a Mazzotti reaction; dexamethasone dosage was begun at 1.5 mg BID and was then tapered over 7 days. No biopsy specimens were taken from patients in group B.

Group C: Six patients (Nos. 11–16) were treated with diphenhydramine, 50 mg TID, after the Mazzotti reaction began during DEC therapy. Biopsy specimens were taken from two patients in group C: patient 11 at day 7 and patient 14 at days 12 and 18.

Results

The three patients pretreated with dexamethasone (group A) had very mild adverse responses to DEC: two experienced mild pruritus and the third was asymptomatic. The seven patients receiving dexamethasone after onset of the Mazzotti reaction (group B) experienced relief of symptoms within one day of beginning dexamethasone and by day 3 no further Mazzotti reaction was evident. Of the six patients treated with diphenhydramine after onset of the Mazzotti reaction (group C), pruritus improved in only one; no effect was observed in the other five patients.

The pretreatment and posttreatment aggregate microfilarial densities are shown in Table 1. For group A, no significant reduction in AMD was seen in patients 1 and 2 at day 5; and a 48% reduction occurred in patient 3 at day 10. Patients in groups B and C had 69% to 100% (92% average) and 100% reductions of AMDs, respectively.

Skin biopsy specimens from selected patients (one from group A; two from group C) demonstrated similar results to the AMDs. A specimen from patient 3 of group A (day 5) demonstrated many microfilariae, mostly in the upper dermis, but none were degenerating or centered within foci of inflammation. The characteristic features of untreated onchocercal dermatitis were present: hyperpigmentation of keratin and one pigmented hyperkeratotic focus (tombstone), sclerotic dermal papillae, pigmentary incontinence, and dilated lymphatics (Fig. 1). Histiocytes, plasma cells, and lymphocytes surrounded

Table 1. Effects of dexamethasone and diphenhydramine on aggregate microfilarial density (AMD) and on the Mazzotti reaction to equivalent DEC dosage^a

Patient No.	Age (yrs), sex	Pretreatment AMD ^b	Posttreatment AMD ^b (therapy day)	% Change in AMD ^b	Mazzotti reaction
<i>Group A – pretreatment with dexamethasone</i>					
1	25, ♂	1548	1510 (5)	–2.4%	mild itching
2 ^c	26, ♀	39	42 (5)	+7.7%	asymptomatic
3	30, ♂	108	56 (10) ^d	–48.2%	mild itching
<i>Group B – dexamethasone with Mazzotti reaction</i>					
4	38, ♂	227	70 (21)	–69.3%	relieved
5	18, ♀	320	40 (11)	–87.5%	relieved
6	29, ♂	717	50 (15)	–93.0%	partial relief
7	37, ♂	106	0 (17)	–100.0%	relieved
8	19, ♀	61	0 (16)	–100.0%	partial relief
9	20, ♂	427	26 (10)	–93.9%	relieved
10 ^c	19, ♂	257	0 (17)	–100.0%	itch persisted
<i>Group C – diphenhydramine with Mazzotti reaction</i>					
11	27, ♀	7	0 (10) ^e	–100.0%	no change
12	18, ♀	61	0 (16)	–100.0%	malaise improved
13	18, ♂	18	0 (12)	–100.0%	no change
14	33, ♀	193	0 (27) ^f	–100.0%	no change
15	20, ♂	380	0 (25)	–100.0%	no change
16 ^c	20, ♀	12	0 (9)	–100.0%	no change

^a All patients received 3.225 g DEC over 14 days (regimen in Materials and Methods).

^b AMD is the sum of microfilarial densities (mf/mg) in skin snips from four sites: outer canthus, scapula, iliac crest, and calf (Awadzi et al., 1980).

^c Leprosy patients, under regular dapsone therapy, with clinical classifications: patient 2, lepromatous leprosy; patient 10, borderline lepromatous leprosy; patient 16, borderline tuberculoid leprosy.

^d Biopsy specimen taken from skin of calf on day 5 of DEC therapy (cf. Fig. 1).

^e Biopsy specimen taken from skin of iliac crest on day 7 of DEC therapy (cf. Fig. 2).

^f Biopsy specimens taken from skin of thigh on days 12 and 18 of DEC therapy (cf. Figs. 3 and 4).

neurovascular channels and intact microfilariae in all layers of dermis. Some of these microfilariae had increased eosinophilia, but apart from the latter there was no histologic evidence of a Mazzotti reaction. An early specimen from patient 11 of group C (day 7) showed hyperpigmented keratin; acanthosis; many “tombstones” characteristic of post-DEC changes; and histiocytes, lymphocytes, and plasma cells surrounded blood vessels (Fig. 2). Also present in the dermis were melanophores and a few intact microfilariae. A later specimen from patient 14 of group C (day 12) was similar but showed degenerating microfilariae surrounded by degranulating eosinophils (Figs. 3 and 4). In a still

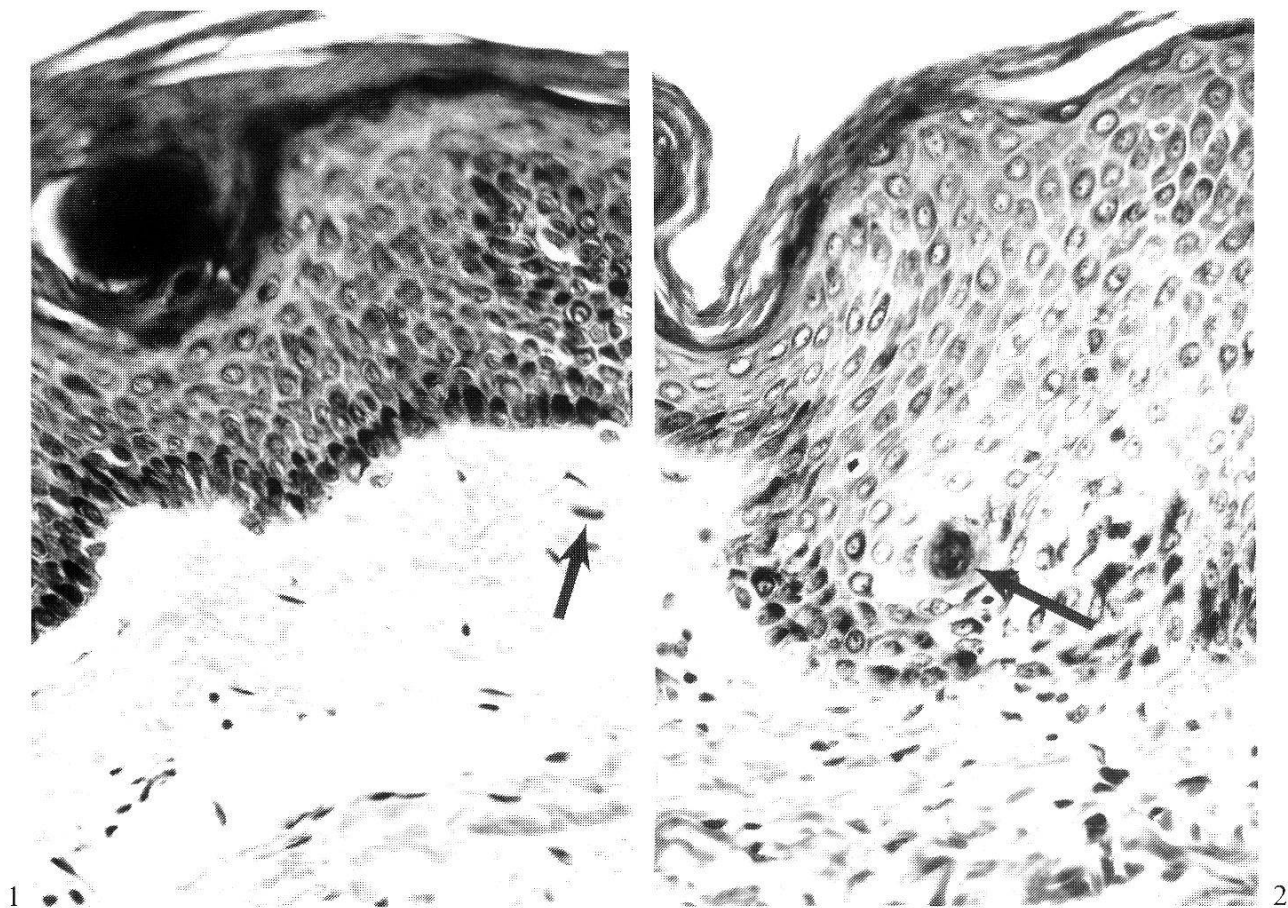
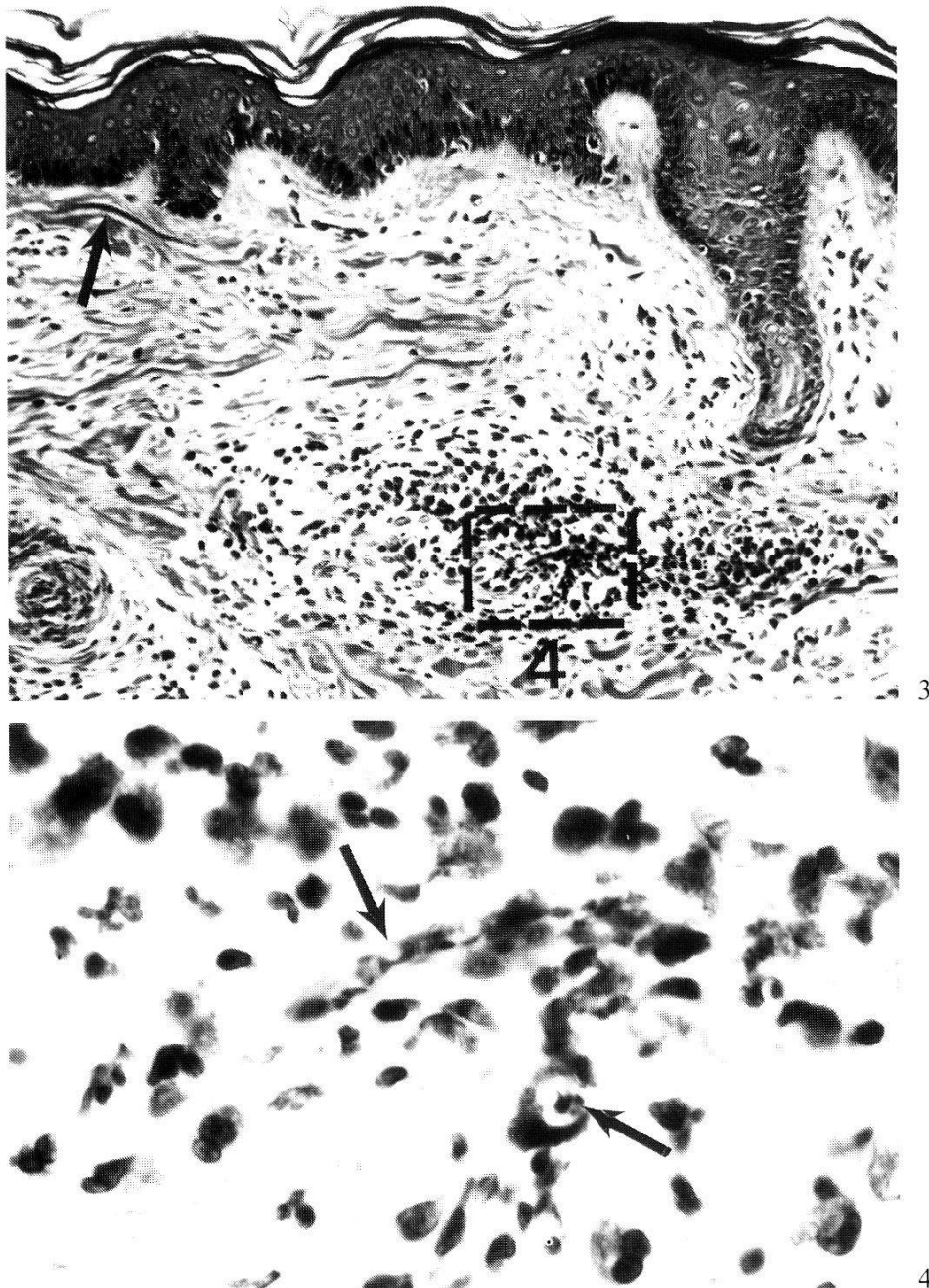


Fig. 1. Skin from the calf of patient 3 (group A – pretreated 3 days with dexamethasone) on day 5 after beginning treatment with DEC. In the upper dermis there is a fragment of a microfilaria (arrow) *without* degeneration, surrounding eosinophils or other post-DEC reaction (contrast with Figs. 3 and 4). Thus, pretreatment with steroids has inhibited the Mazzotti reaction. There are increased numbers of fibroblasts in the dermal collagen; some sclerosis of dermal papillae; a dilated lymphatic in the upper dermis; some acanthosis; and a parakeratotic nest in the keratin – all characteristic features of *untreated* onchocercal dermatitis. Hematoxylin and eosin, 250 \times (AFIP Neg. 85–9960).

Fig. 2. Skin from the iliac crest of patient 11 (group C – diphenhydramine with Mazzotti reaction) on day 7 after beginning treatment with DEC. There is a small (early) intraepidermal abscess (arrow) – a common feature after treatment with DEC. No microfilariae are in the abscess. Hematoxylin and eosin, 250 \times (AFIP Neg. 85–9961).

later specimen from patient 14 (day 18), the microfilariae had cleared, but the dermatitis persisted.

There was one patient with leprosy in each group (patients 2, 10, and 16 in groups A, B, and C, respectively). Patient 10 experienced itching longer than other patients in group B but had a 100% reduction in AMD. Patients 2 and 16 responded similarly clinically and by reduction in AMD to other members of their respective groups.



Figs. 3 and 4 (different magnifications of same field – box in Fig. 3). Skin from the thigh of patient 14 (group C – diphenhydramine with Mazzotti reaction) on day 12 after beginning treatment with DEC. There is an eosinophilic abscess in the upper dermis in which degranulating eosinophils surround a degenerating microfilaria – seen in tangential and cross sections (arrows in Fig. 4). In contrast to pretreatment with dexamethasone (cf. Fig. 1), diphenhydramine has not suppressed these characteristic features of the Mazzotti reaction. Just below the basal layer is an intact microfilaria (arrow in Fig. 3). Hematoxylin and eosin, 250 \times and 1000 \times (AFIP Negs. 85–9963 and 85–9964).

Discussion

This study provides histologic support to previous clinical studies that demonstrated modification of the Mazzotti reaction by corticosteroids. The use of low-dose dexamethasone, 3 mg/day, in combination with standard doses of

diethylcarbamazine resulted in limiting the Mazzotti reaction to mild pruritus and the elimination of hypotension, glandular reactions, and eye itching and tearing. Steroidal use, following onset of the Mazzotti reaction (group B), did not alter treatment effectiveness, since the average reduction of microfilariae was 91% compared to 100% reduction in group C (no corticosteroids). The dosage of steroids used in this study was quite low: 3 mg/day of dexamethasone, which is equivalent in steroid activity to 15 mg prednisone. Previous studies have used 60 mg prednisone (Awadzi et al., 1982), and this higher dosage may have caused the reduction of microfilariae by 79% of pretreatment counts.

The three patients with leprosy included in this study did not respond differently from the other patients. The Mazzotti reaction was suppressed, and the outcome of treatment was similar to other patients with onchocerciasis.

Pretreatment with dexamethasone prior to DEC (group A) did not result in reductions in AMD similar to those for groups B and C discussed above. Furthermore, the skin biopsy performed on patient 3 demonstrated many intact microfilariae with little of the inflammatory response typical of patients treated with DEC. These findings indicate that pretreatment with even low-dose corticosteroids may result in inadequate treatment of onchocercal dermatitis. Pretreatment with prednisone (at higher dosage) was used in the above-cited study by Awadzi et al. (1982). The ability of the microfilariae to survive despite DEC treatment in patients premedicated with dexamethasone provides further insight into the mechanism of action of DEC. Previous studies have demonstrated the ineffectiveness of DEC in vitro against microfilariae of *Onchocerca volvulus* (Hawking, 1950; Hawking et al., 1950). This study supports the finding that it is the eosinophil that damages the microfilaria and the effect of DEC is indirect (Kephart et al., 1984). Corticosteroid inhibition of eosinophil function is well-recognized. Gibson et al. (1976) first observed that after treatment with DEC microfilariae in the dermis were intensely eosinophilic and surrounded by eosinophils, indicating degeneration of these microfilariae. Pretreatment with corticosteroids eliminated the inflammation surrounding the microfilariae and reduced microfilarial density (AMD) by less than 50% (Table 1, group A). Corticosteroids that were begun with the onset of the Mazzotti reaction (group B) lessened symptoms dramatically and did not adversely affect the outcome.

We have demonstrated that the timing of the administration of corticosteroids is an important determinant of treatment outcome in patients with onchocercal dermatitis. Pretreatment with corticosteroids reduces DEC effectiveness to an unacceptable level. We recommend that low-dose corticosteroids be administered *after* the onset of the Mazzotti reaction and that they be tapered rapidly. Based on our findings, we cannot recommend pretreatment with corticosteroids. Our results must be considered preliminary in view of the small number of patients investigated and the variable time interval between initiation of the treatment and pathologic assessment.

New drug therapy for onchocerciasis is being developed (Aziz et al., 1982; Taylor, 1984; Awadzi et al., 1985; Green et al., 1985); however, diethylcarbamazine remains the principle treatment. Modification of the Mazzotti reaction will permit less toxic therapy until better drugs are widely available.

Acknowledgments

This work was supported in part by the German Leprosy Relief Association (DAHW), and in part by the World Health Organization (WHO), Geneva. The histopathologic specimens are filed in the WHO Collaborating Centre for the Histopathology of Filarial Diseases in Man, at the AFIP. Mrs. Maria Stingl performed all the laboratory work in the Sudan. Ms. Dale Slavin helped organize the data on the patients in the early stages of the study at AFIP. The opinions or assertions contained herein are the private views of the authors and are not to be construed as official or as reflecting the views of the DAHW, WHO, the Department of the Army or the Department of Defense, or the institutions with which the authors are affiliated.

- Abdalla R. E.: Filariasis in the Sudan. *Trans. roy. Soc. trop. Med. Hyg.* 68, 53–55 (1974).
- Anderson J., Fuglsang H.: Further studies on the treatment of ocular onchocerciasis with diethylcarbamazine and suramin. *Brit. J. Ophthal.* 62, 450–457 (1978).
- Awadzi K., Roulet H., Bell D. R.: The chemotherapy of onchocerciasis. V. A standard method for the determination of microfilarial density in skin snips. *Ann. trop. Med. Parasit.* 74, 363–366 (1980).
- Awadzi K., Orme M. L. E., Breckenridge A. M., Gilles H. M.: The chemotherapy of onchocerciasis. VII. The effect of prednisone on the Mazzotti reaction. *Ann. trop. Med. Parasit.* 76, 331–338 (1982).
- Awadzi K., Dadzie K. Y., Schulz-Key H., Haddock D. R. W., Gilles H. M., Aziz M. A.: The chemotherapy of onchocerciasis. X. An assessment of four single dose treatment regimes of MK-933 (ivermectin) in human onchocerciasis. *Ann. trop. Med. Parasit.* 79, 63–78 (1985).
- Aziz M. A., Diallo S., Diop I. M., Lariviere M., Porta M.: Efficacy and tolerance of ivermectin in human onchocerciasis. *Lancet* 1982/II, 171–173.
- Bryceson A. D., Warrell D. A., Pope H. M.: Dangerous reactions to treatment of onchocerciasis with diethylcarbamazine. *Brit. med. J.* 1977/I, 742–744.
- Connor D. H., Morrison N. E., Kerdell-Vegas F., Berkoff H. A., Johnson F., Tunnicliffe R., Failing F. C., Hale L. N., Lindquist K., Thornbloom W. (Dr. and Mrs.), McCormick J. B., Anderson S. L.: Onchocerciasis. Onchocercal dermatitis, lymphadenitis, and elephantiasis in the Ubangi territory. *Hum. Path.* 1, 553–597 (1970).
- Connor D. H., George G. H., Gibson D. W.: Pathologic changes of human onchocerciasis: implications for future research. *Rev. infect. Dis.* 7, 809–819 (1985).
- Cruickshank A.: Tropical diseases of the Southern Sudan, their distribution and significance. *E. Afr. med. J.* 13, 172–177 (1936).
- El Sheikh H. A.: Chemotherapy trials in onchocerciasis in southern Sudan: a review. *Sudan med. J.* 21 (Suppl.), 83–88 (1985).
- Enarson D. A.: Observations on onchocerciasis in the Sudan Republic: endemicity, intensity of infection and clinical features. *Ann. trop. Med. Parasit.* 71, 465–468 (1977).
- Fuglsang H., Anderson J.: Collapse during treatment of onchocerciasis with diethylcarbamazine. *Trans. roy. Soc. trop. Med. Hyg.* 68, 72–73 (1974).
- Ghalib H., Mackenzie C. D., Williams J. F., Sisley B. M., El Khalifa M. Y.: Immunology and the development of pathology in onchocerciasis; studies in Sudan. *Sudan med. J.* 21 (Suppl.), 59–64 (1985).

- Gibson D. W., Connor D. H., Brown H. L., Fuglsang H., Anderson J., Duke B. O. L., Buck A. A.: Onchocercal dermatitis: ultrastructural studies of microfilariae and host tissues, before and after treatment with diethylcarbamazine (Hetrazan). *Amer. J. trop. Med. Hyg.* 25, 74–87 (1976).
- Gibson D. W., Heggie C., Connor D. H.: Clinical and pathologic aspects of onchocerciasis. In: *Pathology annual: 1980*, ed. by S. C. Sommers and P. P. Rosen, vol. 15, part 2, p. 195–240. Appleton-Century-Crofts, New York 1980.
- Green B. M., Taylor H. R., Cupp E. W., Murphy R. P., White A. T., Aziz M. A., Schulz-Key H., D'Anna S. A., Newland H. S., Goldschmidt L. P., Auer C., Hanson A. P., Freeman S. V., Reber E. W., Williams P. N.: Comparison of ivermectin and diethylcarbamazine in the treatment of onchocerciasis. *New Engl. J. Med.* 313, 133–138 (1985).
- Haseeb M. A., Satti M. H., Sherif M.: Onchocerciasis in Sudan. *Bull. Wld Hlth Org.* 27, 609–615 (1962).
- Hawking F.: Some recent work on filariasis. *Trans. roy. Soc. trop. Med. Hyg.* 44, 153–186 (1950).
- Hawking F., Sewell P., Thurston J. P.: The mode of action of hetrazan on filarial worms. *Brit. J. Pharmacol.* 5, 217–238 (1950).
- Kancene J. B., Ibrahim M. H., Williams J. F., Mackenzie C. D., Ghalal I., O'Day J., Ling P.: An epidemiological study of onchocerciasis in Bahr El Ghazal Province, southern Sudan. *Sudan med. J.* 21 (Suppl.) 65–71 (1985).
- Kephart G. M., Gleich G. L., Connor D. H., Gibson D. W., Ackerman S. J.: Deposition of eosinophil granule major basic protein onto microfilariae of *Onchocerca volvulus* in the skin of patients treated with diethylcarbamazine. *Lab. Invest.* 50, 51–61 (1984).
- Kirk R., Morgan H. V., Haseeb, M. A., Satti M. H.: Onchocerciasis in the Sudan Republic. *Ann. trop. Med. Parasit.* 53, 97–102 (1959).
- Mazzotti L.: Posibilidad de utilizar como médico diagnóstico en la oncocercosis las reacciones alérgicas consecutivas a la administración de "Hetrazan". *Rev. Inst. Salubr. Enferm. trop. (Mex.)* 9, 235–237 (1948).
- Satti M. H.: A historical account of onchocerciasis in Sudan. *Sudan med. J.* 21 (Suppl.) 5–8 (1985).
- Satti M. H., Kirk R.: Observations on chemotherapy of onchocerciasis in Bahr el Ghazal Province, Sudan. *Bull. Wld Hlth Org.* 16, 531–540 (1957).
- Stingl P., Stingl M.: Leprosy, onchocerciasis, diethylcarbamazine and the Mazzotti reaction. *Leprosy Rev.* 53, 317–318 (1982).
- Stingl P., Ross M., Gibson D. W., Ribas J., Connor D. H.: A diagnostic "patch test" for onchocerciasis using topical diethylcarbamazine. *Trans. roy. Soc. trop. Med. Hyg.* 78, 254–258 (1984).
- Stingl P.: Onchocerciasis in Sierra Leone und im Südsudan: Klin. Epidemiologie, Dermatohistopathologie, Wirtantwort und Pathogenese. Habilitationsschrift, Ludw.-Max. Universität, München 1986.
- Taylor H. R.: Recent developments in the treatment of onchocerciasis. *Bull. Wld Hlth Org.* 62, 509–515 (1984).
- Titanji V. P. K., Barla E., Anyangwe S., Ngu J. L.: The effects of diethylcarbamazine citrate, antihistamines, and corticosteroid derivatives on skin reactivity to *Onchocerca* supernatants. *Tropenmed. Parasit.* 34, 30–32 (1983).
- Williams J. F., Mackenzie C. D., Dawood M. S.: Current distribution of onchocerciasis in Sudan. *Sudan med. J.* 21 (Suppl.), 9–17 (1985a).
- Williams J. F., Mackenzie C. D., Homeida M. M. A.: Detection and characterization of *Onchocerca volvulus* in Sudan. *Sudan med. J.* 21 (Suppl.), 49–58 (1985b).

