

Comparison of ultrasonography, intravenous pyelography and cystoscopy in detection of urinary tract lesions due to "Schistosoma haematobium"

Autor(en): **Burki, A. / Tanner, M. / Burnier, E.**

Objekttyp: **Article**

Zeitschrift: **Acta Tropica**

Band (Jahr): **43 (1986)**

Heft 2

PDF erstellt am: **22.05.2024**

Persistenter Link: <https://doi.org/10.5169/seals-313621>

Nutzungsbedingungen

Die ETH-Bibliothek ist Anbieterin der digitalisierten Zeitschriften. Sie besitzt keine Urheberrechte an den Inhalten der Zeitschriften. Die Rechte liegen in der Regel bei den Herausgebern.

Die auf der Plattform e-periodica veröffentlichten Dokumente stehen für nicht-kommerzielle Zwecke in Lehre und Forschung sowie für die private Nutzung frei zur Verfügung. Einzelne Dateien oder Ausdrucke aus diesem Angebot können zusammen mit diesen Nutzungsbedingungen und den korrekten Herkunftsbezeichnungen weitergegeben werden.

Das Veröffentlichen von Bildern in Print- und Online-Publikationen ist nur mit vorheriger Genehmigung der Rechteinhaber erlaubt. Die systematische Speicherung von Teilen des elektronischen Angebots auf anderen Servern bedarf ebenfalls des schriftlichen Einverständnisses der Rechteinhaber.

Haftungsausschluss

Alle Angaben erfolgen ohne Gewähr für Vollständigkeit oder Richtigkeit. Es wird keine Haftung übernommen für Schäden durch die Verwendung von Informationen aus diesem Online-Angebot oder durch das Fehlen von Informationen. Dies gilt auch für Inhalte Dritter, die über dieses Angebot zugänglich sind.

¹ Hôpital du Val-de-Ruz, Fontaines, Switzerland

² Swiss Tropical Institute, Basel, Switzerland

³ Swiss Tropical Institute Field Laboratory, Ifakara, Tanzania

⁴ St. Francis Hospital, Ifakara, Tanzania

⁵ Merian-Iselin Hospital, Basel, Switzerland

Comparison of ultrasonography, intravenous pyelography and cystoscopy in detection of urinary tract lesions due to *Schistosoma haematobium**

A. BURKI¹, M. TANNER³, E. BURNIER³, W. SCHWEIZER⁴, R. MEUDT⁵,
A. DEGRÉMONT²

Summary

The use of ultrasound in detecting urinary tract alterations by *Schistosoma haematobium* such as hydronephrosis and bladder calcifications was studied in 125 patients of the out-patients department of a district hospital in SE Tanzania, in an area highly endemic for this disease. Ultrasound was compared with plain abdominal X-ray (in 33 patients), intravenous pyelography (29), cystoscopy (31) and simple urine examination (125). Except for bladder calcifications which could not be demonstrated other than by X-ray, sonography compared favorably with IVP and cystoscopy and proved therefore to be a valuable tool in assessing *S.h.* related morbidity. – In children moderate and advanced hydronephrosis were always associated with an irregular bladder wall and correlated strongly with the prevalence and intensity of *S.h.* infections as well as with haematuria and proteinuria. Important congestive pathology was observed in 1 out of 10 infected children and in 1 out of 20 examined adults.

Key words: sonography; cystoscopy; intravenous pyelography, *Schistosoma haematobium*; morbidity; kidney; bladder.

* This work was realized through a grant from the World Health Organization (Nr. IR/ARI/PDP/013/RB/82.310) and the Swiss Directorate for Technical Co-operation and Humanitarian Aid. Research clearance has been granted by the Tanzanian National Scientific Research Council as per Ref. No. NSR/CONF R.C. 29th July 1982 and NSR/CONF R. C. 19th April 1983.

Introduction

Schistosoma haematobium (*S.h.*) infections can lead to significant pathology in man, the urinary tract (bladder, ureters and kidneys) being the main target (reviewed in Gilles, 1982). Many studies have been undertaken to describe the lesions accompanied with *S.h.* infections and to investigate their functional significance (Warren et al., 1979; Gilles, 1982; Degrémont, 1983). Up to now lesions have been detected mainly by intravenous pyelography (IVP) (Umerah, 1981; Young et al., 1974), cystoscopy, and, more recently computerized tomography (Aisen et al., 1983). However, these techniques are invasive or need sophisticated equipment and high expertise. For these reasons, they have been used only at a hospital level and almost exclusively for individual diagnosis. IVP has been used for community and longitudinal studies (Forsyth and MacDonald, 1965; Forsyth, 1969; Rugemalila et al., 1979), but its large scale use is limited due to logistic and ethical problems. Bladder calcifications, which are very specific of *S.h.* infections, have also been observed by abdominal X-ray during morbidity surveys (Holzer et al., 1983), but their functional significance as morbidity index needs further investigations.

Ultrasonography is well known to be a safe, non-invasive and efficient technique to monitor disease in man and is being widely used in internal medicine, gynecology and obstetrics. This technique has rarely been used up to now for investigating urinary tract lesions due to *S.h.* infections (Abdel-Wahab, 1982; Hanash et al., 1984; Abdul Khair et al., 1980; Meier et al., 1983; Browning et al., 1984), but its potential application seems remarkable (Degrémont et al., 1985). Thus, the present study was undertaken to compare ultrasonography with conventional methods of investigation, such as IVP and cystoscopy.

Patients and Methods

The study was undertaken from July to November 1983 in a rural area of SE Tanzania at St. Francis District Hospital, Ifakara. Urinary schistosomiasis is endemic in the Kilombero valley and its epidemiological data are being investigated (Zumstein, 1983; Tanner et al., 1983; Marti et al., 1985).

Patients

The 125 patients considered in this study were chosen among out-patients of St. Francis Hospital and, therefore, not selected at random. Ninety-eight of them presented either: 1. *S.h.* eggs in a urine sample, or 2. microhaematuria (concomitant or without excretion of *S.h.* eggs), or 3. a positive schistosomiasis serology, or 4. received schistosomiasis treatment during the past year. Another 27 patients with none of the above mentioned criteria were included for comparison. There were 52 children (5–15 years) and 73 adults.

Besides ultrasound examination patients underwent: 1. a short case history with reference to the urinary tract and a clinical examination, 2. a urine examination by dip stick and by filtration for *S.h.* eggs, 3. a blood examination for haemoglobin, creatinine and white-blood cells count, 4. a schistosomiasis serology.

X-ray facilities at St. Francis hospital did not allow to screen 50 patients by IVP as scheduled, but only 29. Sonography plus IVP, sonography plus cystoscopy, and sonography plus IVP plus cystoscopy were performed on 18, 19 and 11 patients, respectively. Twenty-three out of 29 patients

who underwent IVP, and 29 out of 30 who underwent a cystoscopy were selected before sonographical examination. The remaining patients presented pathological findings in ultrasound, which prompted IVP or cystoscopy.

Furthermore, abdominal X-ray was taken on 4 patients at the end of the study, when it became evident that sonography was insufficient to detect small calcifications of the bladder wall.

The adult patients or the guardians of the children gave oral consent to participate in the study. *S.h.* infected participants were treated with Metrifonate (single dose, 10 mg/kg). For most of the patients follow-up after therapy was not feasible.

Methods

Urine specimens were collected between 9 and 12 a.m. and examined for blood, protein and leucocytes by Combur-9 reagent strips (Boehringer Mannheim, FRG). For detection of *S.h.* eggs, urine was passed through a 12 μ m Nucleopore membrane (Nucleopore Corp., Pleasanton, CA, USA) as described by Zumstein (1983). Serodiagnosis of schistosomiasis was performed by ELISA using *S. mansoni* egg antigen according to Speiser (1982).

Sonographical examinations were performed with a 3 MHz transportable real time linear scanner ("Sonoline 1000", Siemens, Erlangen, FRG). Three different contact media were used and compared: 1. a commercial gel (Aquasonic, Parker Laboratories, Orange, N. J., USA) pure, and 2. diluted (1:3) with distilled water in order to reduce the cost, and 3. a selfmade gel (*Tragacanthum* powder and distilled water, 1:20 with little glycerol to make it smoother for use). The quality of the echograms was excellent, thus all three media were comparable.

For documentation a Nikon FE camera was used with a 55 mm macro-objective lens and a black and white film (Kodak Plus-X 125 ASA). Pictures were first printed as contact copies and enlarged when needed. For each patient examined, at least 4 pictures were taken of each kidney and of the urinary bladder in transverse and longitudinal sections.

Patients were usually examined in the supine position, but when results were poor, the scanning was performed in prone position. The examiner (AB) had been trained in Switzerland 3 months prior to the study. Pictures were blindly interpreted by an ultrasound specialist (RM) in Basel. Interpretations by the two examiners correlated well with regard to the degree of dilatation of the calico-pyelic system and the changes on the bladder wall. The only noticeable differences came up in defining fissures and mild hydronephrosis, where the expert interpreted about 25% of the fissures as mild hydronephrosis. This did not influence the conclusions at all.

For the kidneys, four types of congestive changes were recorded according to Ellenbogen et al. (1978): fissure, mild hydronephrosis, moderate hydronephrosis and advanced hydronephrosis (Figs. 1–4). Congestion of the ureter was also checked. Fissures were considered as normal on the right kidney and as mild hydronephrosis on the left kidney (Lutz and Meudt, 1984). Advanced hydronephrosis and hydroureter were regrouped. Where a congestive change was seen, the patient was asked to empty his bladder and reexamined to prevent the diagnosis of kidney congestion merely due to a full bladder (Gill and Curtis, 1977; Morin and Baker, 1979). Only the second results were recorded. Other kidney changes (mainly blurred central echo complex) were recorded, but not evaluated in this study since they are mostly related to bacterial infection.

Special attention was paid to the structure of the bladder wall (Fig. 5–6): its regularity, thickness and the appearance of tumors or calcifications. The thickness of the bladder wall was measured and recorded as pathological when ≥ 5 mm. It was also noted if the wall was thickened all over or only in a circumscribed region such as the trigonum area.

Intravenous pyelograms (IVP) were performed as usual (Older et al., 1981; Cramer and de Lacey, 1980) with a plain abdominal X-ray being taken before injection of the contrast medium (Telebrix 38, Lab. Gerber, Aulnay s/Bois, F), and pictures at 5, 15 and 25 min intervals. Readings were done in Tanzania and independently by a radiologist in Switzerland.

All *cystoscopies* were performed without prior knowledge of other results (WS) under short general anesthesia for patients younger than 15 years. Lesions were described as: inflammation, sandy patches (specific changes for urinary schistosomiasis), nodules, polyps or papillomas, tumor, anomalies of the ureteric ostia (widened or narrowed) with additional mention of their localization.

Analysis

To compare egg output, the geometric mean of (x+1) eggs per 10ml \pm standard deviation was used. Whenever appropriate χ^2 test, one way analysis of variance (Anova) and Mann-Whitney U-rank test were applied for statistical analysis.

Results

The prevalence of *S.h.* infections among all 125 examined patients was 62% with a geometric mean (x+1) egg output (\pm S.D.) of 9 eggs/10 ml \pm 10. Ninety-eight (78%) were infected and had either *S.h.* positive urine and/or positive schistosomiasis serology and/or microhaematuria. The remaining 27 patients, not excreting eggs and showing a negative serology for schistosomiasis, but living in an endemic area, cannot be conclusively considered as *S.h.* negative based on a single urine examination. They may have lost their infection spontaneously or after specific treatment. For this reason, all 125 patients were analysed together. Children had significantly higher geometric mean (x+1) egg output (31 ± 12 eggs/10 ml) compared to adults (2.4 ± 4) (U-test, $2p < 0.0001$).

Pathological findings of the kidneys detected by sonography and geometric mean (x+1) egg output are presented in Table 1. Among children, lesions of the right kidney showed significant correlation with egg output. Out of 125 patients examined, 28 (22%) showed congestive changes. Of those 28, 13 had only one kidney affected and 15 both kidneys. There were no significant differences between the two kidneys with regard to pathologies.

The prevalence of major urinary tract lesions attributed to *S.h.* was compared with urine findings (Table 2). For fissures and mild hydronephrosis (Figs. 1, 2) the prevalences of microhaematuria, proteinuria and leucocyturia

Table 1. Pathological findings of the kidneys detected by sonography and *S.h.* egg output in urine among 125 patients

	Right kidney					Left kidney				
	Total	Children** (5–15 years)		Adults (≥ 16 years)		Total	Children (5–15 years)		Adults (≥ 16 years)	
		N	eggs*	N	eggs*		N	eggs*	N	eggs*
Normal	87	36	30	51	3	84	36	26	48	3
Fissure	5	2	7	3	1	8	4	12	4	3
Mild hydronephrosis	9	3	5	6	2	8	3	26	5	2
Moderate hydronephrosis ..	5	3	3221	2	0	5	3	473	2	0
Advanced hydronephrosis ..	4	3	61	1	0	4	1	140	3	2
Other changes	12	4	9	8	2	15	5	62	10	1
Not judgeable	3	1	2	2	3	1	–	–	1	10

* eggs = Geometric mean of x+1 eggs/10 ml urine

** one-way analysis of variance = $2p < 0.02$

Table 2. Prevalence (P) of major urinary tract lesions detected by sonography, intravenous pyelography and/or cystoscopy, compared to urinary findings among 125 patients

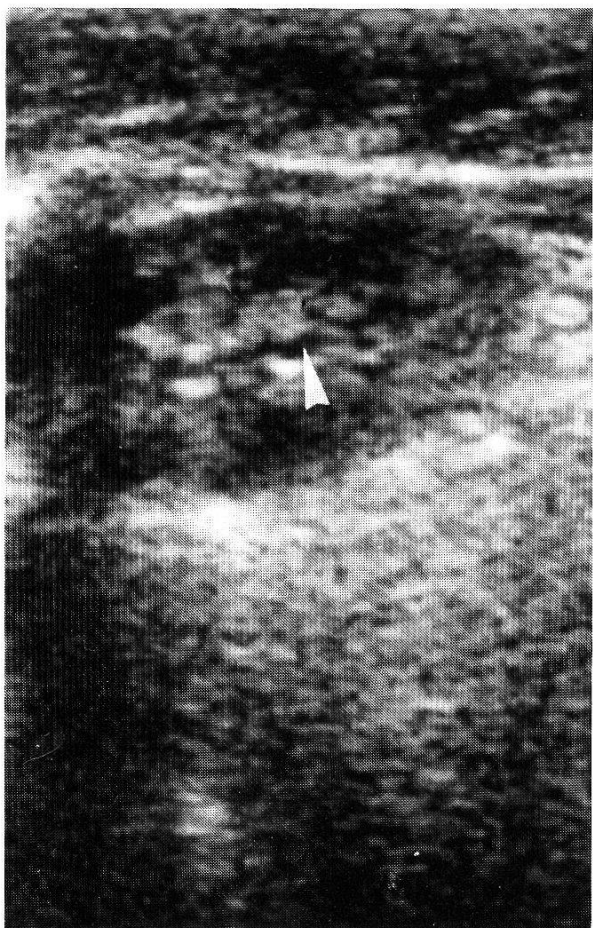
Findings in sonography, IVP and/or cystoscopy	N	P %	Urinary findings			
			<i>S.h.</i> pos. %	Haemat- uria* (≥+) %	Protein- uria* (≥++) %	Leucocyt- uria* (≥+) %
<i>Kidneys</i>						
Normal or minor lesions both sides	113	90	68	65	15	59
Moderate and advanced hydronephrosis:						
unilateral	6	5	83	100	100	100
bilateral	6	5	67	86	86	100
<i>Bladder</i>						
Normal	42	34	54	54	7	48
Thickened wall	70	56	66	66	23	73
Irregular wall	62	50	68	69	32	76
Irregular and thickened wall ...	54	43	70	67	30	72
Calcifications	8	8	75	75	13	75
Tumor	3	2.4	67	100	67	67

* assessed by semiquantitative reagent strips (Combur-9)

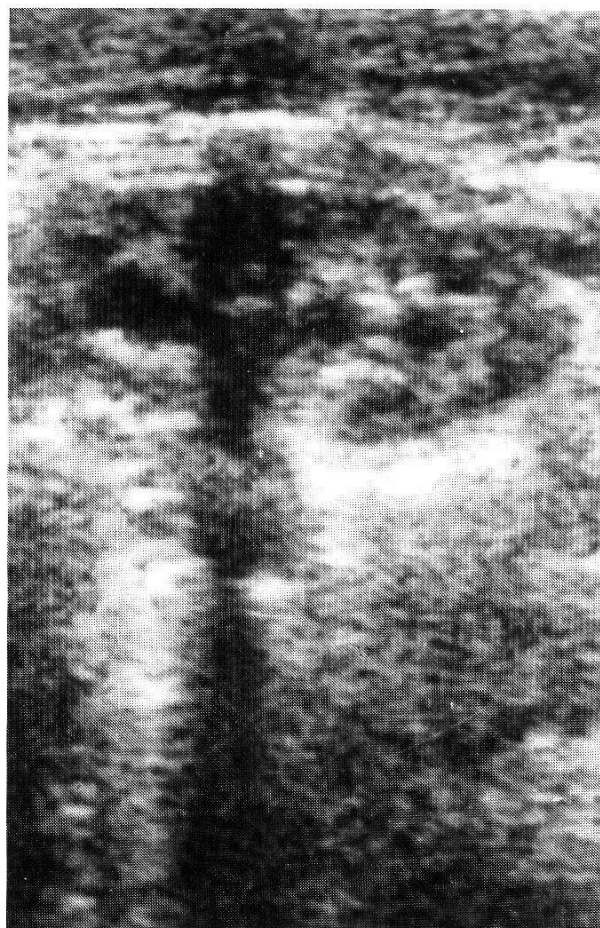showed no significant difference with normal kidneys. Major kidney pathologies (Figs. 3, 4) were always associated with hematuria and leucocyturia, in most cases also with proteinuria. For bladder alterations (Figs. 5, 6), this was not the case.

All children with major congestive changes of the kidneys presented an irregular bladder wall. In comparison to children without kidney lesion the correlation was significant ($\chi^2 = 2p < 0.001$). There was no such correlation among adults. The geometric mean egg output was significantly higher in children presenting sonographically diagnosed bladder thickening (U-test, $2p < 0.002$), bladder irregularity ($2p < 0.001$) or both ($2p < 0.001$) when compared with normal children.

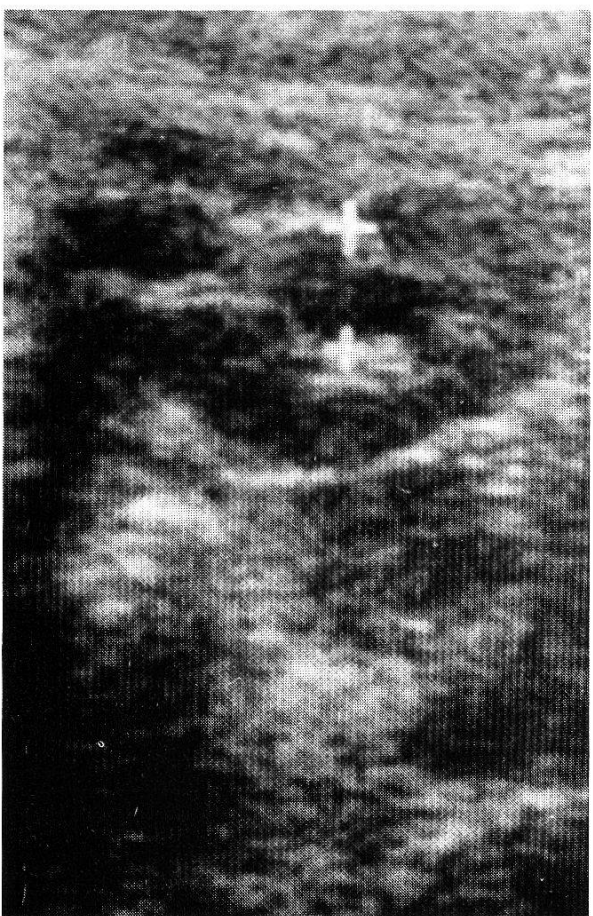
The results of sonography of the kidney and IVP of 29 patients are presented in Table 3. "Other changes" seen by ultrasound and described as normal by IVP are: two cases of bilateral normvariations or malformations of very large kidneys; one case of bilateral multiple cysts with suspicion of an unilateral tumor and one case with an inflammatory right kidney. Considering the dilatation of the pylon and the calices, the results of ultrasound correlate positively with those of IVP as shown also by Rosenfield (1982) and Amis et al. (1982).



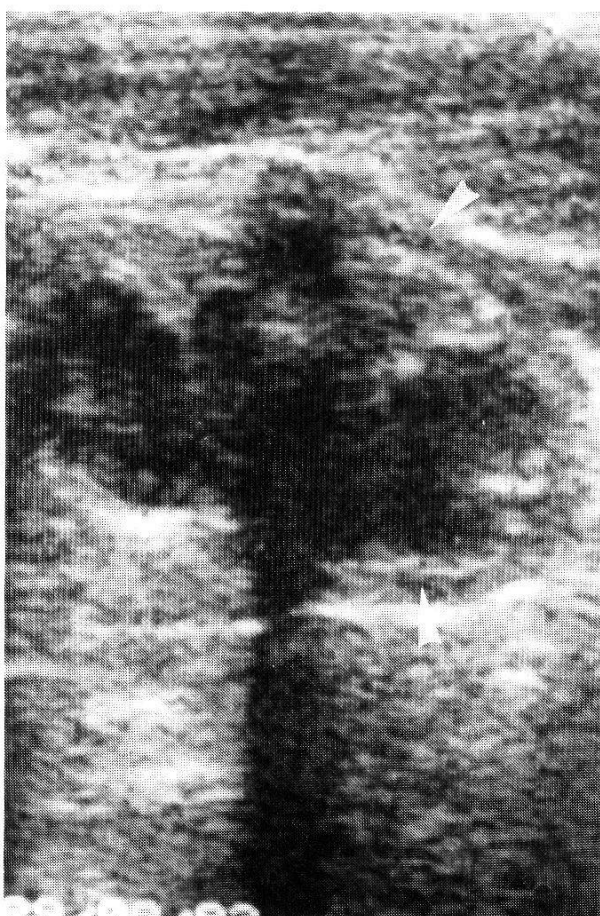
1



2



3



4

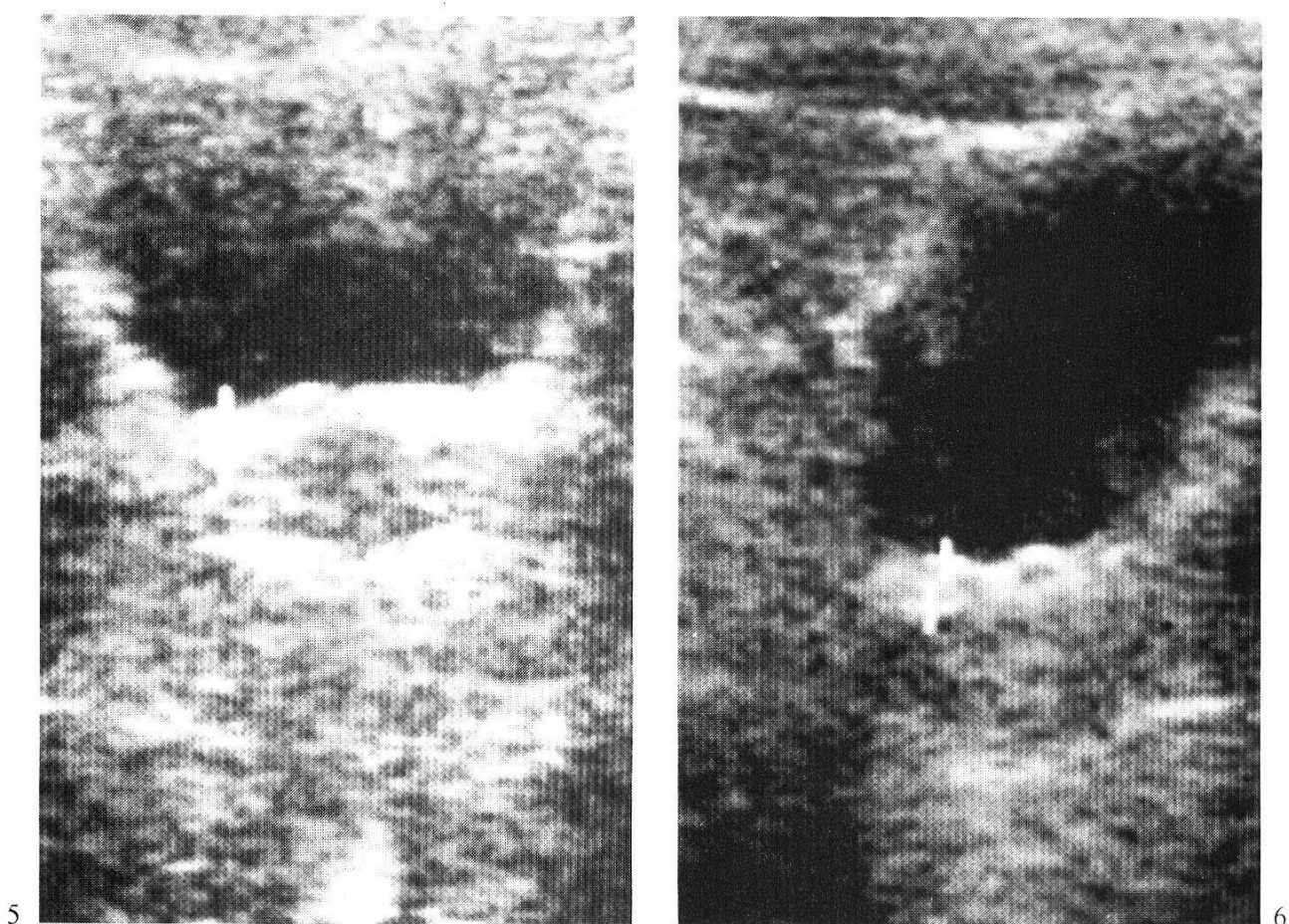


Fig. 5. Thickened bladder wall (+...+) = 5 mm), transverse section.

Fig. 6. Irregular and thickened bladder wall (+...+ = 6 mm), length section.

One notes only 2 false negative results for mild hydronephrosis by sonography and one for moderate hydronephrosis by IVP.

There is no correlation between ultrasound and *X-ray* findings of the bladder. The evaluation was made on 31 cases. Five calcifications were not seen by ultrasound and 3 patterns of calcifications at sonography could not be confirmed by X-ray. Among children, those with "abnormal bladders" in bladder X-ray showed a significantly higher geometric mean egg output with 698 ± 10 eggs/10 ml compared to normal children with 17 ± 8 eggs/10 ml (U-test, $2p < 0.02$).

The comparison between ultrasound and *cystoscopy* of the bladder is presented in Table 4. Among adults, the mean number of eggs was found to be significantly higher in those presenting pathological lesions such as inflammation (U-test, $2p < 0.02$), sandy patches ($2p < 0.02$) and nodules ($2p < 0.001$). The

Fig. 1. Minimal dilatation of the central echocomplex defined as fissure (→).

Fig. 2. Mild hydronephrosis.

Fig. 3. Moderate hydronephrosis with measurement of dilatation of one calix-group (+...+).

Fig. 4. Advanced hydronephrosis with narrowing of the parenchyma (→).

Table 3. Comparison of sonography and intravenous pyelography of the kidneys among 29 patients

Sonography	Intravenous pyelography									
	Right kidney					Left kidney				
	Normal	Mild hydrone.	Moderate hydrone.	Advanced hydrone.	Other changes	Normal	Mild hydrone.	Moderate hydrone.	Advanced hydrone.	Other changes
Normal	10	2	0	0	0	8	0	0	0	0
Mild hydronephrosis*	3	1	1	0	0	6	1	1	1	1 ²
Moderate hydronephrosis ...	0	1	1	3	0	1	0	0	2	0
Advanced hydronephrosis ...	0	0	0	1	1 ¹	0	0	1	1	0
Other changes	4	0	0	0	0	4	0	0	0	1 ³

* included "fissure" on left kidney

¹ silent kidney

² chronic inflammatory process or tumor by IVP

³ double kidney interpreted as hypernephroma by sonography

Table 4. Comparison sonography and cystoscopy of the bladder among 30 patients

Sonography*	Cystoscopy**					
	Normal	Nodular	Sandy patches	Fibrosis	Inflammation	Tumor
Normal	6	4	5	2	4	0
Irregular	2	2	2	1	2	0
Thickened (≥ 5 mm)	3	1	2	2	2	0
Thickened + irregular	17	12	11	7	16	1
Tumor***	2	1	0	2	2	2
Total	30	20	21	14	26	3

* Two bladder sonographies were not judgeable.

** The same patient could have different pictural lesions.

*** Tumors at sonography were associated with thickened and irregular bladder wall.

tumor seen by ultrasound as very irregular and thickened bladder wall was reported by the cystoscopist as a nodule with tumorous aspect. The two other tumors were diagnosed by sonography and confirmed by cystoscopy, without prior knowledge of the ultrasonic result. None of them were diagnosed as tumorous process by abdominal X-ray. One tumor was observed in a 10-year-old child with more than 3000 *S.h.* eggs/10 ml urine. The two others were seen in adults with positive urines, but very low egg counts (<10 eggs/10 ml).

Discussion

Sonography has proved to be a highly sensitive method for investigating diseases affecting the urinary tract especially those causing congestive changes (Ellenbogen et al., 1978; Rosenberg, 1982). We could show that this is also true for detecting changes due to *S.h.* as sonography compares favorably with IVP in visualizing kidney lesions and with cystoscopy in case of bladder lesions.

In defining the degree of congestive changes ranging from mild to severe hydronephrosis the two methods differ somewhat. While ultrasonography is certainly more sensitive than IVP in detecting slight congestions, its specificity as indicator of a pathological process with functional significance related to *S.h.* infection is sometimes questionable; especially in cases of "fissure" or "mild hydronephrosis" (Figs. 1, 2) where the egg count was not significantly higher than in all normal patients (Table 1). It is therefore likely to assume that slight changes of the pyelon are not specific for *S.h.* infections.

In differentiating "moderate" from "advanced hydronephrosis" (Figs. 3, 4), ultrasound is superior to IVP as it shows not only the degree of dilatation of the pyelo-caliceal system, but also the thickness of the renal parenchyma. The latter

is narrowed in case of advanced hydronephrosis as a sign of compression or fibrosis (Rosenfield, 1982; Peake et al., 1983; Chopra et al., 1980). This differentiation is not possible with IVP and thus explains the lack of correlation between the two techniques in grading congestions. Sonographically confirmed narrowing of the parenchyma may explain, why among 8 kidneys classified by ultrasonography as moderate hydronephrosis, only 1 was confirmed by IVP while 5 presented themselves as advanced hydronephrosis (Table 3). Evidently the latter cases must be classified as "incomplete" hydronephrosis.

In the case of silent kidney in IVP, sonography was definitely more conclusive, as it allowed to visualize this kidney in the state of advanced hydronephrosis (Arafa et al., 1982; Behan et al., 1979).

Sonographical examinations and IVPs were neither performed at the same time nor the same day. Depending on renal excretion and bladder retention, short term fluctuations of congestion seem possible and need further studies. Longitudinal studies will reveal the significance of these different congestive changes after treatment and possibly explain the interesting findings of Forsyth (1969), who described that one third of "hydronephrosis" detected by IVP were spontaneously reversible.

The present study shows that calcifications of the bladder wall, which are associated with *S.h.* infections, could not be detected by sonography. This is in contrast to some recent reports from other endemic areas (Abdel-Wahab, 1982; Doebling et al., 1985a, b). The reasons for the failure of ultrasonography to depict calcifications may be technical ones. The linear scanner used for this study detects calcifications down to 2–3 mm. The calcified plaques in the bladder wall caused by fibrosed *S.h.* eggs, however, are below 1 mm size. It remains to be established, if sector scanners are able to detect calcifications.

In accordance with Hanash et al. (1984) and Egender et al. (1982) we agree that ultrasound is a valuable and sensitive tool to detect tumorous processes of the bladder also when related to *S.h.* Furthermore, 80% of nodules and 75% of sandy patches as seen by cystoscopy were identified by sonography as thickening and/or irregular changes of the bladder wall (Table 4). Cystoscopy is certainly a more sensitive diagnostic means than sonography, but the latter compares well, is safe (Bang, 1981; Hill, 1981), more convenient for the patient and easier to perform.

The time required to perform an IVP or cystoscopy made it impossible to apply these methods to a large scale screening without interfering with the activity of the hospital. Therefore few patients could be examined during a 3-month period by at least one of these two techniques in order to compare them with ultrasound. Furthermore around 40% of the patients scheduled for those examinations did not show up.

The use of common black and white films processed by ourselves revealed to be very cost effective when compared to more sophisticated means of documentation using fast processing films such as Polaroid.

It is well known that *S.h.* related morbidity correlates with the intensity of infection as reflected by the egg output especially among children (Gilles, 1982). The egg output further correlates positively with haematuria and proteinuria. The correlations between the sonographical lesions and the results of the urine examination can give indications on the degree of morbidity of *S.h.* among a population as well as confirm the value of the method applied.

As described earlier the intensity of infection in the studied area is not very high when compared with other endemic areas despite of a high frequency of microhaematuria (Tanner et al., 1983). However, the prevalence of all congestive changes of the kidneys was found to be high (22%). The small number of pathological cases did not always allow a statistical analysis, but moderate and advanced hydronephrosis were associated with children showing higher egg output and important haematuria, leucocyturia and proteinuria. There was no significant difference for mild hydronephrosis. We may conclude that only moderate and advanced hydronephrosis as detected by ultrasonography are predominantly related with *S.h.* infection. The origin of proteins and leucocytes in urine is still controversial. Different authors believe them to be related to upper urinary tract superinfections (Gilles, 1982; Sabbour et al., 1972) while others suggest postrenal origin (Doehring et al., 1985c; Dukes et al., 1967). We can only state that both leucocyturia and proteinuria were always present in important kidney changes with high egg output, while this was not always the case in bladder alterations. This suggests that both renal and postrenal alterations can cause proteinuria and leucocyturia in *S.h.* infections.

The comparison between ultrasonographically revealed lesions of the bladder and urine examinations shows a significantly higher egg output among children with thickened and/or irregular wall (Figs. 5, 6). Nevertheless, 31 to 34% of the children with a thickened and/or irregular bladder wall showed no haematuria and/or no *S.h.* egg in urine. It remains to be established which proportion refers to parasitologically missed cases (as only one examination was performed), to inadequate interpretations of sonographical picture or to recently cured infections (spontaneously or after treatment). The fact that all children with major congestive changes on the kidneys presented an irregular bladder wall confirms that among children most of the moderate and advanced hydronephrosis are related to *S.h.* infection.

Summarizing, the present study supports that ultrasound is a highly valuable means to assess *S.h.* related morbidity. It compares well with conventional methods of investigation and its important pathological findings correlate positively with the urinary findings in schistosomiasis. As it is non-invasive, void of adverse reactions, accurate and easy to handle, it can also be applied successfully in field studies within communities as shown recently (Degrémont et al., 1985; Doehring et al., 1985b). In addition, this allows to carry out longitudinal studies in order to determine the predictive value of quantitative and semi-quantitative urine examinations in assessing morbidity. Its usefulness in man-

aging individual patients affected by urinary bilharziasis remains to be established.

Acknowledgments

We gratefully acknowledge the support of this study by Prof. W. Kilama (Director General, National Institute of Medical Research Tanzania), Dr. S. Tayari (District Medical Officer) and Dr. W. Moll (Medical Superintendent, St. Francis Hospital, Ifakara). We thank Dr. F. Kink, who kindly cross-checked our X-ray films as well as Miss A. Schaer, Mr. R. Suter and all the staff of the Field Laboratory of Ifakara for their excellent technical assistance. The manuscript was kindly reviewed by Dr. K. E. Mott and carefully typed by Mrs. M. Bürgin. Finally, special attention is due to all the examined patients, whose excellent cooperation contributed to the success of the present study.

- Abdel-Wahab M. F.: Schistosomiasis in Egypt. CRS Press, Florida 1982.
- Abdul-Khair M. H., Arafa N. M., Sobeih A. M., Talaab A. A. A.: Sonography of bilharzial masses of the scrotum. *J. clin. Ultrasound* 8, 239–240 (1980).
- Aisen A. M., Gross B. H., Glazer G. M.: Computed tomography of uretero-vesical schistosomiasis. *J. Comput. Assist. Tomogr.* 7, 161–163 (1983).
- Amis E. S., Cronan J. J., Pfister R. C., Yoder Y. C.: Ultrasonic inaccuracies in diagnosing renal obstruction. *Urology* 19, 101–105 (1982).
- Arafa N. M., Fathi M. M., Safwat M., Moro H., Torky H., Kenawi M., Abdel-Wahab M. F.: Accuracy of ultrasound in the diagnosis of non-functioning kidneys. *J. Urol. (Baltimore)* 128, 1165–1169 (1982).
- Bang J.: Clinical aspects of diagnostic ultrasound. In: Recent advances in ultrasound diagnosis 3, ed. by A. Kurjak and A. Kratochwil, p. 30–32. Excerpta Medica, Amsterdam/Oxford/Princeton 1981.
- Behan M., Wixson D., Kazam E.: Sonographic evaluation of the nonfunctioning kidney. *J. clin. Ultrasound* 7, 449–458 (1979).
- Browning M. D., Narooz S. I., Strickland G. T., El-Masry N. A., Abdel-Wahab M. F.: Clinical characteristics and response to therapy in Egyptian children infected with *Schistosoma haematobium*. *J. infect. Dis.* 149, 998–1004 (1984).
- Chopra A., Teek R. L.: Hydronephrosis in children: narrowing the differential diagnosis with ultrasound. *J. clin. Ultrasound* 8, 473–478 (1980).
- Cramer B., de Lacey G.: Intravenous urography. *Brit. med. J.* 281, 661–663 (1980).
- Degrémont A.: Les schistosomiasis sont-elles des maladies débilitantes? *Schweiz. Rundschau Med. (Praxis)* 29, 973–981 (1983).
- Degrémont A., Burki A., Burnier E., Schweizer W., Meudt R., Tanner M.: Value of ultrasonography in investigating morbidity due to *Schistosoma haematobium* infection. *Lancet* 1985, 662–665.
- Doehring E., Ehrich J. H. H., Dittrich M.: Ultrasound in urinary schistosomiasis (letter). *Lancet* 1985a, 1930.
- Doehring E., Ehrich J. H. H., Reider F., Dittrich M., Schmidt-Ehry G., Brodehl J.: Morbidity in urinary schistosomiasis: relation between sonographical lesions and pathological urine findings. *Trop. Med. Parasit.* 36, 145–149 (1985b).
- Doehring E., Ehrich J. H. H., Vester U., Feldmeier H., Poggensee U., Brodehl J.: Proteinuria, haematuria and leucocyturia in children with mixed urinary and intestinal schistosomiasis. *Kidney int.* 28, (in press) (1985c).
- Dukes D. C., MacDougall B. R. D., Orne-Gliemann R. H., Davidson L.: Urinary leucocyte excretion in African subjects: its relation to bacteriuria and the passage of bilharzial ova in urine. *Brit. med. J.* 1967/I, 537–538.
- Egenger G., Goidinger K., Jakse G.: Klassifikation der Harnblasentumoren durch die Sonographie. *Fortschr. Röntgenstr.* 136, 416–420 (1982).

- Ellenbogen P. H., Scheible F. W., Talner L. B., Leopold G. R.: Sensitivity of gray scale ultrasound in detecting urinary tract obstruction. *Amer. J. Roentgenol.* 130, 731–733 (1978).
- Forsyth D. M.: A longitudinal study of endemic urinary schistosomiasis in a small East African community. *Bull. Wld Hlth Org.* 40, 771–783 (1969).
- Forsyth D. M., MacDonald G.: Urological complications of endemic schistosomiasis in schoolchildren. Part I: Usagara School. *Trans. roy. Soc. trop. Med. Hyg.* 59, 171–178 (1965).
- Gill W. B., Curtis G. A.: The influence of bladder fullness on upper urinary tract dimensions and renal excretory function. *J. Urol. (Baltimore)* 117, 573–576 (1977).
- Gilles, in: *Schistosomiasis, epidemiology, treatment and control*, ed. by P. Jordan and G. Webbe, p. 79–104. Heinemann, London 1982.
- Hanash K. A., Bissada N. K., Abba A., Esmail D., Dowling A.: Predictive value of excretory urography, ultrasonography, computerized tomography, and liver scan in the staging of bilharzial bladder cancer in Saudi Arabia. *Cancer (Philad.)* 54, 172–176 (1984).
- Hill C. R.: Interactions of ultrasound with tissues. In: *Recent advances in ultrasound diagnosis 3*, ed. by A. Kurjak and A. Kratochwil, p. 67–70. Excerpta Medica, Amsterdam/Oxford/Princeton 1981.
- Holzer B., Saladin B., Saladin K., Dennis E., Degrémont A.: The impact of schistosomiasis among rural populations in Liberia. *Acta trop. (Basel)* 40, 239–260 (1983).
- Lutz A., Meudt R.: *Manual of ultrasound*. Springer, Berlin 1984.
- Marti H. P., Tanner M., Degrémont A., Freyvogel T. A.: Studies on the ecology of *Bulinus globosus*, the intermediate host of *Schistosoma haematobium* in the Ifakara area, Tanzania. *Acta trop. (Basel)* 42, 171–187 (1985).
- Meier V., Willi U., Stahel E.: Hämaturie bei Bilharziose durch *Schistosoma mansoni*. *Monatsschr. Kinderheilk.* 131, 45–46 (1983).
- Morin M. E., Baker D. A.: The influence of hydration and bladder distention on the sonographic diagnosis of hydronephrosis. *J. clin. Ultrasound* 7, 192–194 (1979).
- Older R. A., Moore A. V. jr., McLelland R.: Excretory urography: update 1980. *CRC Crit. Rev. Diagn. Imaging* 16, 1–42 (1981).
- Peake S. L., Rokburgh H. B., Langlois S. L. P.: Ultrasonic assessment of hydronephrosis of pregnancy. *Radiology* 146, 167–170 (1983).
- Rosenberg R. E.: Ultrasonographic evaluation of the kidney. *CRC Crit. Rev. Diagn. Imaging* 17, 239–276 (1982).
- Rosenfield A. T.: Ultrasound evaluation of renal parenchymal disease and hydronephrosis. *Urol. Radiol.* 4, 125–133 (1982).
- Rugemalila J. B.: The impact of urinary schistosomiasis on the health of two community populations living in endemic areas in Tanzania. *Trop. geogr. Med.* 31, 375–380 (1979).
- Sabbour M. S., El-Said W., Abou-Gabal I.: A clinical and pathological study of schistosomal nephritis. *Bull. WHO* 47, 549–557 (1972).
- Speiser F.: Serodiagnosis of tissue dwelling parasites: application of a multiantigen to enzyme-linked-immunosorbent assay (ELISA) for screening. *Ann. Soc. belge Méd. trop.* 62, 103–120 (1982).
- Tanner M., Holzer P., Marti H. P., Saladin B., Degrémont A.: Frequency of haematuria and proteinuria among *Schistosoma haematobium* infected children in two communities from Liberia and Tanzania. *Acta trop. (Basel)* 40, 231–237 (1983).
- Umerah B. C.: Bilharzial hydronephrosis: a clinico-radiological study. *J. Urol. (Baltimore)* 126, 164–165 (1981).
- Warren K. S., Mahmoud A. A. F., Muruku J. F., Whittaken L. R., Ouma J. H., Arap Siongok T. K.: Schistosomiasis haematobia in Coast Province Kenya. *Amer. J. trop. Med. Hyg.* 28, 864–870 (1979).
- Young S. W., Khalid K. H., Farid Z., Mahmoud A. H.: Urinary-tract lesions of *Schistosoma haematobium*. *Radiology* 111, 81–84 (1974).
- Zumstein A.: A study of some factors influencing the epidemiology of urinary schistosomiasis at Ifakara (Kilombero District, Morogoro Region, Tanzania). *Acta trop. (Basel)* 40, 187–204 (1983).

