

Experimental infection of the domestic donkey ("Equus asinus asinus") with a goat strain of "Sarcoptes scabiei" and treatment with ivermectin

Autor(en): **Abu-Samra, M.T. / Ali, B.H. / Musa, B.E.**

Objekttyp: **Article**

Zeitschrift: **Acta Tropica**

Band (Jahr): **42 (1985)**

Heft 3

PDF erstellt am: **22.05.2024**

Persistenter Link: <https://doi.org/10.5169/seals-313472>

Nutzungsbedingungen

Die ETH-Bibliothek ist Anbieterin der digitalisierten Zeitschriften. Sie besitzt keine Urheberrechte an den Inhalten der Zeitschriften. Die Rechte liegen in der Regel bei den Herausgebern.

Die auf der Plattform e-periodica veröffentlichten Dokumente stehen für nicht-kommerzielle Zwecke in Lehre und Forschung sowie für die private Nutzung frei zur Verfügung. Einzelne Dateien oder Ausdrucke aus diesem Angebot können zusammen mit diesen Nutzungsbedingungen und den korrekten Herkunftsbezeichnungen weitergegeben werden.

Das Veröffentlichen von Bildern in Print- und Online-Publikationen ist nur mit vorheriger Genehmigung der Rechteinhaber erlaubt. Die systematische Speicherung von Teilen des elektronischen Angebots auf anderen Servern bedarf ebenfalls des schriftlichen Einverständnisses der Rechteinhaber.

Haftungsausschluss

Alle Angaben erfolgen ohne Gewähr für Vollständigkeit oder Richtigkeit. Es wird keine Haftung übernommen für Schäden durch die Verwendung von Informationen aus diesem Online-Angebot oder durch das Fehlen von Informationen. Dies gilt auch für Inhalte Dritter, die über dieses Angebot zugänglich sind.

¹ Departments of Medicine, Pharmacology and Toxicology, and

² Surgery, Obstetrics and Gynaecology, Faculty of Veterinary Science, University of Khartoum, Sudan

Experimental infection of the domestic donkey (*Equus asinus asinus*) with a goat strain of *Sarcoptes scabiei*, and treatment with ivermectin

M. T. ABU-SAMRA¹, B. H. ALI¹, B. E. MUSA², K. E. E. IBRAHIM¹

Summary

Donkeys were experimentally infected with *Sarcoptes scabiei* from goats, proving that this mite is not completely host specific. The lesions produced on the donkeys were characterized by extensive areas of alopecia, covered with thin crusts and bran-like scales. The skin had many excoriations but showed no cracks or fissures. Skin scrapings from the experimental lesions in donkeys contained numerous mites of all stages and skin sections showed severe histopathological changes, proving that the goat mites had become well established and were reproducing actively in experimental lesions. Treatment of the donkeys with ivermectin produced excellent and rapid cure.

Key words: infection of donkeys with *Sarcoptes scabiei*; transmission of *Sarcoptes scabiei* from goats to donkeys; ivermectin in the treatment of sarcoptic mange in donkeys.

Introduction

Sarcoptes scabiei is an ubiquitous mite which infects domestic and wild animals as well as man (Kral and Schwartzman, 1964; Soulsby, 1968; Fain, 1968, 1978). Though very similar, the parasites from different species exhibit unique physiological characteristics, so that some workers considered them as different 'biological races' or even different species altogether (Soulsby, 1968; Howell et al., 1978; Blood et al., 1979). However, Fain (1968, 1978) conducted

Correspondence: Dr. Mukhtar T. Abu-Samra, Departments of Medicine, Pharmacology and Toxicology, Faculty of Veterinary Science, University of Khartoum, P.O. Box 2278, Khartoum, Sudan

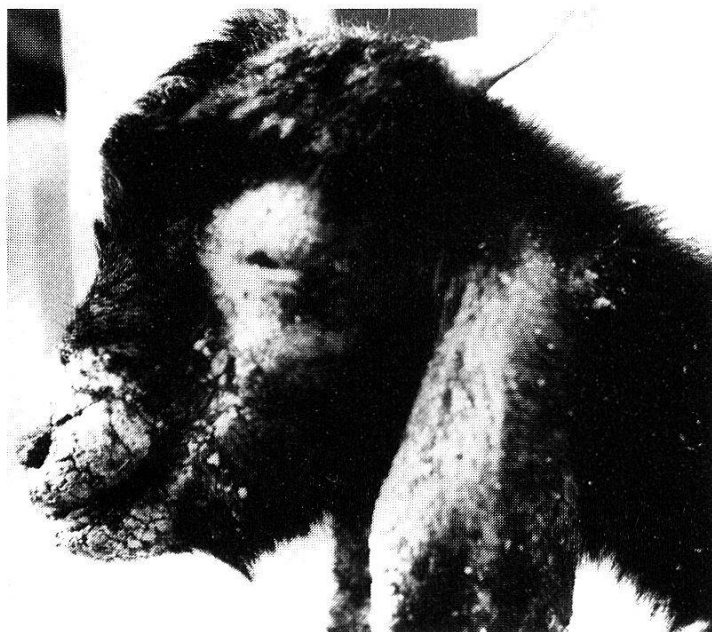

Fig. 1. A field case of severe sarcoptic mange in a goat showing thick fissured scab on the lips, muzzle, bridge of nose, round the eyes, on the cheeks and ears.

an extensive study on the genus *Sarcoptes scabiei* and concluded that it contains only 1 valid but variable species.

The host specificity of the mite has been challenged and several attempts were made to transmit the mite from one domestic animal to another (Kral and Schwartzman, 1964; Soulsby, 1968; Blood et al., 1979). Human scabies following contact with water buffaloes infected with *S. scabiei* was reported by Chakrabarti et al. (1981) and scabies in camels was reported to be zoonotic (Higgins, 1983).

Fain (1978) reported that the frequent interbreeding of the mite in zoologically remote mammals has on the one hand prevented speciation and on the other hand provided new genetic characters which have enhanced the adaptability of the mite to infest other hosts. Sarcoptic mange in sheep and goats has previously been studied (Abu-Samra et al., 1981a and b); and experimental transmission of the parasite between these species has recently been carried out successfully (Abu-Samra et al., 1984).

Ivermectin is a new broad-spectrum antiparasitic agent which has been used successfully in many species (for a review see Campbell and Benz, 1984). However, till now no work has been reported about the use of this drug in donkeys.

To our knowledge there is no report in the literature about sarcoptic mange in the donkey. However, several cases of psoroptic mange in this species have been brought to our clinic for treatment. Donkeys in this country are usually kept in close contact with other animals, particularly goats and sheep, and the possibility of infection from these species is quite likely. Therefore, it was

thought worthwhile attempting to transmit *Sarcoptes scabiei* from naturally infected goats to healthy donkeys to evaluate the severity of the lesions produced, follow the course of the disease and attempt to treat the lesions produced with ivermectin which is probably used for the first time in the treatment of donkeys.

Materials and Methods

Infective materials

Deep skin scrapings were collected immediately before the start of the experiment, using several goats naturally infected with severe and advanced lesions of sarcoptic mange (Fig. 1). The scrapings were pooled, thoroughly mixed and examined in 20% potassium hydroxide to confirm the heaviness of the infestation with *Sarcoptes scabiei*. The mites were also checked for viability.

Animals

Four male donkeys, aged approximately 7 to 10 years, weighing 125–150 kg and in good condition, were purchased from premises with no history of previous mange infection. Each donkey was placed in a clean disinfected stable and kept on a high plane of nutrition.

Experiment

On both sides of each of the four donkeys (Nos. 1 to 4), skin on the chest was clipped and shaved. Immediately before infection numerous superficial abrasions approximately 5 cm long and covering the shaved areas were then made, using a Cristalet lancet (Hawksley and Sons Ltd., London). Donkeys Nos. 1 to 3 were infected by placing positive skin scrapings from goats on pads of cotton wool which were then inverted to make contact with the prepared areas. The cotton wool pads were then bandaged round the body of the donkeys so as to hold the scrapings in place and prevent the animals from scratching or licking the experimentally infected areas. Control donkey No. 4 was similarly bandaged but without the application of skin scrapings.

Clinical observations

A week after infection the bandages were removed and the infected areas were examined and rebanded. Two weeks after the original infection the bandages were removed, and the progress of the lesions observed. Deep skin scrapings and skin biopsy specimens were collected from the developing lesions at weekly intervals.

Ten weeks after infection the experimental donkeys Nos. 2 and 3 were treated with ivermectin (Ivomec, MSD, Agvet). Each donkey was injected subcutaneously with 3 ml of the drug. Donkey No. 1 was not treated and left as control.

Laboratory investigations

Skin scrapings collected from the experimentally produced lesions were examined under the microscope in 20% potassium hydroxide. The skin biopsy specimens were fixed in 10% formal saline, embedded in wax, cut at 5 μ m and stained with Haematoxylin and Eosin (H & E).

Results

By the end of the second week many raised areas of 1–2 cm in diameter appeared on the infected sites which showed intense hyperaemia on the white donkey No. 2. By week 3 many papules and vesicles appeared on the infected areas and the animals were persistently gnawing and scratching the infected

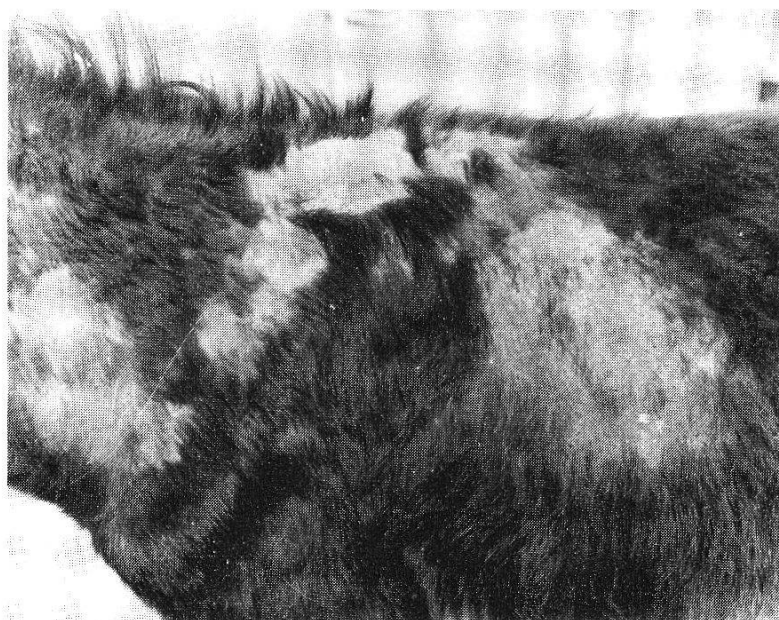

Fig. 2. Donkey No. 3, five weeks after infection with a goat strain of *S. scabiei*, showing linear spread of lesions on the back, wither and base of the neck.

areas against the walls of their stables. By week 4, the infected areas became covered with minute white bran-like scales and showed numerous scab-covered lesions of 2–4 mm in diameter. In donkeys Nos. 2 and 3, the muzzle and mouth commissures became involved showing alopecia, hyperaemia and many papules and vesicles. The animals were persistently scratching and gnawing at the infected areas. By week 5 the infected areas became covered with thick greyish-white crusts, showing many excoriations which were oozing a serohaemorrhagic exudate. The infected areas became wider and the lesions spread in a linear fashion on the back of the animal along the withers to the base of the neck (Fig. 2). In donkeys Nos. 2 and 3 the lesions on the muzzle became covered with a yellow scab and the animals were seen rubbing their muzzle against the walls and door of their stables. In donkey No. 1 similar lesions started to appear. By weeks 7 and 8 the lesions spread, covering the bridge of nose, down the cheeks, muzzle, mouth commissures, half-way above the base of the neck, withers, shoulders to elbow and whole chest except for a strip of 7 to 10 cm above the sternum. The hair at the periphery of the lesions was soiled with bran-like scales and could easily be plucked-off. By weeks 9 and 10 the experimental donkeys had an extensive area of alopecia, covered with thin crusts and bran-like scales and showing many excoriations resulting from the continued gnawing and scratching. The skin over those areas was hard and leathery in consistency, but without cracks or fissures.

Control donkey No. 4 had thin scab on the lacerated areas. The scab was completely shed and the skin over the area was normal within 12 days.

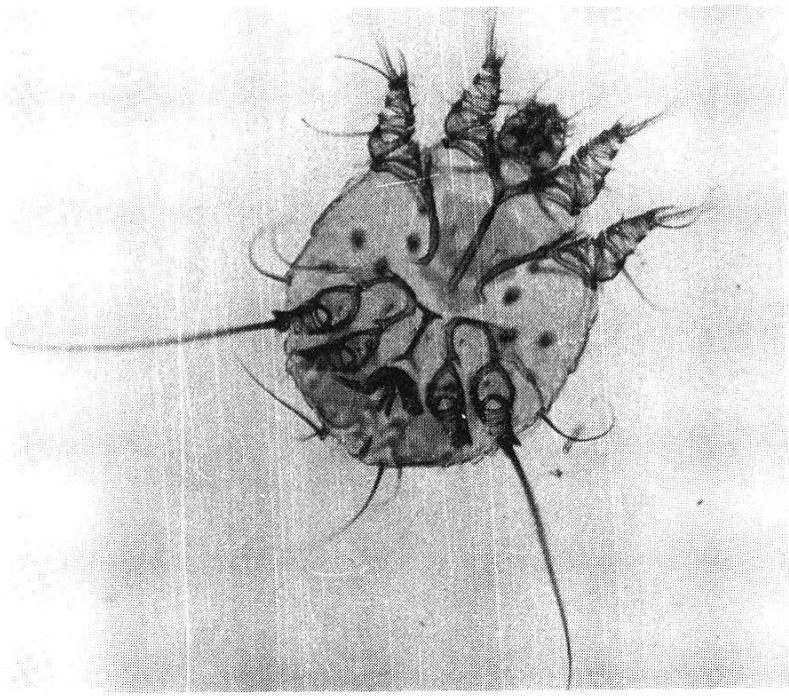


Fig. 3. *Sarcoptes scabiei* in skin scrapings from an infected donkey. 20% KOH. $\times 90$.

Treatment

Ten days after the treatment with ivomec, donkeys Nos. 2 and 3 became calm, showing only little itching. Fifteen days after treatment, most of the crusts and scales were shed from the infected areas. Complete shedding of the crusts and scales occurred by the 21st to 25th day. The lesions completely cleared and the skin regained its normal texture 30 to 35 days after treatment. Until the preparation of this manuscript (14 weeks after infection), the untreated donkey No. 1 continued showing severe lesions and signs of sarcoptic mange.

Laboratory investigations

Viable *Sarcoptes scabiei* (Fig. 3) mites were seen under the dissection microscope in skin scrapings from the experimentally produced lesions. By weeks 5 to 10 numerous adult mites, nymphs, wandering and stationary larvae, and eggs were seen.

Two weeks after the treatment of donkeys No. 2 and 3 with ivomec, very few live mites were seen and the skin scrapings were negative for mites, three weeks after treatment. In the untreated donkey No. 1, many adult mites, nymphs, wandering and stationary larvae and eggs were seen in skin scrapings collected 14 weeks after infection.

Skin sections from the experimental donkeys within 2 to 4 weeks of infection revealed slight hyperkeratosis, acanthosis, dilatation of the blood capillaries, severe epidermal and dermal haemorrhages, oedema of the epidermal cells and infiltration with lymphocytes and eosinophils.

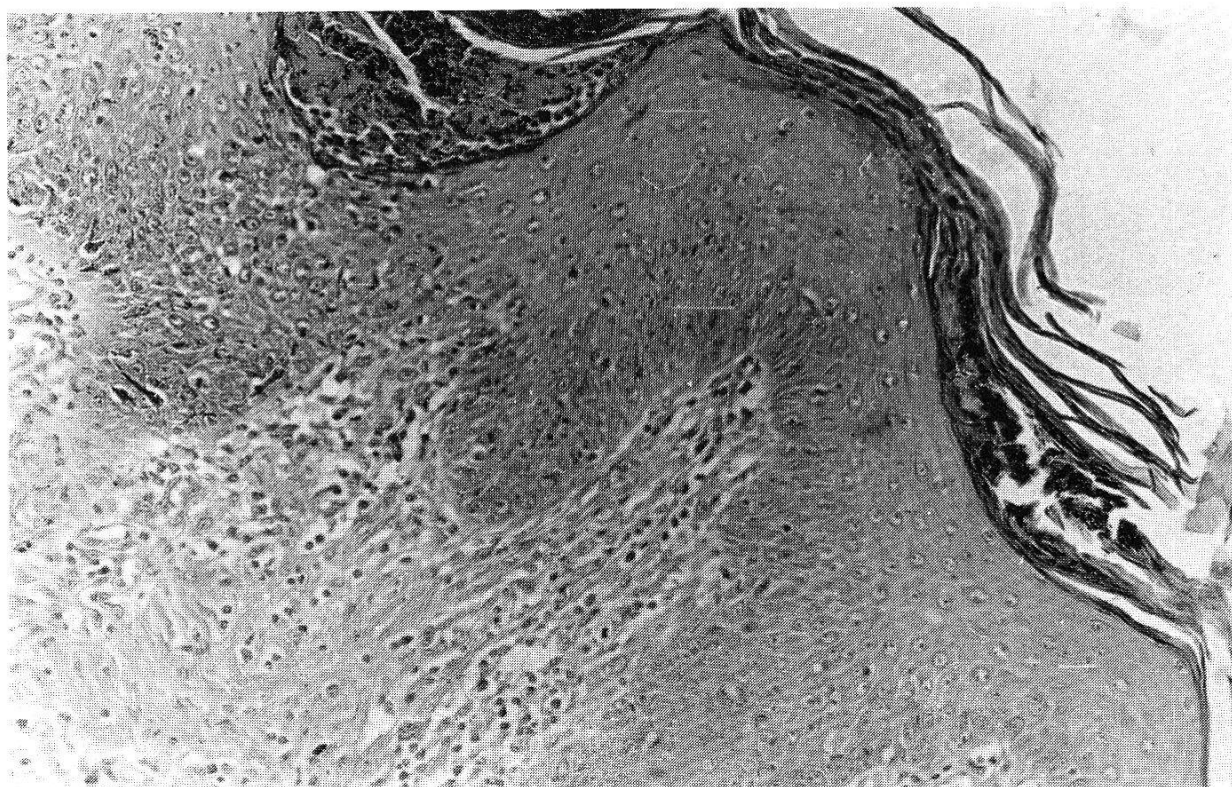


Fig. 4. Section of skin from donkey No. 3 infected with a goat strain of *S. scabiei*, showing hyperkeratosis, acanthosis, scab formation and infiltration with inflammatory cells. H & E. $\times 100$.

By weeks 5 to 10 there was marked hyperkeratosis, and scab formation (Fig. 4). Shreds of mites were seen beneath the scab and keratin. The scab was infiltrated with degenerate polymorphs. There were marked degenerative and necrotic changes in the epidermis. The blood capillaries were dilated and there was some haemorrhage in the upper dermis and proliferation of the dermal connective tissue. The papillary layer and dermis were infiltrated with eosinophils, macrophages, lymphocytes and a few neutrophils.

In the untreated donkey No. 1 there was more keratin and scab formation, proliferation of the dermal connective tissue and infiltration with eosinophils.

Discussion

Sarcoptes scabiei from goats was successfully transmitted from their natural host to donkeys proving that the host specificity of *Sarcoptes* is incomplete. This finding substantiates the statements of Kral and Schwartzman (1964), Soulsby (1968), Fain (1978) and Blood et al. (1979), and authenticates the results of Abu-Samra et al. (1984) who transmitted *S. scabiei* from sheep to goats.

The lesions produced on the donkeys were very severe and spread from the site of infection to cover an extensive area of the body. The affected areas had alopecia, were covered by bran-like scales and crusts, and showed areas of

excoriations, but the skin was free of crackings and fissures. The severity of these lesions could not be properly compared for lack of reports on similar natural infection with sarcoptic mange in donkeys. However, these lesions were similar to the dense powdery coating observed on the body of goats naturally infected with sarcoptic mange (Abu-Samra et al., 1981b) but was different from the thick multifissured scab observed on the muzzle, lips, outer surfaces of the ears and on the fetlocks and coronets of sheep and goats naturally infected with sarcoptic mange (Abu-Samra et al., 1981a and b) or on the lesions produced in goats infected with a sheep strain of *S. scabiei* (Abu-Samra et al., 1984).

The lesions produced contained numerous eggs, larvae, nymphs and viable adult mites, proving that the goat strain of *S. scabiei* mites got well established in donkeys, that the mites were reproducing actively and were able to persist strongly through many generations. A further evidence for this were the severe histopathological changes seen in skin sections. Moreover, the lesions did not disappear without treatment and this was contrary to Kotlán (1936), who reported that non-specific mite infections cause only transient lesions that disappear without treatment.

As was suggested by Kral and Schwartzman (1964), Soulsby (1968), Howell et al. (1978), Blood et al. (1979) and Abu-Samra et al. (1984), the spread of the lesions beyond the infected areas and the involvement of the donkeys' heads probably resulted from the persistent scratching and gnawing of the infected areas.

Ivermectin was effective in treating the experimental sarcoptic mange in donkeys and no untoward effects were observed in the treated animals.

From the present findings, and the reports of Fain (1968, 1978) and Abu-Samra et al. (1984) it is evident that the low host specificity of the infection necessitates complete isolation of the infected animals from the healthy ones regardless of the species involved.

- Abu-Samra M. T., Hago B. E. D., Aziz M. A., Awad F. M.: Sarcoptic mange in sheep in the Sudan. Ann. trop. Med. Parasit. 75, 639–645 (1981a).
- Abu-Samra M. T., Imbabi S. E., Mahgoub E. S.: Mange in domestic animals in the Sudan. Ann. trop. Med. Parasit. 75, 627–637 (1981b).
- Abu-Samra M. T., Ibrahim K. E. E., Abdel Aziz M.: Experimental infection of goats with *Sarcoptes scabiei* var. *ovis*. Ann. trop. Med. Parasit. 78, 55–61 (1984).
- Blood D. C., Henderson J. A., Radostits O. M.: Veterinary medicine, 5th ed., p. 819–820. Baillière, Tindall and Cassell, London 1979.
- Campbell W. C., Benz G. W.: Ivermectin: a review of efficacy and safety. J. vet. Pharmacol. Therap. 7, 1–16 (1984).
- Chakrabarti A., Chatterjee A., Chakrabarti K., Sengupta D. N.: Human scabies from contact with water buffaloes infested with *Sarcoptes scabiei* var. *bubalis*. Ann. trop. Med. Parasit. 75, 353–357 (1981).
- Fain A.: Etude de la variabilité de *Sarcoptes scabiei* avec une révision des Sarcoptidae. Acta zool. pathol. antverp. 47, 1–196 (1968).
- Fain A.: Epidemiological problems of scabies. Int. J. Dermatol. 17, 20–31 (1978).

- Higgins A. J.: Observations on the disease of the Arabian camel (*Camelus dromedarius*) and their control (Review). Vet. Bull. 53, 1089–1100 (1983).
- Howell C. J., Walker J. B., Nevill E. M.: Ticks, mites and insects infesting domestic animals in South Africa. Part I: description and biology. Sci. Bull. Dept. of Agric. Tech. Serv. Rep. S. Afr. 393, 39–40 (1978).
- Kotlán S.: A rühatkák fajlagosságának kérdéséhez (On the specificity of mange mites) (in Hungarian language). Állatorv. Lapok. 59, 345–347 (1936).
- Kral F., Schwartzman R. M.: Veterinary and comparative dermatology, p. 343–368. J. B. Lippincott Company, Philadelphia/Montreal 1964.
- Soulsby E. J. L.: Helminths, arthropods and protozoa of domesticated animals, 6th ed., p. 503–507. Baillière, Tindall and Cassell, London 1968.