

Zeitschrift: Acta Tropica
Herausgeber: Schweizerisches Tropeninstitut (Basel)
Band: 41 (1984)
Heft: 4

Artikel: Pathology of experimental infection with "Brugia malayi" in ferrets : comparison with occult filariasis in man
Autor: Crandall, R.B. / Thompson, J.P. / Connor, D.H.
DOI: <https://doi.org/10.5169/seals-313314>

Nutzungsbedingungen

Die ETH-Bibliothek ist die Anbieterin der digitalisierten Zeitschriften auf E-Periodica. Sie besitzt keine Urheberrechte an den Zeitschriften und ist nicht verantwortlich für deren Inhalte. Die Rechte liegen in der Regel bei den Herausgebern beziehungsweise den externen Rechteinhabern. Das Veröffentlichen von Bildern in Print- und Online-Publikationen sowie auf Social Media-Kanälen oder Webseiten ist nur mit vorheriger Genehmigung der Rechteinhaber erlaubt. [Mehr erfahren](#)

Conditions d'utilisation

L'ETH Library est le fournisseur des revues numérisées. Elle ne détient aucun droit d'auteur sur les revues et n'est pas responsable de leur contenu. En règle générale, les droits sont détenus par les éditeurs ou les détenteurs de droits externes. La reproduction d'images dans des publications imprimées ou en ligne ainsi que sur des canaux de médias sociaux ou des sites web n'est autorisée qu'avec l'accord préalable des détenteurs des droits. [En savoir plus](#)

Terms of use

The ETH Library is the provider of the digitised journals. It does not own any copyrights to the journals and is not responsible for their content. The rights usually lie with the publishers or the external rights holders. Publishing images in print and online publications, as well as on social media channels or websites, is only permitted with the prior consent of the rights holders. [Find out more](#)

Download PDF: 09.07.2025

ETH-Bibliothek Zürich, E-Periodica, <https://www.e-periodica.ch>

¹ College of Medicine, University of Florida, Gainesville, FL, USA

² Armed Forces Institute of Pathology, Washington, D.C., USA

³ Walter Reed Army Institute of Research, Washington, D. C., USA

Pathology of experimental infection with *Brugia malayi* in ferrets: comparison with occult filariasis in man

R. B. CRANDALL¹, J. P. THOMPSON¹, D. H. CONNOR²,
P. B. MCGREEVY³, C. A. CRANDALL¹

Summary

Ferrets experimentally infected with *Brugia malayi* (subperiodic strain) developed eosinophilia at patency and usually became amicrofilaremic. Ferrets necropsied within 3 months after becoming amicrofilaremic had granulomas and focal reactions to degenerating microfilariae in their livers, lungs and lymph nodes essentially identical to those of tropical eosinophilia. Four of 7 ferrets that received multiple inoculations of larvae, developed edema of the inoculated paw and leg after becoming amicrofilaremic and 6 of these 7 ferrets had granulomatous lymphangitis and lymphadenitis of inoculated limbs but not the lesions of lung and liver characteristic of occult infection.

Key words: *Brugia malayi*; filaria; occult filariasis; tropical eosinophilia; *Mustela putorius furo*; ferret; histopathology; liver; lungs; lymphatics.

Introduction

Filarial infection without microfilaremia (Beaver, 1970) can have diverse manifestations including tropical pulmonary eosinophilia (Weingarten, 1943) or lymphadenopathy with or without hepatosplenomegaly and pulmonary disease (Meyers and Kouwenaar, 1939). These infections are characterized by persistent eosinophilia, high levels of IgE (Neva et al., 1975) and focal inflammatory reactions to microfilariae (mf) in lung, lymph node, spleen or liver (Joe, 1962; Webb et al., 1960). Allergic hypersensitivity to antigens of mf is probably

Correspondence: Dr. R. B. Crandall, Department of Immunology and Medical Microbiology, Box J-266 JHMH, College of Medicine, University of Florida, Gainesville, Florida 32610, USA

a major factor in the pathogenesis of occult infections (Ottesen et al., 1979) but the immunopathology and predisposing factors have not been clarified.

In an initial study of infection of ferrets by *Brugia malayi*, the ferrets developed persistent eosinophilia, cleared mf from the circulation and had tissue reactions characteristic of tropical eosinophilia (Crandall et al., 1982). To evaluate further the ferret as an experimental model for occult filariasis, we have now studied the lesions of liver, lungs, lymph nodes and lymphatic vessels following single and multiple infections with *B. malayi* and compared the lesions with those of occult filariasis in man.

Materials and Methods

Animals and infections. Male ferrets were purchased from Marshall Research Animals, Inc. (North Rose, NY) and maintained in facilities accredited by the American Association for Accreditation for Laboratory Animal Care. Five ferrets, 3- to 4-years-old, were injected subcutaneously in the dorsum of the hind paws with 150–200 infective larvae of *Brugia malayi* (subperiodic strain); 3 of the ferrets were reinoculated with 150–200 larvae. In a second group, 6 of 10, 8- to 12-month-old ferrets, were injected with 90–100 larvae distributed in both hind paws and the remaining 4 ferrets received 7 injections of 25 larvae each in the right hind paws over a period of 5 months. The procedures for obtaining infective larvae, infecting the ferrets and measuring microfilaremia have been described (Crandall et al., 1982).

Pathology. Ferrets were bled at intervals from the jugular vein and differential leukocyte counts made. The necropsy procedures and preparation of tissues for histopathology have been described (Crandall et al., 1982). Prior to necropsy, 2% Evans Blue dye was injected subcutaneously in the hind paws to stain the draining lymphatics and lymph nodes. The popliteal lymph nodes and the inguinal lymph nodes, if enlarged, were removed for histologic study. Examination of the lymphatic vessels was confined to the dye-stained vessels associated with the popliteal or inguinal lymph nodes and to enlarged vessels occasionally observed in the skin of the lower leg. Surgical laparotomy and wedge biopsy of the liver was also performed (Archibald and Sumner-Smith, 1974).

Results

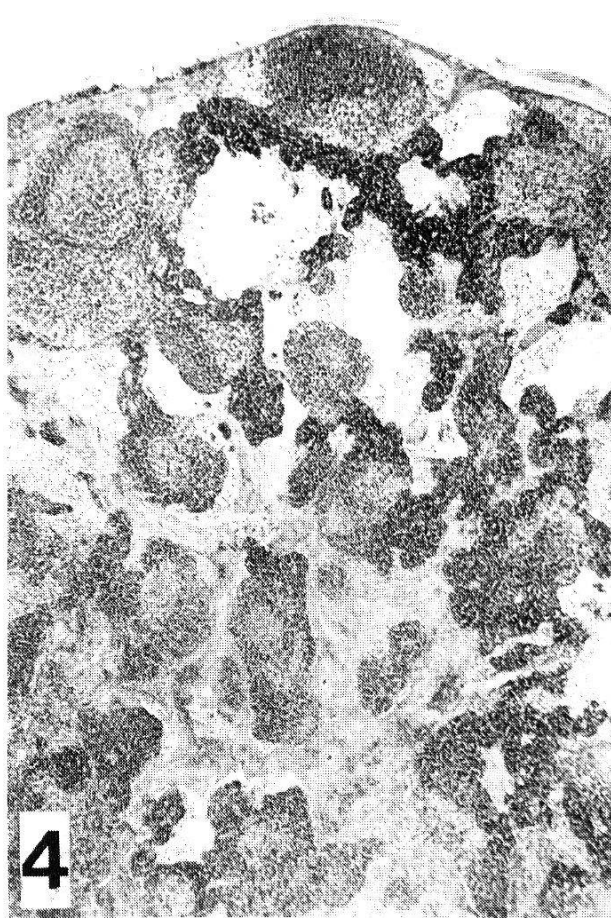
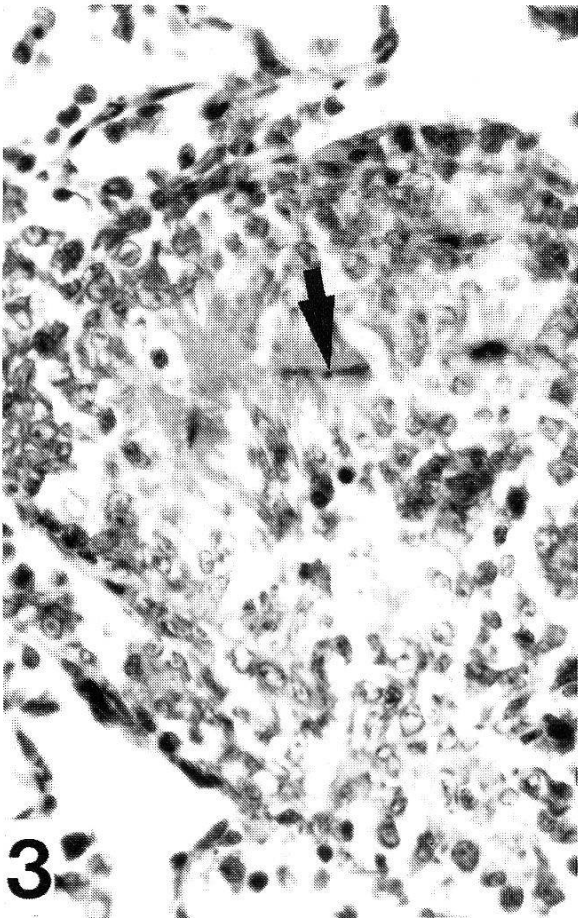
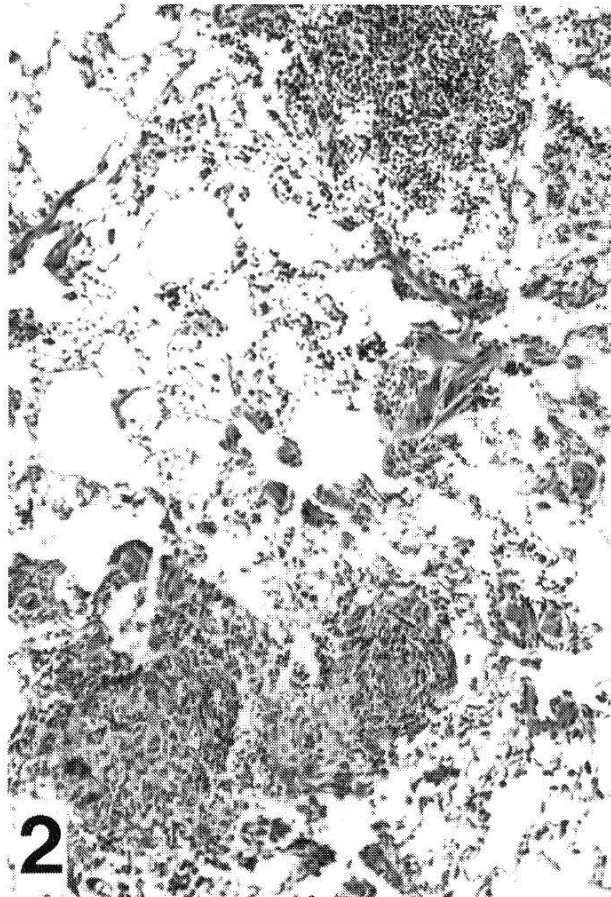
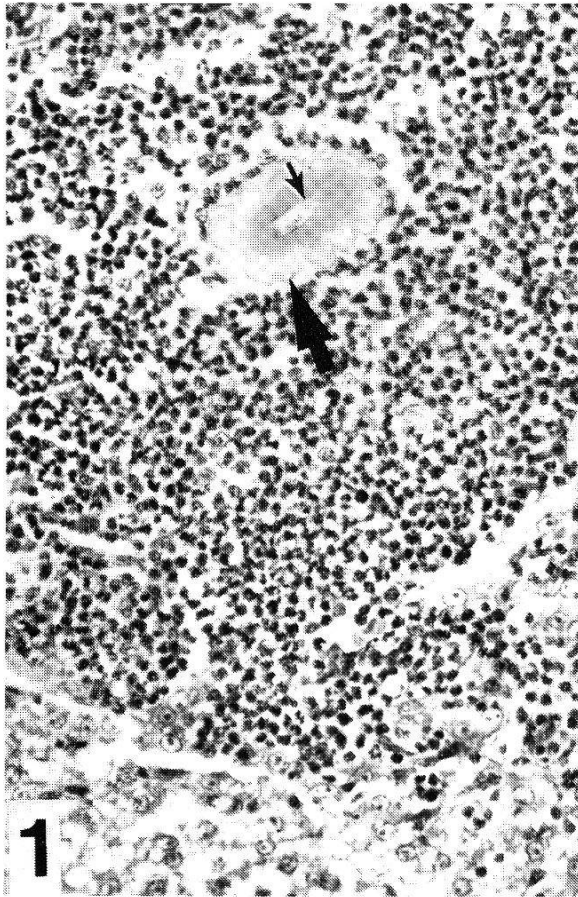
Experimental infections. The 5 ferrets injected with 150–200 infective larvae became patent during the third month after inoculation and were amicrofilaremic by the sixth month. Eosinophilia developed at patency and reached a maximum of 21–36% near the end of patency or in the early amicrofilaremic period. Two ferrets were necropsied within 6 weeks after becoming amicrofilaremic and 3 ferrets were reinfected with 150–200 larvae at 8 months after becoming amicrofilaremic and were necropsied 6 months later. The reinfected

Fig. 1. Eosinophilic abscess in the liver surrounding the carcass of a degenerating microfilaria (small arrow), encased in Splendore-Hoeppli substance (large arrow). H & E $\times 250$, AFIP No. 82–13734.

Fig. 2. Randomly disbursed granulomas within the lung. H & E $\times 100$, AFIP No. 82–13711.

Fig. 3. Pulmonary granuloma containing a degenerating microfilaria (arrow) encased in Splendore-Hoeppli substance. Giemsa $\times 400$, AFIP No. 82–13709.

Fig. 4. Enlarged lymph node with hyperplastic germinal centers and dilated sinuses containing histiocytes and lymph. Giemsa $\times 25$, AFIP No. 82–13724.



ferrets remained amicrofilaremic and 2 of them developed persistent edema of the lower legs and paws.

The younger group of ferrets all became patent, developed eosinophilia and had a variable period of microfilaremia. In ferrets given a single inoculation of 90–100 larvae, one has remained microfilaremic at levels greater than 1,000/ml for over one year and is still under study, 2 cleared mf from the circulation by the fifth month after inoculation and 3 cleared by the end of the first year. A liver biopsy was done on these ferrets at the fifth month after inoculation and they were later necropsied within 2 months after becoming amicrofilaremic. Of the 4 ferrets receiving multiple inoculations of larvae, one cleared mf by the fifth month after initial inoculation, 2 between the sixth and seventh month and one by the tenth month. Two of these ferrets developed edema of the injected paw and lower leg after becoming amicrofilaremic.

Histopathology. The livers and lungs of 20 experimentally infected ferrets were examined. Six of these ferrets were from a previous study (Crandall et al., 1982) and had been infected with 150–200 larvae and necropsied during clearance of mf from the circulation or at periods up to 3 months after the ferret became amicrofilaremic.

Grossly, the livers contained numerous lesions. These were on the surface and throughout the substance of the liver. They ranged from 0.5 to 2.0 mm across, were white, homogeneous and circumscribed but not encapsulated. Microscopically, each of these was an abscess comprised of eosinophils around the carcass of a degenerating mf. Most of the carcasses were encased in an eosinophilic coagulum characteristic of Splendore-Hoeppli (SH) material (Fig. 1). Some of the abscesses contained mf within SH deposits surrounded by a giant cell or epithelioid cells.

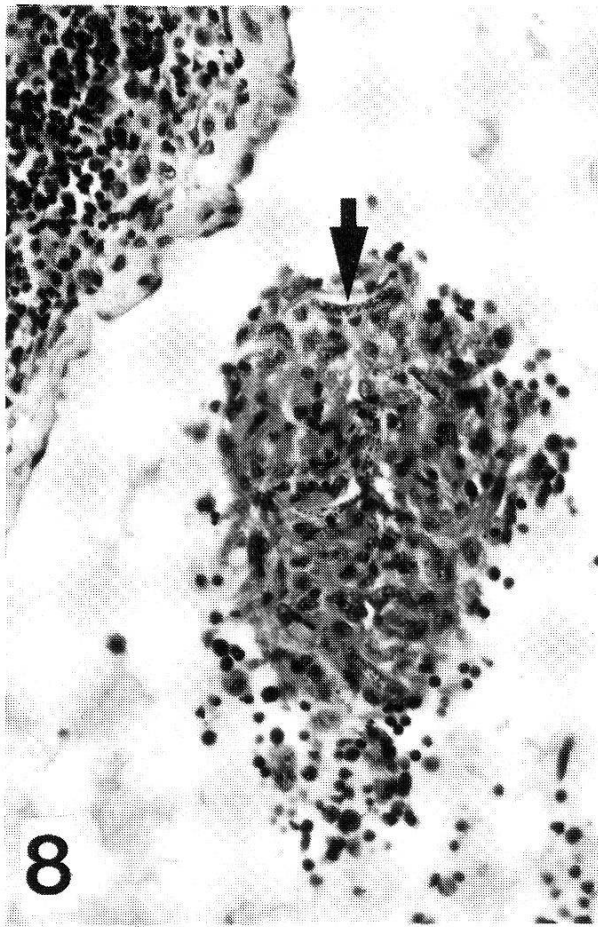
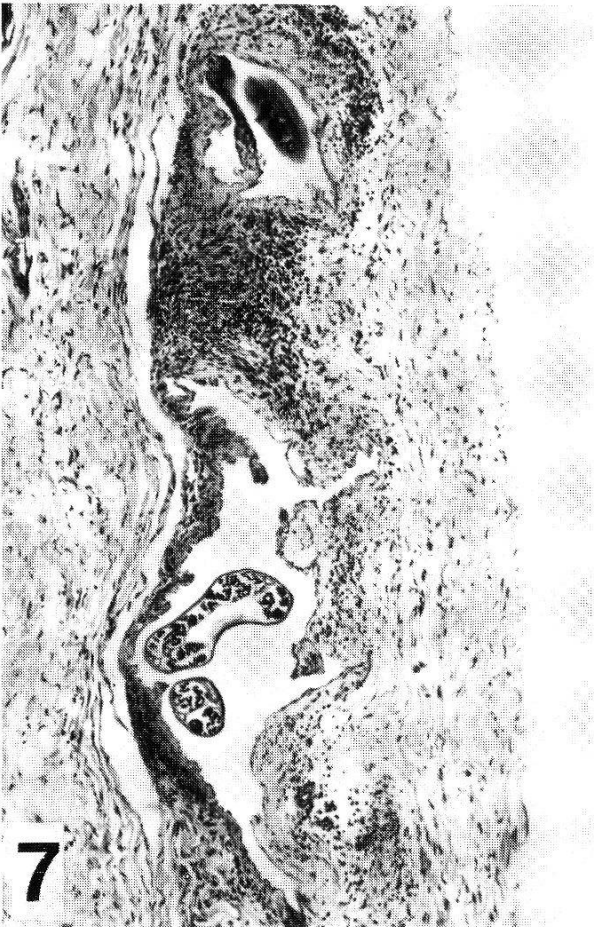
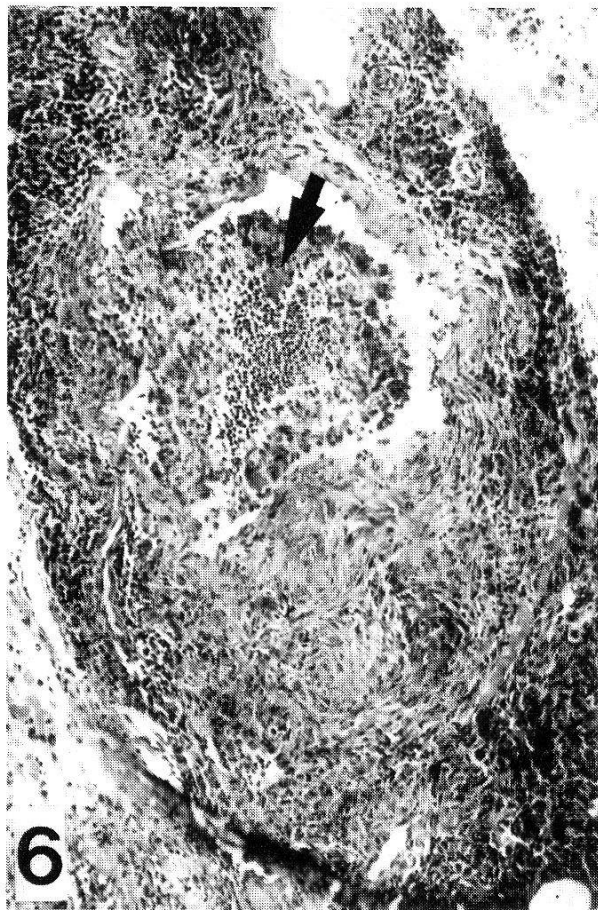
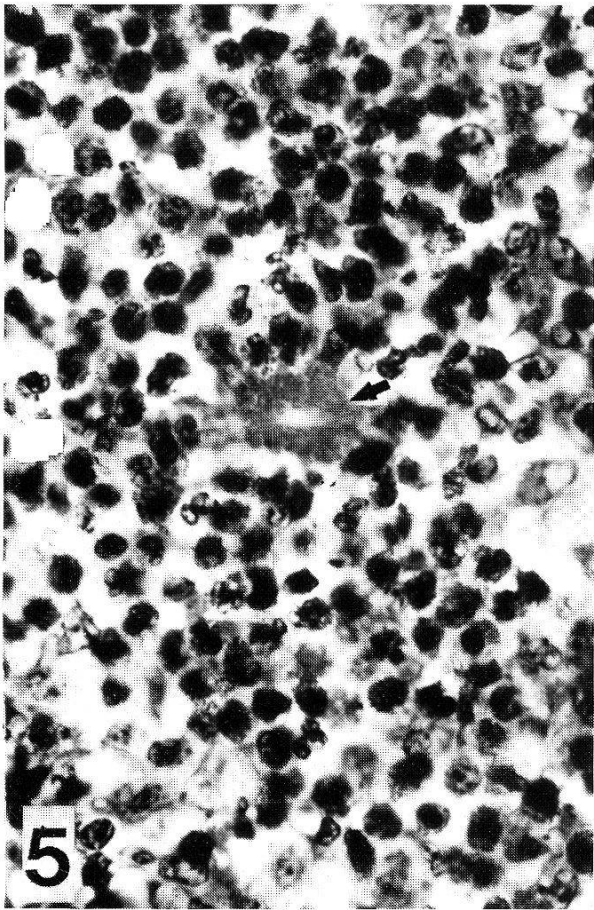
Degenerate giant surrounded by SH deposits also were observed within giant cells or surrounded by epithelioid cells within small granulomas in the liver. Several ferrets had few or no lesions of the liver; these ferrets included the reinfected animals described later in the text. Liver biopsy specimens of 6 ferrets taken at 5 months after infection contained numerous lesions in the 2 amicrofilaremic ferrets but few (<5) gross lesions in the specimens from the 4 microfilaremic ferrets. Only 1 of the 4 microfilaremic ferrets had microabscesses and granulomas in the liver typical of occult infection.

Fig. 5. A degenerating microfilaria in Splendore-Hoeppli substance (arrow) within an eosinophilic abscess in a lymph node. Giemsa $\times 630$ AFIP No. 83–7009.

Fig. 6. Lymphatic of a leg. The lumen is reduced to a crescent shaped slit by inflammation of the wall and a lymph thrombus. The lymph thrombus contains Splendore-Hoeppli substance (arrow) surrounded by eosinophils. Giemsa $\times 60$, AFIP No. 82–13715.

Fig. 7. Inflamed lymphatic of the deep dermis of a limb with a thickened wall and valves and containing a gravid filariae. Movat $\times 60$, AFIP No. 82–13715.

Fig. 8. Dilated, inflamed lymphatic containing a lymph thrombus which has enmeshed microfilariae (arrows). H & E $\times 250$, AFIP No. 83–7003.



The lungs of most ferrets had no gross lesions, but microscopically contained randomly dispersed granulomas composed of eosinophils, epithelioid cells, giant cells, lymphocytes and plasma cells (Fig. 2). Eosinophilic amorphous materials or a mf encased in SH deposits were in these granulomas usually surrounded by epithelioid and giant cells (Fig. 3). In the ferrets necropsied immediately after clearance of mf, or with small numbers of mf still circulating, the lungs had a diffuse, interstitial pneumonitis. Eosinophils and histiocytes with fewer giant cells and plasma cells expanded the interstices. Also, there were areas of peribronchiolar and perivascular cellular infiltration in which eosinophils were prominent. Siderophages were in the lungs of most of these animals. The ferrets with intense pulmonary inflammation also had numerous liver lesions; the ferrets without liver lesions had no pulmonary lesions.

Lymph nodes and lymphatic vessels were examined in 13 of the necropsied ferrets. Lymph nodes from the legs injected with larvae were enlarged and the lymphatics dilated; adult filariae were occasionally visible within the lymphatics. Microscopically the changes in the nodes and lymphatics were similar in the singly and multiply infected ferrets but tended to be more severe in the reinfected animals. Germinal centers in the nodes were hyperplastic and there was often a histiocytosis and dilation of the lymphatic sinuses (Fig. 4). A granulomatous endolymphangitis was common in the afferent lymphatic vessels and extended into the subcapsular sinuses; plasma cells were usually numerous in the medullary cords. Eosinophils were not conspicuous in most lymph nodes but small aggregates or abscesses were present in about one-half the nodes. Microfilariae were in lymph nodes of 11 ferrets. Some mf were intact and others were degenerating and surrounded by SH deposits, histiocytes and epithelioid cells or in aggregates of eosinophils (Fig. 5).

Changes in the lymphatic vessels were focal or regional. Adult filariae within a dilated vessel usually provoked little inflammation but adjoining areas could have marked perilymphangitis and endolymphangitis. Partial or complete occlusion of a lymphatic by a granulomatous reaction was common (Fig. 6). Other vessels were dilated and had thickened walls and valves (Fig. 7, 8). The immediate cause of lymphatic lesions often was not apparent but in 6 ferrets mf were in lymphthrombi (Fig. 8) and in a granulomatous endolymphangitis of histiocytes, epithelioid cells and giant cells. Microfilariae, occasionally covered by SH material, were also in aggregates of granulocytes within lymphatic vessels and outside these vessels in masses of inflammatory cells, mostly eosinophils. These inflammatory reactions to mf in the lymphatics were in ferrets with prominent liver and lung lesions but the most intense inflammatory reactions to mf were in an amicrofilaremic ferret with only a few liver lesions.

The 3 ferrets that had been reinfected after becoming amicrofilaremic and 3 of the 4 ferrets with multiple infections had no lesions of liver or lung at the time of the necropsy. As noted previously, 2 of these ferrets in each group devel-

op persistent edema of the injected legs and paws. Lymphatic vessels of both edematous and nonedematous ferrets, without liver or lung lesions, had extensive granulomatous reactions with segments of lymphatic occlusion; however, the two nonedematous ferrets also had obvious exudative and granulomatous reactions to mf and tissue eosinophilia not evident in the edematous animals. The single ferret given multiple infections that had lesions of liver and lung was not edematous and had numerous mf in the lymphatics but relatively little cellular reaction to them.

Discussion

This study confirms and extends the results of the previous investigation of experimental filariasis in the ferret (Crandall et al., 1982) by demonstrating that the cellular response to mf in the lung, liver and lymph nodes resembles that of occult filariasis in man. The study also indicates that ferrets have a potential use in the study of filarial lymphedema.

The conspicuous lesions in the liver of infected ferrets are similar to the liver lesions of occult filariasis described in man (Webb et al., 1960). These lesions in the ferret, abscesses of eosinophils surrounding a degenerating mf covered with Splendore-Hoeppli substance, are also identical to the lesions originally described by Meyers and Kouwenaar (1939) in the lymph node of an amicrofilaremic patient with hypereosinophilia. The structure formed by the microfilarial carcass and the Splendore-Hoeppli deposits has been called the Meyers-Kouwenaar (MK) body; these bodies within aggregates of eosinophils and granulomas are characteristic of occult filariasis (Joe, 1962).

Comparison of the histopathology of lung and lymph node in occult filariasis of man and ferrets reveals striking similarities. In tropical pulmonary eosinophilia, biopsy specimens contain degenerate mf in aggregates of eosinophils and MK bodies surrounded by histiocytes and within granulomas scattered throughout the lungs (Danaraj et al., 1966). These reactions to mf also develop in the lungs of ferrets; but the macroscopic abscesses in man (Udwadia and Joshi, 1964; Webb et al., 1950) were rare in ferrets. The interstitial inflammations in man including peribronchiolar infiltration of eosinophils in tropical pulmonary eosinophilia (Danaraj et al., 1966; Udwadia and Joshi, 1964) developed in ferrets but extensive, diffuse inflammatory reactions were limited to the period of initial clearance of mf from the circulation. In man the enlarged lymph nodes in tropical eosinophilia contain eosinophils in abscesses surrounding degenerate mf and MK bodies; the latter are also in epithelioid and giant cell granulomas (Webb et al., 1960; Hartz et al., 1948; Galliard, 1957). These responses to mf resemble those in lymph nodes of ferrets but massive infiltrates of eosinophils were not observed in ferrets.

The lymphangitis and lymphadenitis in ferrets resemble the granulomatous and exudative inflammatory responses of early filariasis of man (Wartman,

1944; von Lichtenberg, 1957) and certain experimental animals (Schacher and Sahyoun, 1956; Malone et al., 1976). These reactions are usually attributed to products from the larvae and from living and dead adult filariae within the lymphatics rather than the mf. In ferrets, the presence of mf in thrombolymphangitic lesions and exudative inflammatory responses indicates that mf can contribute to the lymphangitis of acute filariasis in conditions producing amicrofilaremic infections. Degenerating mf can provoke inflammation in the lymphatics (Meyers et al., 1976) and the immune responses to mf, characteristic of occult infections, could initiate such a reaction. In fact, the most extensive inflammatory reactions to mf in the lymphatics were in amicrofilaremic ferrets with few or no lesions in liver or lung. This observation suggests that intense inflammatory reactions in lymphatics and lymph nodes may trap mf and prevent their circulation. Thus lymphangitis and lymphadenitis become principal manifestations of occult infection.

The cause of persistent edema in the ferrets which received more than one injection of infective larvae is unknown. None of these ferrets had a secondary bacterial lymphangitis. Although there were some differences in the lymphangitis between nonedematous and edematous ferrets, the histologic comparison was too limited to reach any conclusions. A change in immune responses to filarial antigens and consequent alterations in tissue reactivity, which might lead to edema, have not been investigated.

Acknowledgments

This work was supported in part by grants from Merck, Sharp and Dohme Research Laboratories; NIH grant AI 19275 and the World Health Organization's Collaborating Centre for Histopathology of Filarial Infections in Man, at the Armed Forces Institute of Pathology. The technical assistance of Thomas J. Doyle, IV is gratefully acknowledged.

- Archibald J., Sumner-Smith G.: Abdomen. In: Canine surgery, ed. by J. Archibald, p. 505–554. American Veterinary Publications Inc., Santa Barbara, California 1974.
- Beaver P. C.: Filariasis without microfilaremia. *Amer. J. trop. Med. Hyg.* **19**, 181–189 (1970).
- Crandall R. B., McGreevy P. B., Connor D. H., Crandall C. A., Neilson J. T., McCall J. W.: The ferret (*Mustela putorius furo*) as an experimental host for *Brugia malayi* and *Brugia pahangi*. *Amer. J. trop. Med. Hyg.* **31**, 752–759 (1982).
- Danaraj T. J., Pacheco G., Shanmugaratnam K., Beaver P. C.: The etiology and pathology of eosinophilic lung (tropical eosinophilia). *Amer. J. Trop. Med. Hyg.* **15**, 183–189 (1966).
- Galliard H.: Outbreak of filariasis (*Wuchereria malayi*) among French and North African servicemen in North Vietnam. *Bull. Wld Hlth Org.* **16**, 601–608 (1957).
- Hartz P. H., van der Sar A.: Tropical eosinophilia in filariasis. Occurrence of radiating processes about microfilariae. *Amer. J. clin. Path.* **18**, 637–644 (1948).
- Joe K. L.: Occult filariasis: its relationship with tropical pulmonary eosinophilia. *Amer. J. trop. Med. Hyg.* **11**, 646–651 (1962).
- von Lichtenberg F.: The early phase of endemic bancroftian filariasis in the male. Pathological study. *J. Mt Sinai Hosp.* **24**, 983–1000 (1957).

- Malone J. B., Leininger J. R., Chapman W. L.: *Brugia pahangi*: histopathological study of golden hamsters. *Exp. Parasit.* 40, 62–73 (1976).
- Meyers F. M., Kouwenaar W.: Over hypereosinophilie en over een merwaardigen vorm van filariasis. *Geneesk. T. Ned.-Ind.* 79, 853–873 (1939).
- Meyers W. M., Neafie R. C., Conner D. H.: Brancroftian and Malayan filariasis. In: *Pathology of tropical and extraordinary diseases*, ed. by C. H. Binford, D. H. Conner, p. 340–355. Armed Forces Institute of Pathology, Washington, D. C. 1976.
- Neva F. A., Kaplan A. P., Pacheco G., Gray L., Danaraj T. J.: Tropical eosinophilia: a human model of parasitic immunopathology, with observations on IgE levels before and after treatment. *J. Allergy clin. Immunol.* 55, 422–429 (1975).
- Ottesen E. A., Neva F. A., Raranjape R. S., Tripathy S. P., Thiruvengadam K. V., Beaver M. A.: Specific allergic sensitization to filarial antigens in tropical eosinophilia syndrome. *Lancet* 1979/I, 1158–1161.
- Schacher J. F., Sahyoun P. F.: A chronological study of the histopathology of filarial disease in cats and dogs caused by *Brugia pahangi*. *Trans. roy. Soc. trop. Med. Hyg.* 61, 234–243 (1956).
- Udwadia F. E., Joshi V. V.: A study of tropical eosinophilia. *Thorax* 19, 548–555 (1964).
- Wartmann W. B.: Lesions of the lymphatic system in early filariasis. *Amer. J. trop. Med. Hyg.* 24, 299–313 (1944).
- Webb J. K. G., Job C. K., Gault E. W.: Tropical eosinophilia: demonstration of microfilariae in lung, liver and lymph nodes. *Lancet* 1960/I, 835–842.
- Weingarten R. J.: Tropical eosinophilia. *Lancet* 1943/I, 103–105.

