

Zeitschrift: Acta Tropica
Herausgeber: Schweizerisches Tropeninstitut (Basel)
Band: 36 (1979)
Heft: 1

Artikel: Effect of levamisol on tissues of "Ascaris lumbricoides"
Autor: El Boulaqi, H.A. / Dar, F.K. / Hamdy, E.I.
DOI: <https://doi.org/10.5169/seals-312510>

Nutzungsbedingungen

Die ETH-Bibliothek ist die Anbieterin der digitalisierten Zeitschriften auf E-Periodica. Sie besitzt keine Urheberrechte an den Zeitschriften und ist nicht verantwortlich für deren Inhalte. Die Rechte liegen in der Regel bei den Herausgebern beziehungsweise den externen Rechteinhabern. Das Veröffentlichen von Bildern in Print- und Online-Publikationen sowie auf Social Media-Kanälen oder Webseiten ist nur mit vorheriger Genehmigung der Rechteinhaber erlaubt. [Mehr erfahren](#)

Conditions d'utilisation

L'ETH Library est le fournisseur des revues numérisées. Elle ne détient aucun droit d'auteur sur les revues et n'est pas responsable de leur contenu. En règle générale, les droits sont détenus par les éditeurs ou les détenteurs de droits externes. La reproduction d'images dans des publications imprimées ou en ligne ainsi que sur des canaux de médias sociaux ou des sites web n'est autorisée qu'avec l'accord préalable des détenteurs des droits. [En savoir plus](#)

Terms of use

The ETH Library is the provider of the digitised journals. It does not own any copyrights to the journals and is not responsible for their content. The rights usually lie with the publishers or the external rights holders. Publishing images in print and online publications, as well as on social media channels or websites, is only permitted with the prior consent of the rights holders. [Find out more](#)

Download PDF: 04.07.2025

ETH-Bibliothek Zürich, E-Periodica, <https://www.e-periodica.ch>

¹ Faculty of Medicine, University of Garyounis, Benghazi, Libya

² Department of Parasitology, Faculty of Medicine, Cairo University

Effect of levamisol on tissues of *Ascaris lumbricoides*

H. A. EL BOULAQI¹, F. K. DAR¹, E. I. HAMDY², E. G. MIKHAIL²

Summary

Levamisol which is highly effective against *Ascaris* infections, was shown to produce degenerative changes in the intestine and the reproductive system of the worm. Worms that were not expelled by treatment produced only non-viable eggs which could not develop in vitro. Levamisol is thus shown to be not only a highly curative drug, but a compound of significant edpidemiological importance.

Key words: levamisol; *Ascaris*; histology.

Introduction

Tetramisol (2,3,5,6-tetrachloro-6-phenyl-imidazo (2,1-b) thiazol) is an effective antinematodal drug used in man and animal (Seftel and Heinz, 1968). The levoisomer of tetramisol (levamisol which is available commercially as Ketrax) is about twice as active as the racemic form and side-effects are again much fewer (Forsyth, 1968; Thienpont et al., 1969).

The drug appears to act by inhibiting the enzyme succinic dehydrogenase in the muscles of the worm resulting in complete paralysis (Van den Bossche and Janssen, 1967). As a result the parasite loses its hold on the intestinal mucosa and gets expelled by peristalsis.

The compound seems to be effective against a variety of gastrointestinal nematodes harboured by man and animals. All reports have indicated that the drug is safe and is of particular value in ascariasis. A single oral dose of 2.5 mg/kg with or without fasting or purging, gives a cure rate of 92% to 97% (Lionel et al., 1969). This high cure rate is clearly superior to that obtained by other ascari-cides presently used.

Correspondence: Prof. Dr. F. K. Dar, University of Garyounis, Faculty of Medicine, P.O. Box 1451, Benghazi, Libya

In our own preliminary studies, we obtained a cure rate of 97.5% using a dose rate of 2.5 mg/kg. There were 3 failures out of 120 trials. When cultures of eggs were done from the faeces of these non responding cases by the method of Hamdy (1968), it was noticed that the ova failed to develop in the cultures. This finding raised the question whether the drug had any effects on the different systems of the worms other than its paralysing effect.

The present work was thus designed to study any morphological changes in *Ascaris lumbricoides* due to levamisol treatment.

Materials and methods

Human cases of ascariasis were treated with Ketrax. A single oral dose of 2.5 mg/kg was given irrespective to meals and without purgatives. The stools were examined for expelled worms for a period of 7 days after treatment. The recovered worms were washed with saline and fixed in 10% formalin. Pieces of the worms were taken at different levels to be embedded in paraffin. Sections were cut 5 microns thick, stained with haematoxylin and eosin, and examined for any pathological changes. The findings were compared with sections prepared from untreated worms (controls) discharged spontaneously from heavily infected cases.

Results

1. Control worms

A transverse section of the worm showed an outer intact cuticle, followed by subcuticular matrix and then a well-defined muscle layer. The subcuticle showed 4 lines or thickenings that contained the dorsal and ventral nerve cords and 2 lateral excretory ducts. The intestine appeared as a flattened tube lined with a single layer of columnar cells of regular size with basal nuclei and no vacuoles (Fig. 1).

The female genital tract was circular in cross-section with villi-like structures projecting from the inner surface. Uteri appeared as big circles full of intact, mamillated, cellular, fertilized, and regularly distributed eggs (Figs. 3 and 4).

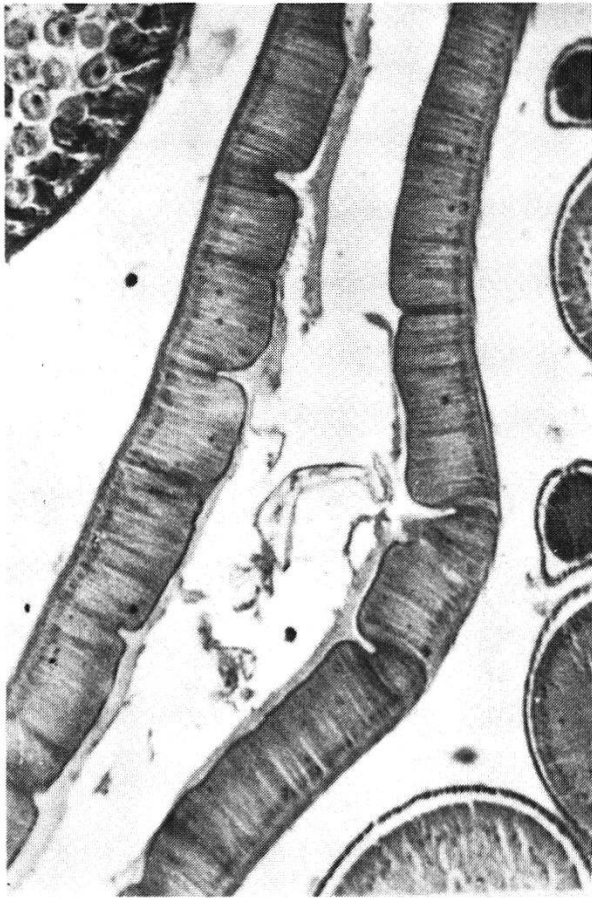
The male genital system was circular in cross-section. Spermatozoa were amoeboid, nucleated, numerous, and regular (Fig. 7).

Fig. 1. Section of the intestine of a normal worm. It is lined by columnar cells which are regular in size and shape with basal nuclei. $\times 90$.

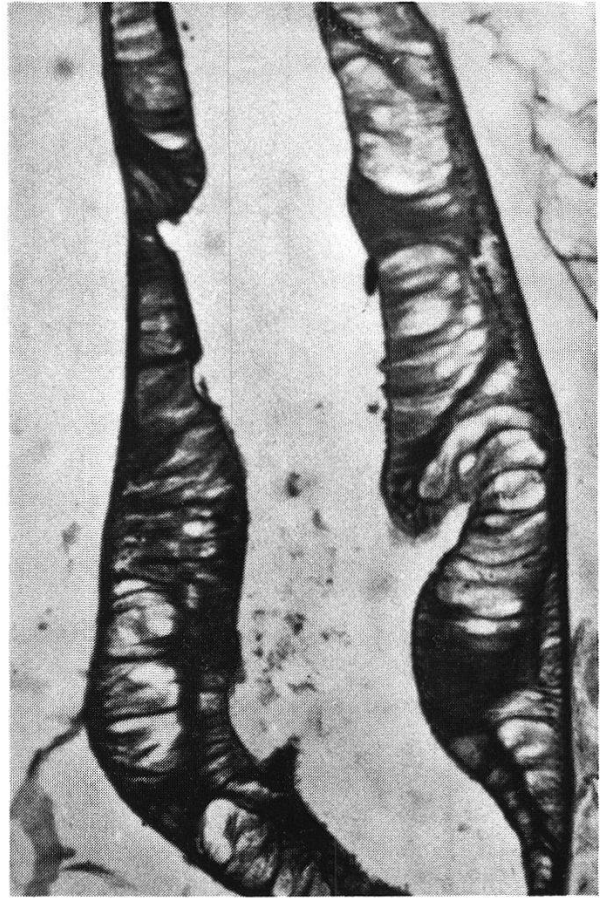
Fig. 2. Section of the intestine of a treated worm. The columnar cells become irregular in size and shape, vacuolated and with displaced nuclei. $\times 90$.

Fig. 3. Section of the genital system of a normal female. Uteri show villi-like projections internally while the ova are numerous and homogeneously distributed. $\times 52.2$.

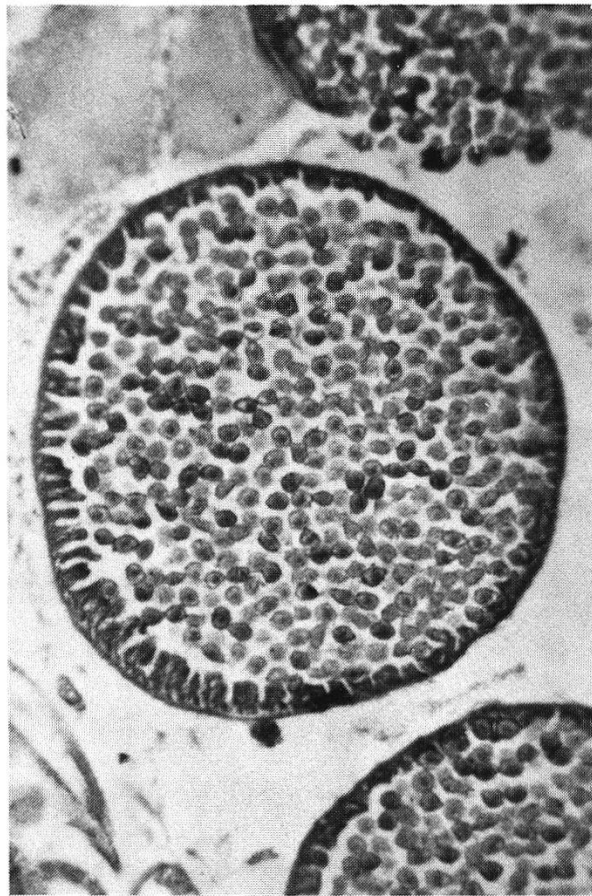
Fig. 4. Same as Fig. 3 but with higher magnification ($\times 300$). The ova are normal in appearance and fertilized.



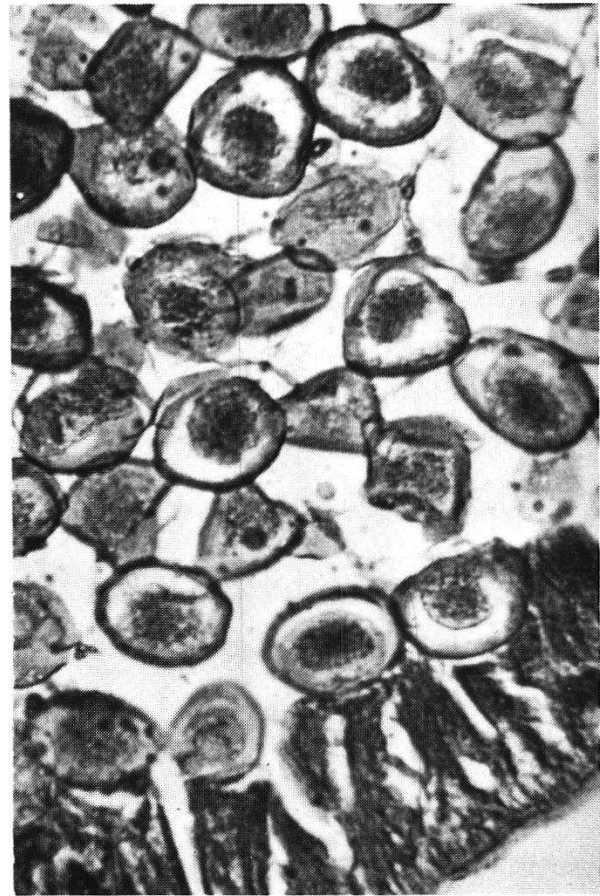
1



2



3



4

2. Treated worms

Section of the treated worms showed normal cuticle and subcuticle. The muscle fibres were thin and separated from each other. Nerve cords and excretory ducts were atrophied.

The columnar cells of the intestine were affected. They appeared irregular in size and shape, vacuolated, degenerated, and with displaced nuclei (Fig. 2). The walls of the uteri were thin with atrophied villi. The uteri contained eggs and degenerated structureless acidophilic homogeneous masses. The degenerate vacuolated eggs were few in number, irregular in outline with very poorly developed shells, and without the mamillated coats (Figs. 5 and 6).

The male reproductive system also showed extensive damage with abnormal spermatozoa (Fig. 8).

Discussion

It is known that levamisol induces paralysis of *Ascaris* by selective inhibition of succinic dehydrogenase in its muscle. This blocks the reduction of fumarate to succinate which is an important step in the anaerobic metabolism of nematode muscle (Van den Bossche and Janssen, 1967).

The present results clearly show that the drug not only interferes with the carbohydrate metabolism in the muscles, but also in the different systems as indicated by the pathological changes described above.

The degenerative changes in the intestine of the worm interfere with digestion and absorption leading to starvation. The drug was also shown to damage the nerves and this probably augments its paralysing effect on the muscle. Both these factors explain the rapid elimination of the worms after therapy, since most of them are expelled in the first 24 h after drug administration (Lionel et al., 1969).

We are satisfied that the histological changes seen after treatment were due to drug action and not to post-mortem changes per se. Sections of untreated dead worms did not show the specific lesions seen in the drug treated ones.

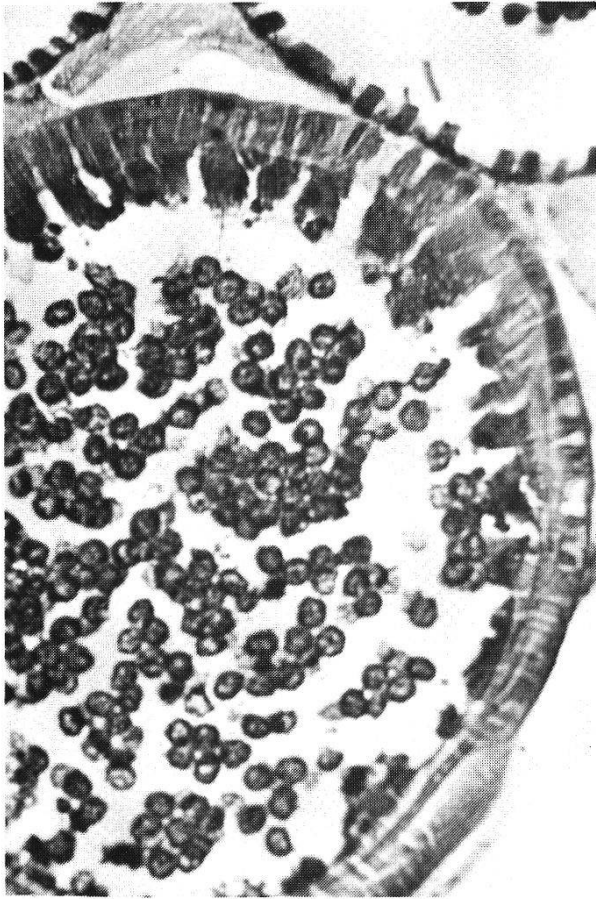
Levamisol is the most effective ascaricide presently in use. The cure rate is as high as 97% (Vakil et al., 1970). Furthermore, the drug is of epidemiological

Fig. 5. Section of the genital system of a treated female worm. Uteri show thin walls and atrophied villi. They contain fewer eggs which are degenerated structureless acidophilic homogenous masses. $\times 52.2$.

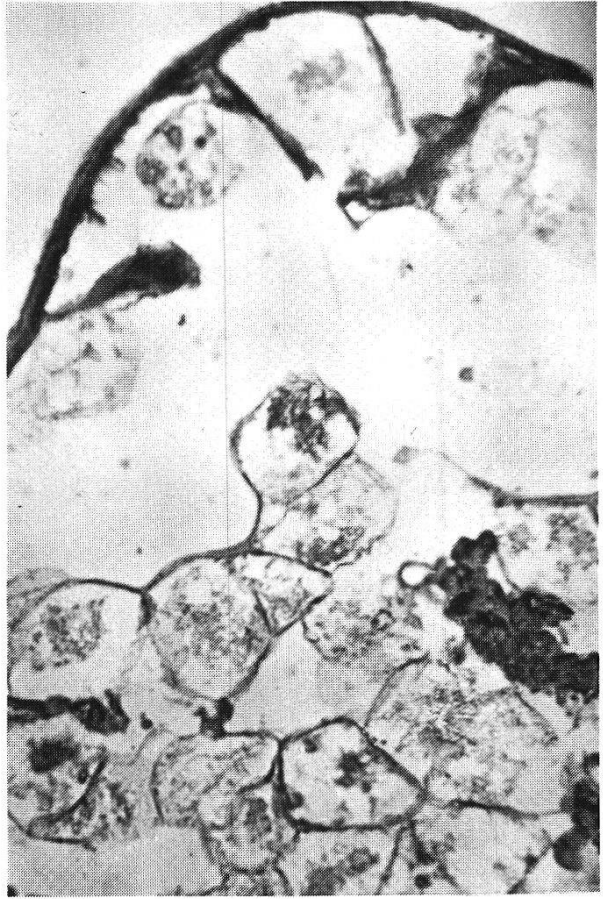
Fig. 6. Same as Fig. 5 but with higher magnification ($\times 300$). The ova are irregular in outlines, with very poorly developed shells, absent mamillated coats and disrupted unfertilized contents.

Fig. 7. Section of the genital system of a normal male. Spermatozoa are numerous, amoeboid and nucleated. $\times 300$.

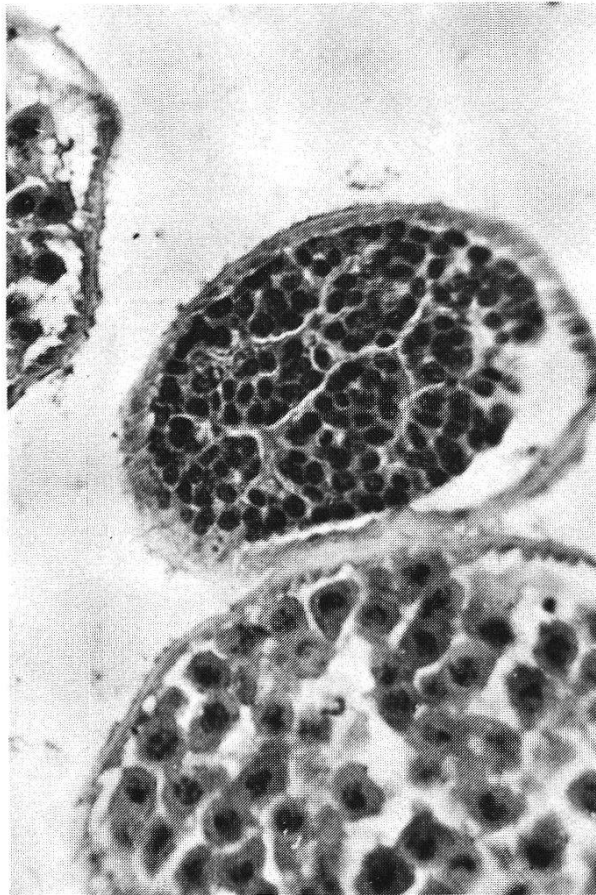
Fig. 8. Section of the genital system of a treated male. Spermatozoa are fewer in number and degenerated. $\times 300$.



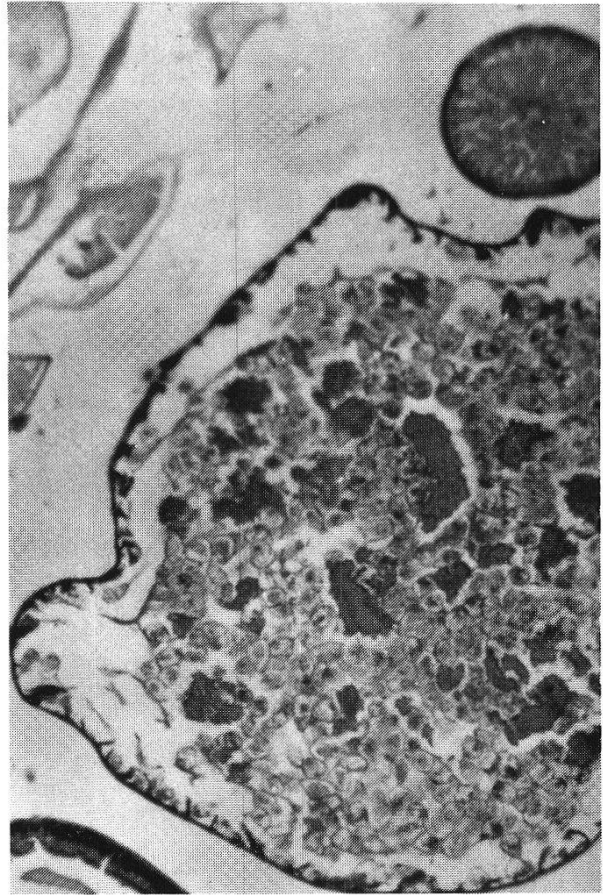
5



6



7



8

significance in that even in the small proportion of non-responding cases, its use affects the fertility in both the male and the female worms. The present study clearly shows that the degenerative changes in the reproductive systems of the worms lead to the production of non-viable eggs. Such eggs were shown to be incapable of development in vitro. It is thus evident that the wide-spread use of drugs like levamisole may help in effectively breaking the transmission cycle of the parasite in the endemic areas.

- 1 Forsyth B. A.: The anthelmintic activity of the optical isomers of tetramisole in sheep and cattle. *Aust. vet. J.* 44, 395–400 (1968).
- 2 Hamdy E. I.: Extra-corporeal hatching of *Ascaris* eggs. *Med. J. Cairo Univ.* 36, 273–278 (1968).
- 3 Lionel N. D. W., Mirando E. H., Nanayakkara J. C., Soysa P. E.: Levamisole in the treatment of ascariasis in children. *Brit. med. J.* 1969/IV, 340–341.
- 4 Seftel H. C., Heinz H. J.: Comparison between piperazine and tetramisole in treatment of ascariasis. *Brit. med. J.* 1968/IV, 93.
- 5 Thienpont D., Brugmans J., Abadi K., Tanamal S.: Tetramisole in the treatment of nematode infections in man. *Amer. J. trop. Med. Hyg.* 18, 520–525 (1969).
- 6 Vakil B. J., Dalal N. J., Sapre M. M., Kulkarni H. J.: Clinical trials with a new anthelmintic, tetramisole. *Trans. roy. Soc. trop. Med. Hyg.* 64, 717–722 (1970).
- 7 Van den Bossche H., Janssen P. A. J.: The biochemical mechanism of action of the anthelmintic drug tetramisole. *Life Sci.* 6, 1781–1792 (1967).