

**Zeitschrift:** Acta Tropica  
**Herausgeber:** Schweizerisches Tropeninstitut (Basel)  
**Band:** 19 (1962)  
**Heft:** 3

**Artikel:** Miscellanea : Increased number of mast cells and helminthic diseases in man : clinical observations  
**Autor:** Fernex, M. / Bèzes, H.  
**DOI:** <https://doi.org/10.5169/seals-311029>

### **Nutzungsbedingungen**

Die ETH-Bibliothek ist die Anbieterin der digitalisierten Zeitschriften auf E-Periodica. Sie besitzt keine Urheberrechte an den Zeitschriften und ist nicht verantwortlich für deren Inhalte. Die Rechte liegen in der Regel bei den Herausgebern beziehungsweise den externen Rechteinhabern. Das Veröffentlichen von Bildern in Print- und Online-Publikationen sowie auf Social Media-Kanälen oder Webseiten ist nur mit vorheriger Genehmigung der Rechteinhaber erlaubt. [Mehr erfahren](#)

### **Conditions d'utilisation**

L'ETH Library est le fournisseur des revues numérisées. Elle ne détient aucun droit d'auteur sur les revues et n'est pas responsable de leur contenu. En règle générale, les droits sont détenus par les éditeurs ou les détenteurs de droits externes. La reproduction d'images dans des publications imprimées ou en ligne ainsi que sur des canaux de médias sociaux ou des sites web n'est autorisée qu'avec l'accord préalable des détenteurs des droits. [En savoir plus](#)

### **Terms of use**

The ETH Library is the provider of the digitised journals. It does not own any copyrights to the journals and is not responsible for their content. The rights usually lie with the publishers or the external rights holders. Publishing images in print and online publications, as well as on social media channels or websites, is only permitted with the prior consent of the rights holders. [Find out more](#)

**Download PDF:** 09.07.2025

**ETH-Bibliothek Zürich, E-Periodica, <https://www.e-periodica.ch>**

# Increased Number of Mast Cells and Helminthic Diseases in Man. Clinical Observations.\*

By M. FERNEX and H. BÈZES,

Swiss Tropical Institute, Basle, and University of Dakar, Senegal

Experimental helminthic diseases produce a tissue mastocytosis in rats (13) as well as in mice (1); and the observed blood eosinophilia can be considered as a reflection of increased histamine production by hyperactive mast cells (2).

Helminths, cestodes and nematodes such as ascaris, trichiuris, strongyloides, ancylostoma are extremely common in Dakar, and can even be found simultaneously in a single patient. This might explain the relative mastocytosis of an African series compared to an European series, and also the relative eosinophilia observed in Dakar (2).

In man, filariasis and bilharziasis are diseases often accompanied by a very high eosinophilia. It might be expected that in those two diseases the mast cells are much stimulated so that their activity and their number is greatly increased.

To test this hypothesis, biopsies were collected from macroscopically normal skin in patients with long-standing filariasis infestation: *Loa loa*, *Wuchereria bancrofti*, and *Onchocerca volvulus*. The biopsies were fixed in formalin 10%, embedded in paraffin, cut at 7 microns, and stained with toluidine blue. Mast cells were counted in 40 microscopic fields of 0.25 mm<sup>2</sup>, and their number expressed as cells per square millimeter of dermis. The results tabulated in Table I will be compared to values obtained in a previous series of Europeans and Africans from Dakar, where no filariasis occurs.

*Result:* The number of mast cells in the normal skin of individuals infested with filariasis is three times higher than the average number of mast cells in the skin of not infected individuals.

Some particular cases might be of interest and will be presented.

## *Case I. Filariasis Loa loa and Dipetalonema perstans.*

At the end of 1961, a white male, 33 years old, after a light gastrointestinal intoxication, suffered from generalized giant edema, lasting some days.

Four months later, the patient was quite well, and a skin biopsy was performed on the chest. The number of mast cells was found to be twice the normal value, i.e. 57 per square millimeter.

The past history is of interest: no familial history of allergic diseases, asthma, or eczema. The patient spent 1954 to 1955 in the Congo, near Brazzaville, where he suffered from several malaria attacks and Calabar edema.

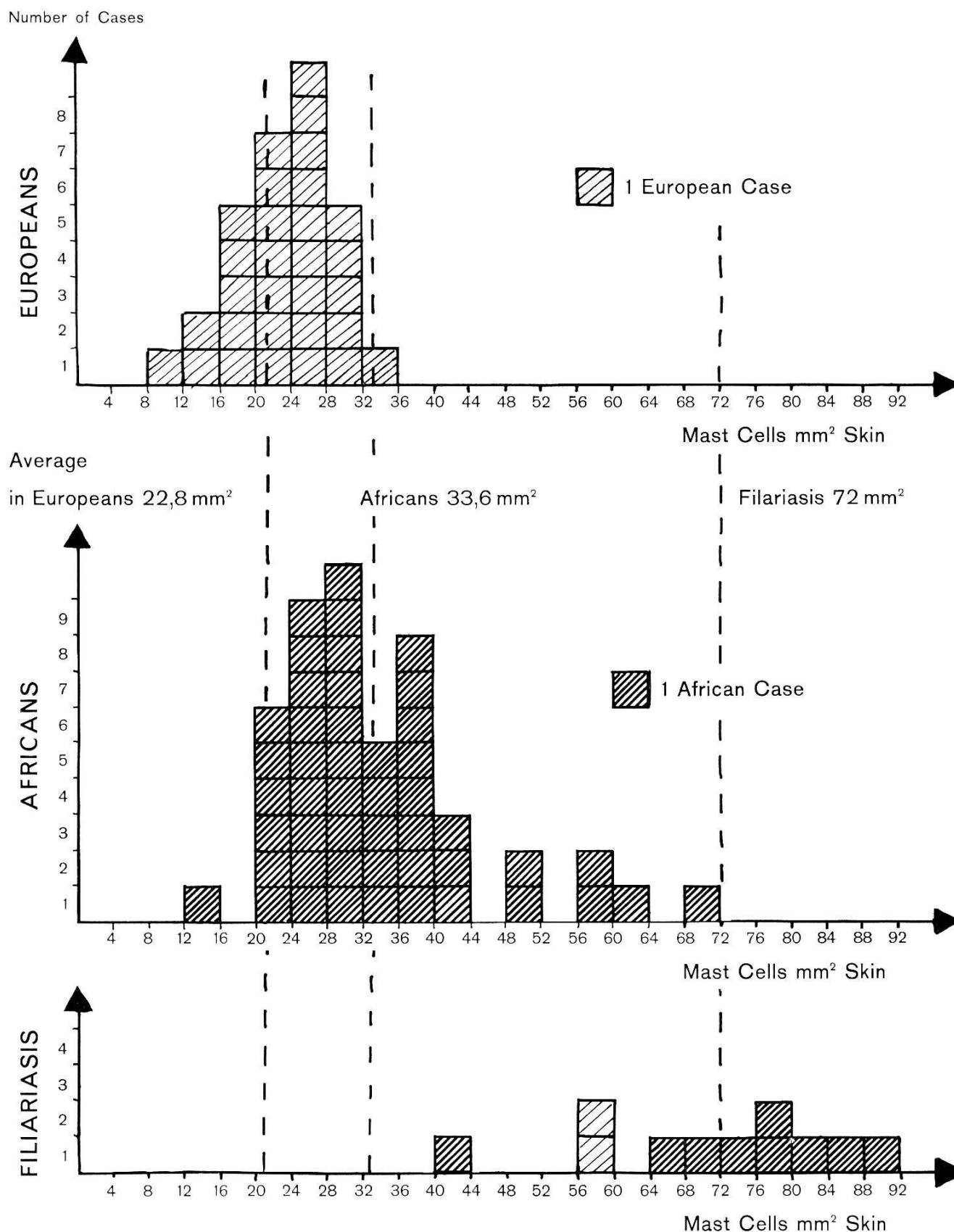
In 1955, he permanently returned to Europe. The blood eosinophilia varied from 65 to 75%, with a leukocytosis of 12,000 per mm<sup>3</sup>. A high infestation with microfilariae of *Loa loa* and *Perstans* was observed. The patient was sent to rest in the mountains for two months, treated with 0.4 g Hetrazan daily for 2 10-day courses. The clinical signs of filariasis as well as the microfilaremia and the eosinophilia disappeared.

Since then, he has been healthy, except the above-mentioned episode of edema.

---

\* Financial assistance for these investigations was kindly provided by a grant from the Swiss National Foundation for Scientific Research.

TABLE I  
Comparison of mast cell number in dermis of Europeans, Africans,  
and patients suffering from filariasis



Number of mast cells per square millimeter dermis compared in 3 groups: 1. Europeans without filariasis average 22.8 MC/mm<sup>2</sup>. 2. Africans without filariasis average 33.6 MC/mm<sup>2</sup>. 3. Africans and Europeans infected with filariasis average 72 MC/mm<sup>2</sup>.

*Discussion:* Seven years after a massive infection with *Loa loa* and *Perstans*, a high number of mast cells remained in the normal skin. This mastocytosis may be the explanation for the abnormal generalized edema, occurring after a slight intoxication, as it has been observed in cases of urticaria pigmentosa, an idiopathic mastocytosis (5, 8, 3).

*Case II. Tropical eosinophilia and hyperactive mastocytosis.*

On the 9. 10. 1959 a 17-year-old African female entered the Medical Clinic of Professor M. PAYET in Dakar, suffering from dyspnea, orthopnea, chest pain, precordialgias, generalized arthralgias and cough with nocturnal paroxysms of many days duration.

*Clinical examination:* Very anxious, dyspneic, cyanotic, well nourished woman, with expiratory dyspnea, tachypnea 64 per minute, pulse 124 per minute, blood pressure 120/80 mm Hg, temperature 37.8. The cardiovascular system was normal except tachycardia. Signs of diffuse bronchitis of asthmatic type. X ray examination: normal heart shape, excessive striations on both lungs, symmetrically from the hili. Abdomen: somewhat sensitive, liver of normal size, spleen just palpable. Except for huge inguinal lymph adenopathies on both sides, the findings were further negative.

*Laboratory data:* Erythrocytes: 4.5 millions, 14.5 g Hb, sedimentation rate 62/90 mm, leukocytes 60,000/mm<sup>3</sup> with 63% eosinophils, 21% neutrophils, 0% basophils, 15% lymphocytes, 1% monocytes, blood platelets 26,000/mm<sup>3</sup>, bleeding time 2'20, clotting time 3'5, normal retractability of the clot. Prothrombin time 60%. Bone marrow normal except for a huge proliferation of eosinophils: 48% of the nucleated cells are eosinophils: 12.5% eosinophils myelocytes, 6% eosinophils metamyelocytes, 29.5% eosinophils polynuclears.

*Skin biopsy:* The mast cell number was 73.6 mast cells per mm<sup>2</sup>. Their morphology was very peculiar: the granules were often scarce, small, irregular. The nucleus, otherwise hidden by the granules, was easily seen. Some of these mast cells looked like the "ghost cells" obtained by RILEY after stimulation with 48/80 compound.

*Evolution and treatment:* Theophylline and Prednisone 40 mg daily did not influence the asthmatic bronchitis, neither the thoracic pain and arthralgias.

On the 13. 11. 1959 an antihelminthic drug was given: 0.4 g Hetrazan daily during 10 days. At the end of the treatment fever, dyspnea, pain disappeared. The sedimentation rate remained high. The white count became normal: 8,000 per mm<sup>3</sup>, with only 22% eosinophils.

*Discussion:* This is a typical case of tropical eosinophilia, a Weingarten syndrome, where the exact helminthic etiology could not be determined; there exists a skin mastocytosis attaining the same values as in filarian infections. The morphology of these cells speaks for a very active secretory stage, explaining the striking eosinophilia.

*Case III: Onchocerca volvulus infection and mastocytosis.*

On the 25. 5. 1962 a 48-year-old white male entered the Swiss Tropical Institute, suffering from pruritus and dermatitis.

The patient had spent nearly 20 years in the Cameroons as a missionary. He has never been seriously ill, but has suffered since 1952 from generalized pruritus. Onchocerciasis was diagnosed at this time. The white cell count was over 10,000/mm<sup>3</sup>, with 70-80% eosinophils; and the patient was treated with Hetrazan.

In 1958 the patient returned permanently to Europe, and once more was treated with Hetrazan, which was badly tolerated: fever, diffuse pain, increase in the pruritus, and generalized giant urticarial reactions.

*Clinical observation in May 1962:* No pathological findings, except a diffuse skin atrophy, with parakeratosis, loss of hair, marks of scratchings and elephantiasic edema of distal part of the left leg, where a deep subcutaneous nodule was palpable. Microfilaria of *Onchocerca volvulus* were found in the skin smear after scarification. Leukocyte count was 6,900/mm<sup>3</sup>, with 22% eosinophils. No blood parasites. The nodule, 2 × 3 cm diameter, was excised and found full of eggs and larva of *Onchocerca volvulus*.

A skin biopsy was performed. This is the only case in this paper where abnormal-appearing skin is examined for mast cells, as the whole skin altered. The mast cell number is 56 per square millimeter of dermis.

*Discussion:* *Onchocerca volvulus* infection may be the cause of dermatitis with important skin mastocytosis. This mastocytosis may play a determining role in the genesis of the subcutaneous nodules as it plays a role in the genesis of the elephantiasis.

#### *Case IV: Schistosoma mansoni infection with high mastocytosis.*

On the 13.11.1959 a 16-year-old African female, of Bambara tribe, was brought in comatose stage to the clinic of Professor M. PAYET in Dakar. The patient had been ill for 8 days with fever, headache, vomiting, and lately light mental disorders and aphasia.

*Clinical investigations:* Young, well developed and well nourished female. Temperature 39.8, pulse rate 120/minute, tachypnea 42/minute, blood pressure 90/40 mm Hg. Further examination is negative: no palpable splenomegaly, no signs of meningitis.

*Laboratory data:* The blood smear showed a very high number of trophozoites of *Plasmodium falciparum*. Blood culture negative, blood sugar 100 mg%, urea 45 mg%, spinal fluid: 3 lymphocytes per mm<sup>3</sup>, albumin 15 mg%, glucose 80 mg%, chloride 720 mg%.

*Clinical course.* The patient immediately received 1 g quinoform, cortisone and desoxycorticosterone intramuscularly, then an infusion with isotonic saline and glucose solution with magnesium sulfate. She died soon after in a sudden onset of pulmonary edema.

*Necropsy findings:* Heart of normal shape, with edematous myocardium. Heavy lung with diffuse and massive edema and stasis. Liver congested, grayish coloured and somewhat increased in consistency. Spleen enlarged and distended: 300 g. Brain was markedly edematous.

*Histology:* Encephalitis due to *Plasmodium falciparum*, with parasites in capillaries of the brain and marked pigmentation of the meninges. Spleen and liver with hypertrophy of histiocytic cells and pigment phagocytosis. *Myocardium:* interstitial edema with very numerous mast cells, 17/mm<sup>2</sup>, by far the highest values observed by us. In the skin, 69/mm<sup>2</sup>, also the highest value observed in people without filarial infection in normal skin. A miliary pneumonia with eggs of *Schistosoma mansoni* and a granulomatous hepatitis with eggs of *S. mansoni* in the centre of polymorphous granuloma, containing giant cells, macrophages, lymphocytes, plasmocytes and mast cells are observed (see fig. 1).

*Discussion:* The *S. mansoni* infection producing a miliary pneumonia and granulomatous hepatitis can be considered as an etiological factor for the observed mastocytosis: serous myocarditis with an extraordinary high level of



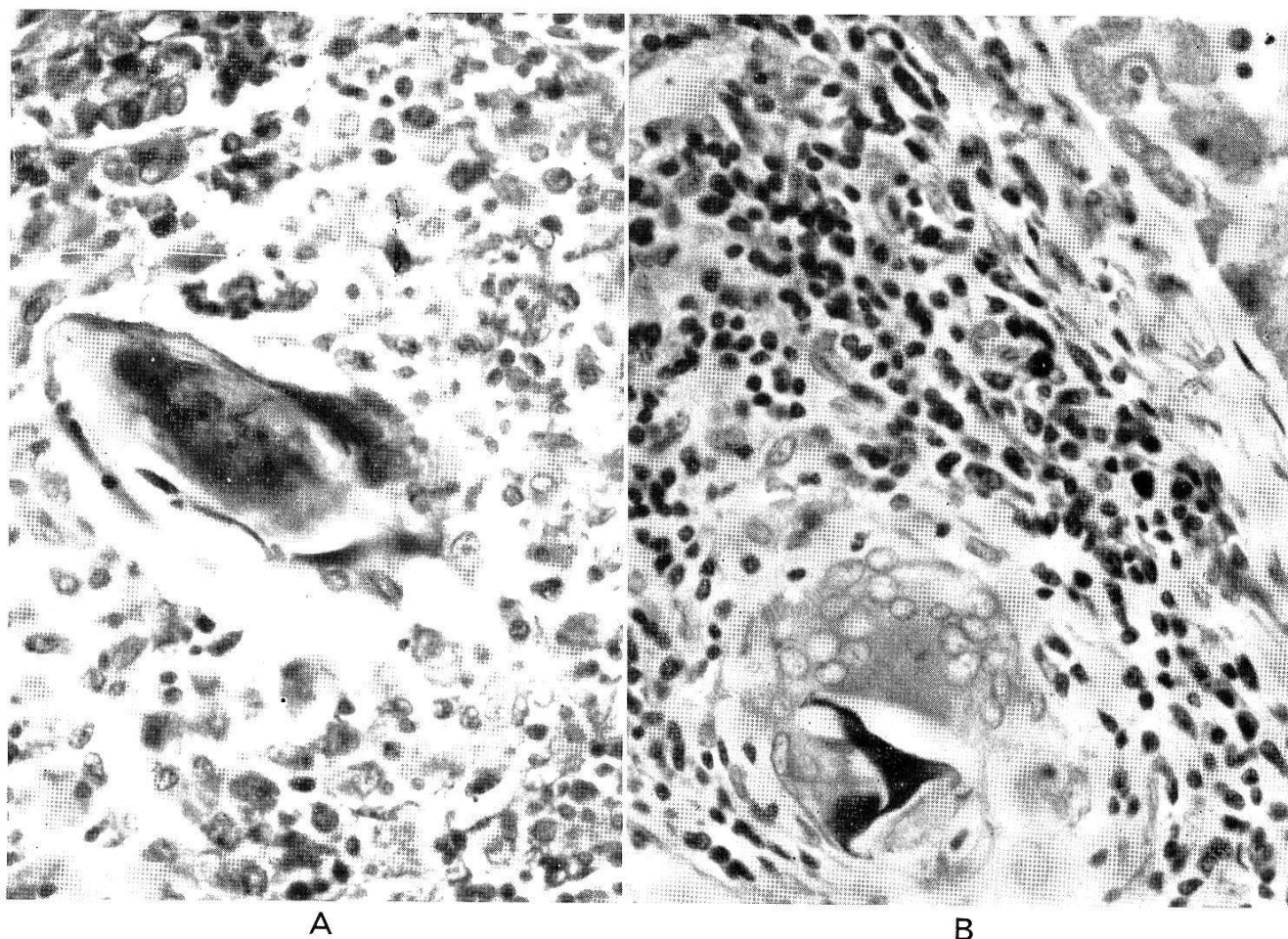


Fig. 1. Case 4: Infection with *Schistosoma mansoni*, coloured with toluidine blue, magnification 400 $\times$ . A. Pneumonia, with egg of *Schistosoma mansoni*, containing a living miracidium in the granulomatous tissue. B. Granuloma in the liver with giant cells around dead egg of *Schistosoma mansoni*.

mast cells, about 8 times the average in Europeans and 5 times the average in Africans. The mastocytosis of the skin approaches that observed in connection with filariasis.

#### *Schistosomiasis and mast cells.*

In our series of 82 autopsies performed in Dakar in 1959, 6 cases presented a *Schistosoma* infection. In those individuals, the average number of mast cells in the myocardium was 8.7/mm<sup>2</sup>, nearly twice the normal values found in Africans which is of 4.9/mm<sup>2</sup>, the average values in Europeans being 1.77 mm<sup>2</sup>. In the skin, the average was 41.6 mast cells per square millimeter of dermis, value somewhat higher than the normal values in Africans: 33/mm<sup>2</sup>, the average being 22.8/mm<sup>2</sup> in Europeans.

#### *Conclusion.*

A strong reactive hyperplasia of the mast cell system is observed in relation with filariasis and bilharziasis and tropical eosinophilia in Africans as well as in Europeans.

In Europe, a mastocytosis is not frequently observed, and may be related to some rare diseases such as urticaria pigmentosa (3, 8), beginning scleroderma (12), Zollinger-Ellinson syndrome (4, 14) or carcinoid syndrome (7, 10)

and hemopathies such as macroglobulinaemia Waldenström (6, 11), aplastic anemias, and perhaps osteomyelosclerosis (9, 4bis).

In tropical regions helminthic diseases may be considered as the most frequent etiological factor for mastocytosis.

### References.

1. FERNEX, M. (1962). Increased number of mast cells and helminthic diseases. Experimental mastocytosis in mice. — *Acta trop.* 19, 249.
  2. FERNEX, M. (1962). Mastocytose et éosinophilie. Contribution à l'étude physiopathologique des hyperéosinophilies. — *Bull. Soc. Path. exot.* (séance du 8 mai, à paraître).
  3. FERNEX, M. (1962). L'urticaire pigmentaire généralisée de l'adulte: une mastocytose. Les syndromes liés à l'hyperhéparinémie et à l'hyperhistaminémie. — *Schweiz. med. Wschr.* 92, 608.
  4. FERNEX, M. (1960). Contribution à l'étude physio-pathologique des mastocytes dans le myocarde. — *Actual. Cardio. angéiol. int.* 9, 269.
  - 4<sup>bis</sup> FRESÉN, O. (1961). On osteomyelosclerosis. — *Acta path. Jap.* 11, 87.
  5. ILIC, S. & STEVANOVIC, D. (1957). Urticaria gigantea in mastocytosis of type 'urticaria pigmentosa'. — *Minerva dermatol.* 34, 257.
  6. KAPPELER, R.; KREBS, A. & RIVA, G. (1958). Klinik der Makroglobulinaemie Waldenström. Beschreibung von 21 Fällen und Übersicht über die Literatur. — *Helv. med. Acta* 25, 101.
  7. McDONALD, R. A. & ROBBINS, S. I. (1957). Pathology of the heart in the carcinoid syndrome. A comparative study. — *Arch. Path. Anat.* 63, 103.
  8. REMY, D. (1962). Die Gewebsmastzellen und Mastzellen-Reticulose. — *Ergebn. inn. Med. Kinderheilk.* 17, 132-189.
  9. SCHORR, S., SAGHER, F. & LIBAN, E. (1956). Generalized osteosclerosis in urticaria pigmentosa. The radiologic aspect. — *Acta radiol.* 46, 575-586.
  10. STEINER, K. (1961). Cutaneous mast-cells in carcinoid. — *Arch. Derm. Syph.* 84, 477-481.
  11. TISCHERDORF, W. A. & HARTMANN, F. (1950). Makroglobulinaemie (Waldenström) mit gleichzeitiger Hyperplasie der Gewebsmastzellen. — *Acta haemat. (Basel)* 4, 374.
  12. WEGELIUS, H. F. & WAHLBERG, P. (1957). Early cardiac connective tissue change in scleroderma. — *Acta med. scand.* 156, 487.
  13. WELLS, P. D. (1962). Mast cell, eosinophil and histamine levels in *Nippostrongylus brasiliensis* infected rats. — *Exp. Parasit.* 12, 82.
  14. ZOLLINGER, R. M. & ELLISON, E. H. (1955). Primary peptic ulceration of the jejunum associated with islet cells tumor of pancreas. — *Ann. Surg.* 142.
-