

Zeitschrift: Acta Tropica
Herausgeber: Schweizerisches Tropeninstitut (Basel)
Band: 14 (1957)
Heft: 3

Artikel: Further Studies on Trypanosoma rangeli Tejera 1920
Autor: Herbig-Sandreuter, A.
DOI: <https://doi.org/10.5169/seals-310679>

Nutzungsbedingungen

Die ETH-Bibliothek ist die Anbieterin der digitalisierten Zeitschriften auf E-Periodica. Sie besitzt keine Urheberrechte an den Zeitschriften und ist nicht verantwortlich für deren Inhalte. Die Rechte liegen in der Regel bei den Herausgebern beziehungsweise den externen Rechteinhabern. Das Veröffentlichen von Bildern in Print- und Online-Publikationen sowie auf Social Media-Kanälen oder Webseiten ist nur mit vorheriger Genehmigung der Rechteinhaber erlaubt. [Mehr erfahren](#)

Conditions d'utilisation

L'ETH Library est le fournisseur des revues numérisées. Elle ne détient aucun droit d'auteur sur les revues et n'est pas responsable de leur contenu. En règle générale, les droits sont détenus par les éditeurs ou les détenteurs de droits externes. La reproduction d'images dans des publications imprimées ou en ligne ainsi que sur des canaux de médias sociaux ou des sites web n'est autorisée qu'avec l'accord préalable des détenteurs des droits. [En savoir plus](#)

Terms of use

The ETH Library is the provider of the digitised journals. It does not own any copyrights to the journals and is not responsible for their content. The rights usually lie with the publishers or the external rights holders. Publishing images in print and online publications, as well as on social media channels or websites, is only permitted with the prior consent of the rights holders. [Find out more](#)

Download PDF: 08.07.2025

ETH-Bibliothek Zürich, E-Periodica, <https://www.e-periodica.ch>

Further Studies on *Trypanosoma rangeli* Tejera 1920.¹

By A. HERBIG-SANDREUTER.

In Vol. 12, Nr. 3 (1955) of this journal we gave a preliminary account of our experimental studies on the life cycle of *T. rangeli* Tejera 1920, completed in September 1953. Since then efficient work has been done especially on the cycle of *T. rangeli* in the invertebrate host as well as on its transmission from the reduviid to the vertebrate (GROOT, H. 1952, GREWAL, SINGH M. 1957, PIFANO, C. F. 1954, ZELEDÓN, R. 1956).

From the cycle in the homoiothermal host, on the other hand, only the blood form (PIFANO, F. and coll. 1948) and its division form (GREWAL, SINGH M. 1956, HOARE, C. A. 1953, REICHENOW 1957), as well as the course of parasitemia in various laboratory animals (PIFANO, C. F. 1954) are known. Histological studies have so far not been published.

The present paper therefore concentrates on the histological analysis of *T. rangeli* in the homoiothermal host. It may contribute to the question of the existence of tissue forms of *T. rangeli*, as well as to the problem of its pathogenicity to vertebrates and man.

The second part of this paper gives a comparison of the main diagnostic characteristics of *T. rangeli* and *T. cruzi* regarding the developmental stages of the reduviid gut, culture medium, and vertebrate blood.

I. Experimental Studies on *T. rangeli* in the Homoiothermal Host.

Material and technique.

The trypanosomes were put at my disposal through the kindness of the Swiss Tropical Institute in Basle. The strain of *T. rangeli* had been generously given to this Institute by Dr. F. PIFANO, Caracas, who had isolated it in 1949 from the blood of an infected dog and successfully cultivated on NNN medium (modified after PIFANO) and in RHAZGHA REICHENOW cultures. At the beginning of these investigations (October 1952) the strain was still fully infectious for white mice as well as for *Rhodnius prolixus*. During the following 12 months, however, a reduction of the virulence was observed

¹ Our investigations were made possible through the International Alice Hamilton fellowship of the I.F.U.W. The experimental part was accomplished at the School of Tropical Medicine in San Juan, Puerto Rico.

for the vertebrate host (mouse), while this was not the case with reduviids.

For the culture of *T. rangeli* we used the RHAZGHA-REICHENOW medium exclusively (cf. GEIGY, R. & HERBIG, A., 1955, p. 411), as this medium produces a maximum of metacyclic forms and has the longest intervals between the inoculations (2-4 months at 24° C, not more than 2 months at temperatures of 26 to 30° C). As no thermostat was available for the cultures at 24° C, these were exposed to the temperature variations of the climate of San Juan, i.e. a range between 25 to 30° C.

For the experiments on the *vertebrate host* 230 newly born white mice were used as well as two 1½-year-old *Macacus rhesus* monkeys (male and female). All these animals came from the breeding station of the Escuela de Medicina Tropical (San Juan), University of Puerto Rico. For xenodiagnosis we bred *Rhodnius prolixus* originating from the Swiss Tropical Institute.

Parasitemia in mice and monkeys was examined by fresh blood preparations, thin and thick blood smears, xenodiagnosis and hemoculture. For direct blood control the blood of mice was taken from the tail-tip, for inoculation of hemocultures it was punctured from the heart. For daily examination of the monkey blood, a few drops were taken from the toes, for greater quantities we punctured the leg-vein. One larva III and two nymphs I or II were used with young mice, three larvae III and three nymphs I or II with monkeys for each xenodiagnosis.

Blood cultures were made by inoculating two culture media with 0.5 c.c. blood of mice each, or with 2 c.c. blood of monkeys for each hemoculture. Thin and thick smears we stained with buffered Giemsa-solution (pH 7.5).

For the histological examination of serial sections, 1-4 days old mice as well as single organs of older mice and monkeys were fixed in Bouin. In order to facilitate the penetration of the solution, tail and legs had been amputated previously. The serial sections were stained with Haemalaun Delafield and Haematoxylin Heidenhain/Eosin-orange.

In addition to sections, preparations were made by smearing and crushing organs onto slides. Half of each organ, or a whole of those in pairs, was kept for this purpose. Organ smears and crushes were treated like blood smears, fixed with alcohol methylium and stained with buffered Giemsa-solution (pH 6.5) ².

Inoculations of mice and monkeys were made with cultures yielding a maximum of metacyclic forms. The time of maximum

² For the fixing and staining technique of sections and smears cf. GEIGY, R., and HERBIG, A., 1955.

TABLE 1.

Examples of the various developmental stages of a culture passage of *T. rangeli* in RHAZGHA medium (temperature 26-28°C).

Days after inoculation of culture medium	<i>Round form</i>		<i>Leptomonas Crithidia</i>			<i>Long Crithidia</i>				<i>Trypanos. form</i>	
	without flagellum	with flagellum	without flagellum	short flagellum	long	short	trans.	long	trans.	short	long
4			12 4	6	60 8	8		2			
8				0.8	15	39 4		31 1	0.2		9
12					11	29 2.5		49 2	0.5		6
16					0.2	20	0.2	22 2	0.6	4	18
20					5	10 1	1	24 6	10	13	31
24					0.5	6 2	2	34 4	3	15	34
30					2	22	8	22 4		26	16
50						30	5	1.5	0.5	48	15
4		2	1 2	7	65 8	10		5			
8				0.8	15	42 4	0.2	31	1		9
12				0.2	9	39 0.4	0.1	50 1.2	1	2	16
16					2	27 1	0.2	48	2	0.8	19
20					1	19 1	1	20 1	7	5	45
24				0.2	1	38 2	0.5	24 0.3	4	13	27
30					0.5	27 2.5	2	40 0.5	1	20	16
50						32 2	4	14	8	25	17
4			2	17	53 6	16 2		4			
8			1	12	30 1	26 1		32 2			
12				0.2	14	35 3	0.1	20 2			
16			0.5		8	37 1	0.2	50 2	0.1	1	0.2
20					5	34 0.5	0.5		0.2	8	4
24					2	50	1	30 10	0.1	10	
30					2	30	0.5	2.5		65	
50					0.2	29	0.5	2.6		68	
4	1		8 2	11	72 2	9		3		2	1
8				0.8	22 2	38 2		28 2	0.2	2	
12			0.2		17 1	40 2		35 4	0.2		0.6
16				0.2	25	39 1		31 1	1		2
20					12	22 1	0.2	51 2	1.8		10
24					7	18 1	0.5	56 2	2.5	0.2	12.8
30					0.2	12		61 1	1	0.8	24
50						10		44	1	2	33
4		0.2		88	61 5	19 1		5		0.8	
8			0.2	0.8	29	23 1		45 1			
12					13	41 1		42 3			0.2
16					4	36 3		53 2	0.5		1.5
20					3	25 2		61 2	1	0.5	6
24				0.1	0.9	19 1	0.2	54 1.6	0.2	5	18
30						19.5 0.3	0.2	18 1		23	37
50						16 0.2	0.1	13 0.5	0.2	30	40

Figures in italics = percentage of division forms.

in the course of a culture passage was found by counting the percentage of the various developmental stages (cf. Table 1). For RHAZGHA-REICHENOW-media at a temperature of 25-30° C it lies between the 20th and 50th day.

The inoculum was taken directly from a culture and injected subcutaneously with a syringe or a capillary pipette, 0.2 c.c. for newly born mice, 0.5 c.c. for young and adult ones and 2.0 c.c. for monkeys.

As most trypanosomes reside between the blood cells the test tube was previously slightly shaken, in order to obtain a more homogeneous distribution of the parasites.

1. Inoculation tests of white mice with cultures of T. rangeli.

a) Course of Parasitemia.

Disposition of tests.

For the control of parasitemia 10 test series were made during the years 1952/53³. Each series consisted of 10 animals. 0.2 c.c. of culture fluid were injected under the skin of the nape within 24 hours of birth. The parasite was detected either in fresh blood preparations or by means of xenodiagnosis and blood cultures.

The blood was examined daily from the 2nd day p.i. for 3 weeks. At the decline of parasitemia, when fresh blood samples had been negative for at least 3-5 days, reduviids were made to suck every 5th day during the first, and once during the second and the third month each.

Results. Of 100 inoculated animals 19 developed acute parasitemia, evident in fresh blood samples within 6-12 days from the 4th to 21st day after infection (cf. Table 2). The period of heaviest parasitemia (2-3 trypanosomes pro preparation) occurs in most cases on the 3rd day after blood-infestation, but it can also last to the 5th day or reappear on the 9th to the 12th day.

The phase of *chronic parasitemia* which was examined by xenodiagnosis lasted usually one month or even longer. In two animals only, blood infestation ceased already the 25th day after inoculation. In 4 cases parasitemia lasted over two months p.i.

Table 2 shows a decrease of virulence of this strain of *T. rangeli* for the homoiothermal host as observed during 1952/53. In the later inoculation series (series 7, 9, and 10) a distinct diminution of the blood infestation occurred, the blood form being demonstrable from the beginning only indirectly by means of xeno-

³ In two series 2 mice of the litter were left uninoculated each time as control animals.

TABLE 2.

Course of parasitemia in young mice infected with cultures of *T. rangeli* 24 hours after birth. The table includes the complete material of 23 mice which developed infection in 10 series of tests with 10 animals each.

Age of Infection Days	S 1	S 2	S 3	S 4	S 5	S 6	S 7	S 8	S 9	S 10
1										
2										
3										
4	+									
5	+									
6	++ +	+	+		+					
7	++ +	+	++	+	+	++		+		
8	++	++ +	++ +	+	+	+	+	+		
9	+	++ ++	+	++ ++	++		+	++	+	+
10	++ +	++ ++	+	+++ +	+	+	█	++ +		+
11	+	++ +	+	+	+	+	+	+		++
12	++ +	+	+	++	+	++ +		+	█	+
13	+	+	++ +	+	+	+	+	+		█
14	+	+	++ +	+	+	+	+	+	█	+
15		+	+	+	+	+				
16		+	+	+	+	+		+		
17		+		+						+
18	+	+		+			+	+		
19		+	+			+		+		
20		█	█	█	█	█	█	█	█	█
21		+								
22										
23										
24										
25	█	█	█	█	█	█	█	█	█	█
26										
27										
28										
29										
30		█	█	█	█	█	█	█	█	█
months										
2	█	█		█	█		█		█	⊕
3		█			█					
4					+	+				

÷ = 1 trypanosome/fresh blood preparation.

█ = positive xenodiagnosis.

⊕ = positive blood culture (for further explanations see text).

diagnosis. Chronic parasitemia lasted from the 10th to the 25th day p.i. for the weakest infection (series 7) and in the three other cases (series 9 and 10) from the 12th or the 14th day till the second month after inoculation.

b) *T. rangeli* in tissue.*Disposition of tests.*

Pre-parasitemic period. In order to examine the destiny of the trypanosomes injected with the culture fluid subcutaneously into the nape of 40 newly born mice, 10 inoculated animals were fixed in toto each time, after 24, 48, 72, and 96 hours. Then they were dissected into serial sections for the examination of the whole organism.

Parasitemic period. During the period of *acute parasitemia* 10 animals with trypanosome yielding blood were dissected each time on the 7th, 10th, 13th, and 17th days after infection during the period of *chronic parasitemia* (blood form detected by means of xenodiagnosis), 10 animals each time the 25th and 30th day as well as two and three months after inoculation. The behaviour of the parasite during the *post-parasitemic phase* was examined in 10 animals each time the 4th, 5th, and 6th months after inoculation.

Ossification being too advanced in 7-10 days old mice for serial sections to be satisfactory, the animals were not fixed in toto but their brain, lung, heart, spleen, liver, and kidney were used for histological studies.

Results.

Pre-parasitemic period. Serial sections through the inoculation region 24 and 48 hours after injection of culture fluid gave the following picture:

RES cells of the subcutis were found packed with phagocytosed erythrocytes and neutrophilic leucocytes. It is not possible to decide whether these blood cells derive from the inoculation material or from the lesion produced by the puncture. In addition to the blood cells, still distinctly recognizable, the phagocytes frequently harboured purple coloured droplets. These are considered as dissolved nuclei either of leucocytes or perhaps of forms of *T. rangeli*.

In no case could a clear structure of flagellates or division forms of the parasite be shown round the inoculation point, either in phagocytes, capillaries or directly in the tissue. After 72 hours the inoculation point is no longer distinguishable from normal tissue.

Analysis of serial sections, which allow the testing of the whole tissue of the host, gave negative results for the pre-parasitemic period.

The *parasitemic period* was also negative for tissue forms of *T. rangeli*. In sections of liver and heart as well as in smears and crush-preparations of these organs of test animals with heavy parasitemia, blood forms of *T. rangeli* could be demonstrated in two cases only. They were found in the heart and in portal blood.

Preparations of organs of the *post-parasitemic period* on the other hand showed no blood forms at all.

Histopathology.

Serial sections of whole animals and organs showed no pathological changes of the tissues in the whole infection period.

Pathology.

According to PIFANO's results the entire course of infection was without any pathological symptoms, even in newly born and thus specially susceptible test animals. The development of the infected animals differed in no way from that of the control animals of the same litter.

Morphology of the blood form corresponds entirely to PIFANO's descriptions. Division forms were not found.

2. *Inoculation tests with Macacus Rhesus.*

a) *Course of parasitemia.*

On two 2½-year-old monkeys of the species *Macacus Rhesus* (male and female) intramuscular inoculation of 2 c.c. culture fluid was practised. Both animals developed a weak parasitemia that could not be shown in fresh blood preparations or thick films but by xenodiagnosis only and in blood cultures.

As was demonstrated by xenodiagnosis the blood of the female was positive for the first time the 7th, that of the male the 10th day after inoculation. From the third week p.i. on parasitemia of both animals could be shown only by hemocultures. Blood cultures of the female were negative in the 7th, those of the male already in the 6th week.

b) *T. rangeli* in tissue.

On the 48th day after infection, i.e. in the post-parasitemic period, autopsy of the male animal was made. Brain-stem, cortex, and cerebellum, heart (large ventricle), lung, spleen, large lobe of liver, kidney, suprarenal gland, and diaphragm were fixed for histological analysis.

Histopathological studies as well as examinations of these organs for parasitic infestation showed evidence of trypanosomes.

Virulence of the strain.

The test with monkeys was made at a moment when inoculation tests with newly born white mice (cf. p. 196) showed already

a strong diminution of virulence of the parasite. It was hoped therefore that passage through the monkey would reactivate the virulence of the strain. Yet inoculation tests on white mice, made with cultures that had been inoculated with monkey blood, were not successful in that sense.

Discussion.

Our results of *parasitemia* in newly born white mice after subcutaneous inoculation are not directly comparable with PIFANO's observations. His test animals underwent intraperitoneal inoculation and their age at the time of infection is not mentioned.

The comparison of our results with PIFANO's brief description of blood infestation (no individual data are given), according to which 100 animals show a slightly higher infection rate (25-30%, PIFANO 25%) as well as the possibility of an earlier beginning of blood infestation (latent period 4th-13th day of infection, PIFANO: "end of the first week") leads to the assumption that PIFANO's tests were made with more resistant probably juvenile or adult white mice.

In accordance with PIFANO, my experiments also indicate that the period of the largest number of parasites is during the second week after infection, in most animals therefore between the 3rd and 5th day after blood infestation (7th-10th day after infection). While PIFANO observed irregular appearance and disappearance of trypanosomes in the blood only at the beginning of the 3rd week, my tests show this fluctuation already during the second week of infection, i.e. for the majority of the test animals 2-5 days after blood infestation. In two cases I observed a second maximum of parasite density between the 12th and 14th day of infection (7th-9th day after blood infestation).

PIFANO's descriptions do not make clear how long the parasites can be detected in fresh blood preparations. His opinion is that the trypanosomes appear in the blood from the third week on irregularly and in decreasing number and eventually disappear altogether from the circulation. Latent parasitemia, only detectable by xenodiagnosis, is, however, supposed to last for 4 to 6 months after inoculation. My experiments reveal the latest data for direct detection of the blood form to be the 21st day after infection. Contrary to PIFANO's findings I was not able to prove either by xenodiagnosis or by the most effective method of blood culture, that parasitemia could last longer than 3 months after infection. In 4 animals parasitemia was so weak from the beginning that it could be demonstrated only by xenodiagnosis. In three cases it disappeared already at the end of the first, in one case in the course of the

second month of infection. I hold that this type of infection is due to loss of virulence of my strain, perceptible in the course of the 3rd year of continuous culture passages in the homoiothermal host.

Macacus Rhesus is very susceptible to *T. rangeli*. Both test animals developed slight parasitemia after subcutaneous injection of 2 c.c. culture fluid, evident during the acute period by xenodiagnosis but during the chronic period only in blood cultures.

When the latent period was 7 days (female) and 10 days (male), the acute phase of parasitemia lasted 11 and 14 days. Chronic phase of the female did not exceed 5 weeks, while blood cultures of the male were free from parasites already one week before autopsy, i.e. after a chronical phase of only 4 weeks.

Regarding the diminution of virulence of our strain as well as the efficiency of PIFANO's inoculation method, our results seem in accordance with his description of the parasitemia of an experimentally infected *Cebus* sp. After simultaneous subcutaneous and intraperitoneal inoculation of *T. rangeli* in culture fluid, this *Cebus* sp. developed also a slight parasitemia which showed itself by direct blood examination only in the 2 first weeks p.i. After this period the infection declined to a latent blood infestation demonstrable only by xenodiagnosis and hemoculture.

No new contribution can be added to PIFANO's observations concerning the *morphology* of *T. rangeli* in the blood of white mice. In accordance with this author division stages of the blood form which since have been observed in heavy laboratory infection with haemolymph of parasitized reduviids (GREWAL, SINGH M. 1957), could not be found.

Histological analysis of a total of 130 white mice, examined during various phases of their infection (24 hours to 3 months after inoculation), as well as histological findings in various organs of monkeys during the post-parasitemic phase of infection lead to the conclusion that *T. rangeli* does not develop tissue forms in the homoiothermal host. The only parasites found in sections of organs and crushed preparations were blood forms in the liver and in the blood of the heart of test animals with heavy parasitemia, they are undistinguishable from the trypanosomal form of the peripheral blood.

Starting from the observation that already 24 hours after inoculation no definite signs of the presence of trypanosomes can be found either in the phagocytes of the resorption zone or in the space between the tissue of the subcutis, it can be assumed that certain developmental stages of the parasite penetrate directly from the inoculation material into the capillaries. Other stages, incapable of developing in the homoiothermal host, would have

been phagocytized by the RES cells already within this period and digestion would be too advanced for their shape to be distinguishable.

From the comparison of *T. rangeli* with *T. cruzi*, the primary tissue forms of which can be shown in the RES cells of the subcutis for at least 4 days, it seems that 24 hours after the penetration of the parasite was not too late a term for the study of primary tissue forms of *T. rangeli*.

The negative results of these investigations, i.e. absence of division forms in the tissue on one side, and absence of a division stage in the blood form on the other, could be explained as follows:

T. rangeli multiplies only in the stage of blood form in the mammal host and does not develop tissue forms. The fact that neither PIFANO and his collaborators nor myself were able to find division stages of the blood form is due to an extremely weak blood infestation, offering but little chance to find a division form, considering that these are relatively rare.

It was probable (as since proved by GREWAL, S. M. 1956) that heavier blood infections would give evidence of the division stage of *T. rangeli*. The only support to our theory was then GROOT's report on his investigations of *T. ariarii*. This trypanosome, as far as it is yet known, resembles *T. rangeli* both morphologically and biologically and in the opinion of PIFANO and other authors [HERNANDEZ DE PAREDES and PAREDES, R. (1949) — REY, H. (1941)] is believed to be identical with it.

Division stages of the blood form of *T. ariarii* (10 division forms per 120 blood forms) which develops a much heavier parasitemia in mammals than *T. rangeli* (man, *Cebus fatuellus*, dog) even after natural infection, could be demonstrated in mice experimentally infected with cultures of *T. ariarii*.

GROOT's histological analysis of young white mice (up to 6 days old) corresponds in all points to the results which I obtained with *T. rangeli*. GROOT could detect neither tissue forms, nor blood forms of *T. ariarii* in sections of organs.

The following contribution can be made to the problem of pathogenicity: neither in white mice of various ages nor in organs of *Macacus Rhesus* could any signs of histopathological changes be observed. This corresponds to GROOT's results with *T. ariarii* and concerns also the absence of any exterior symptoms of the disease in the test animal. GROOT found no symptoms either in naturally or in experimentally infected men, dogs, monkeys, white mice, and marsupialian rats. Neither have PIFANO and his collaborators any valid proofs of a disease caused by infection with *T. rangeli*, either in man or in naturally or experimentally infected

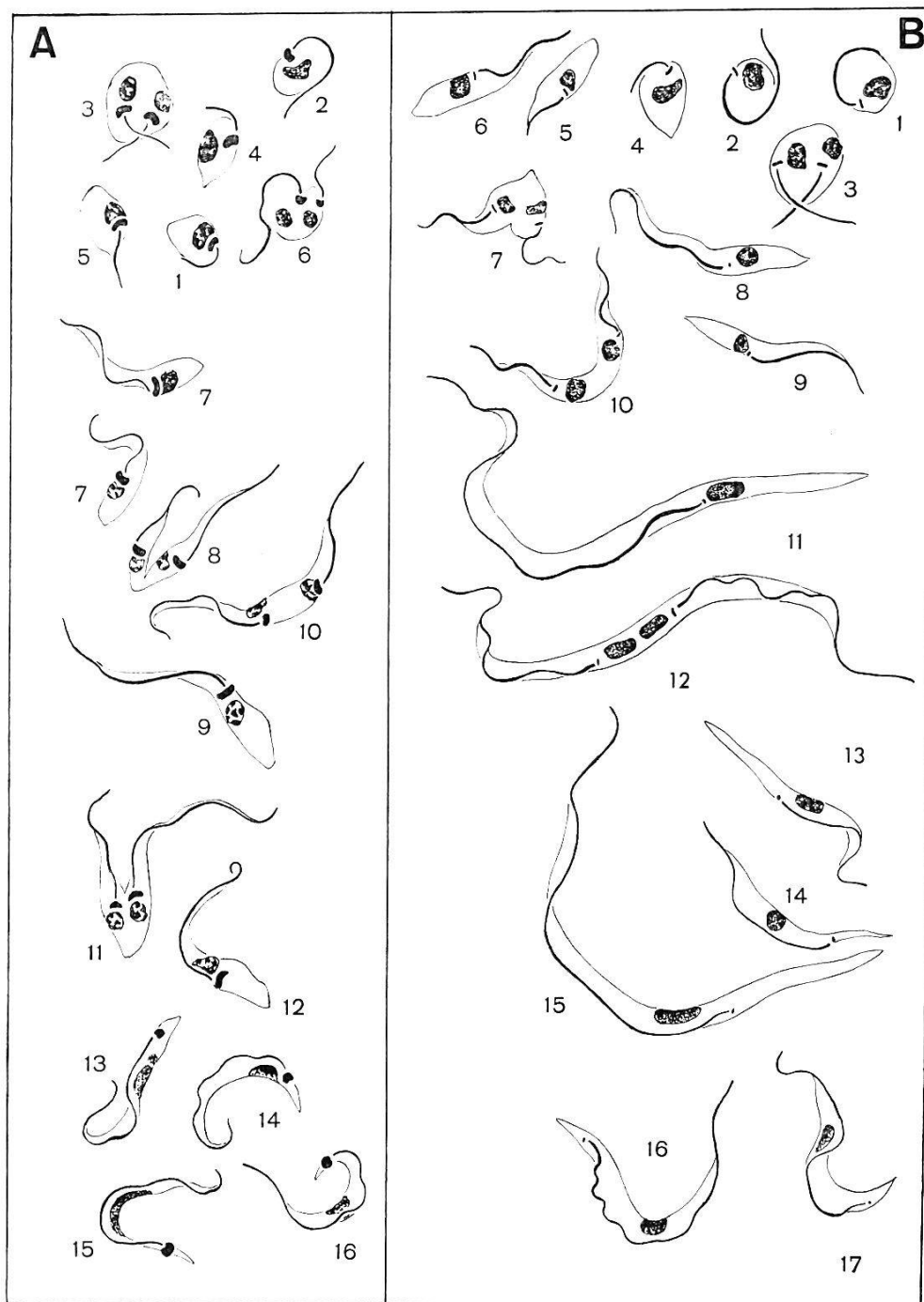


Fig. 1. Comparative description of developmental stages of A: *T. cruzi* and B: *T. rangeli*⁴.

A 2 and 3: flagellated round forms; A 3 in division. A 1, 4 and 5: transitional forms between round form and short crithidia; A 6 in division. A 7: short crithidia; A 8: division form of short crithidia. A 9: long crithidia; A 10 and 11: division form of long crithidia. A 12: transitional form between crithidia and metacyclic form. A 13 and 14: immature, A 15 mature metacyclic forms. A 16: blood form.

B 1: round form with marginal portion of flagellum; B 2: flagellated round form; B 3: round form in division; B 4: transitional form between round form and leptomonal crithidia; B 5: non-flagellated leptomonal crithidia; B 6: flagellated leptomonal crithidia; B 7: in division; B 8 and 9: short forms of "long crithidia"; B 10 in division; B 11: long form of "long crithidia", B 12 in division; B 13: transitional form between "long crithidia" (short form) and metacyclic form; B 14 and 15: metacyclic forms, B 14 short, B 15 long form; B 16 and 17: blood forms.

⁴ Developmental stages drawn after gut smears of *Rhodnius prolixus*, smears of culture media and blood of infected mice. (Haemolymph- and salivary gland-forms of the reduviid not included.)

vertebrate animals. Starting from these results and particularly from the fact that it is absolutely apathogenic for *Macacus Rhesus*, I hold that *T. rangeli* can be of only little importance as a pathogenic agent to man.

II. Comparison of the main diagnostic characteristics of *T. rangeli* and *T. cruzi*.

As parasitemia caused by *T. rangeli* is considerably weaker than that caused by *T. cruzi*, the parasite can hardly be found in the peripheral blood of human infections. Blood examination in fresh blood preparations, smears and thick films is therefore not sufficient for diagnosis; xenodiagnosis and blood culture, however, are successful.

In order to facilitate differentiation of *T. rangeli* and *T. cruzi*, especially for xenodiagnosis and blood culture, a comparison of the main morphological differences is given below (cf. fig. 1).

According to BRUMPT, the earliest developmental forms of *T. cruzi* are round, oval or pear-shaped stages, provided either with the marginal part of flagellum only, or with a free flagellum (A 1-6). The pear-shaped forms develop into a short crithidial stage (A 7+8) which is followed by long shaped crithidial generations (A 9+10). These long forms divide into short crithidia again (A 12) and those are transformed into trypanosomal forms (A 13-16).

Comparing the succession of stages of *T. cruzi* with that of *T. rangeli* it is found that it is identical for round, oval, and pear-shaped stages as well as for short crithidia which occur in both species (A 1-8/B 1-7). Furthermore elongated crithidia generations following primary short forms is also a process occurring in both species (A 9+10/B 11+12).

Differences in the development of *T. cruzi* and *T. rangeli* are: Division of the latter into a short form within the long crithidial stage (B 8-10) and into an extremely elongated form (B 11+12) both of which can develop trypanosomal forms. From these derives for *T. rangeli* a typical long and a short metacyclic form (B 13-15).

Dimensions of round, oval, and pear-shaped forms of the two species as well as their primary short crithidia and leptomonad crithidia hardly differ. The long crithidial stages and the trypanosomal forms (metacyclic and blood forms), however, vary in size, thus excluding any confusion of the two species (cf. Table 3).

The most distinctive morphological characteristic of *T. rangeli* and *T. cruzi* is the small point- or rod-shaped kinetoplast of the former, present in all developmental stages, which is in striking

TABLE 3.

Difference in size of developmental stages of *T. rangeli* and *T. cruzi*.

<i>T. rangeli</i>	Round forms	Leptomonal crithidia	Long crithidia		Metacyclic form		Blood form
	Dm	Total length	short form	long form	short form	long form	Total length
	5-8 μ	18-22 μ	27-35 μ	40-61 μ	22-28 μ	39-58 μ	30.5-38 μ
<i>T. cruzi</i>	Round forms	Primary small crithidia	Long crithidia	Secondary small crithid.	Metacyclic form	Blood form	
	Dm	Total length	Total length	Total length	Total length	Tot. length	
	6-7 μ	16-20 μ	28-32 μ	18-23 μ	18-25 μ	20 μ	

opposition to the voluminous halfmoon-shaped kinetoplast of *T. cruzi*. As to the shape of crithidia a distinctive characteristic of those of *T. rangeli* is the extremely long and drawn out posterior end, the relatively long free flagellum and the well developed undulating membrane. Crithidia of *T. cruzi* instead have a tadpole-shaped form with a thick posterior end, a relatively short free flagellum and an inconspicuous undulating membrane (A 7+9/B 8+10).

Similar differences occur also in the trypanosomal form (long form of the metacyclic and blood form). Besides considerable differences in their length, *T. rangeli* has a well developed undulating membrane, a relatively long flagellum, and the kinetoplast has a definite subterminal position (A 14-16/B 15-17).

A few biological observations which are significant for the examination of xenodiagnostic controls are added below. As known, reduviids excrete immediately after their meal several droplets, those from infected insects yielding parasites. The first two droplets are thick and of brownish colour, while further excrements are thin and transparent. The condition of the excrements to be examined is important inasmuch as the transparent droplets are practically free from *T. rangeli*. They are found only in the brown excrements, where crithidial forms of *T. rangeli* dominate, metacyclic forms instead are relatively scarce. For *T. cruzi* conditions are somewhat different: brown as well as transparent droplets contain parasites, brown droplets yielding a greater number of metacyclic forms, crithidia are contained only in small number in faeces. In the transparent secretion which so to speak washes the remaining trypanosomes out of the hindgut, only mature metacyclic forms are found.

References.

- BRUMPT, E.: (1949). Précis de Parasitologie. 6^e éd. — Paris: Masson & Cie.
- GEIGY, R. & HERBIG, A. (1955). Erreger und Überträger tropischer Krankheiten. Basel: Verlag für Recht und Gesellschaft.
- GREWAL, S. M. (1957). Pathogenicity of *Trypanosoma rangeli* Tejera 1920 in the invertebrate host. — Exper. Parasitol. 6, 123-130.
- GREWAL, S. M. (1956). *Trypanosoma rangeli* Tejera 1920 in its vertebrate and invertebrate hosts. — Trans. Royal Soc. Trop. Med. and Hyg. 50, 301-302.
- GROOT, H. (1952). Further observations on *Trypanosoma ariarii* of Colombia, South America. — Amer. J. trop. Med. and Hyg. 1, 585-592.
- HERBIG-SANDREUTER, A. (1955). Experimentelle Untersuchungen über den Cyclus von *Trypanosoma rangeli* Tejera 1920 im Warmblüter und in *Rhodnius prolixus*. — Acta Tropica 12, 261-264.
- HERNANDEZ-DE-PAREDES, C. & PAREDES-MANRIQUE, R. (1949). Un caso de infección humana por *T. rangeli*. — Rev. Fac. Med. Bogotá 18, 343-375.
- HOARE, C. A. (1953). *Trypanosoma rangeli*, the second American trypanosome of man, and its affinities. — Trans. Royal Soc. Trop. Med. and Hyg. 47, 271-272.
- PIFANO, C. F. (1954). Nueva trypanosomiasis humana de la región neotrópica producida por el *Trypanosoma rangeli*, con especial referencia a Venezuela. — Arch. Venezol. Patol. trop. y Parasit. méd. 2, 89-120.
- REICHENOW, EDUARD (1957). Über *Trypanosoma rangeli* und die Entwicklung des Blutparasitismus der Säugetiertrypanosomen. — Zs. Tropenmed. 8, 219 bis 224.
- REY, H. (1941). Anotaciones sobre el Laboratorio de Parasitología, Tesis Facultad de Medicina, Bogotá.
- ZELEDÓN, R. (1956). Hallazgo de formas evolutivas de *Trypanosoma rangeli* Tejera, 1919, en glándulas salivares de *Rhodnius prolixus* Stal., 1859 salvadoreños. — Rev. Biol. trop. 4, 1-7.

Résumé.

Afin de poursuivre les recherches sur le cycle de *T. rangeli* chez les homoïothermes, nous avons inoculé 230 souris blanches et deux singes avec *T. rangeli* provenant de cultures de Rhazgha. Il s'agissait de souris nouveau-nées et de deux singes (*Macacus rhesus*) âgés d'un an et demi. Quatre jours après l'inoculation, les souris présentaient une parasitémie aiguë (démonstration directe du parasite par analyse du sang périphérique). Après le 20^e jour, cette parasitémie est devenue chronique (démonstration indirecte du parasite par la xénodiagnose et l'hémoculture. Cette parasitémie s'est prolongée jusqu'au 3^e mois p. i.

Chez les singes, nous avons observé, entre la 1^{re} et la 7^e semaine, une faible parasitémie que l'on ne pouvait constater, dès le début, que par la xénodiagnose ou l'hémoculture.

Nous avons observé et analysé histologiquement le comportement de *T. rangeli* dans les tissus de 130 souris blanches à différents stades d'infection (24 h à 3 mois après inoculation). Les animaux âgés de moins de 10 jours ont été étudiés entièrement sur coupes sériées, tandis que, pour les souris plus âgées et les singes, seuls les différents organes ont été examinés (tronc cérébral, écorce, cervelet, grand ventricule du cœur, poumon, rate, foie, rein, capsule surrénale, corps thyroïde, organes génitaux, ainsi que des parties de l'estomac, du diaphragme et des muscles).

Nous n'avons pas trouvé de formes tissulaires rappelant *T. cruzi* sur les quelques milliers de coupes examinées. Dans de rares cas, les préparations

histologiques ne montraient des formes trypanosomes que dans le sang du foie et du cœur d'animaux à forte parasitémie. Morphologiquement, on ne peut différencier ces formes de celle du trypanosome du sang périphérique. Quant au pouvoir pathogène de *T. rangeli* sur l'homoïotherme, nous pouvons affirmer qu'aucun signe d'altération histopathologique n'a pu être observé, soit chez les souris blanches, soit chez les macaques.

Dans la deuxième partie de la publication, l'auteur compare les principaux signes distinctifs diagnostiques de *T. cruzi* et *T. rangeli*, lesquels ont une grande importance dans la détermination des trypanosomes, soit par xénodiagnose, hémoculture, ou sur des préparations hématologiques.

Zusammenfassung.

Zum weiteren Studium des Cyclus von *T. rangeli* im Warmblüter wurden 230 neugeborene weiße Mäuse und zwei 1½ jährige Affen (*Macacus rhesus*) mit *T. rangeli* aus Rhazghakulturen inokuliert. Bei 19% der Mäuse entwickelte sich nach dem 4. Infektionstag eine akute *Parasitämie* (direkter Nachweis der Blutform im Peripherblut), die um den 20. Tag p. i. in eine chronische Phase überging (indirekter Nachweis der Blutform über Xenodiagnose und Blutkultur) und bis in den 3. Monat p. i. andauerte.

Bei den Affen beobachteten wir zwischen der 1. und 7. Woche p. i. einen schwachen Blutbefall, der sich von Anfang an nur xenodiagnostisch oder über Blutkulturen feststellen ließ.

Das Verhalten von *T. rangeli* im Gewebe verfolgten wir bei 130 weißen Mäusen, die auf verschiedene Infektionsalter verteilt (24 Stunden bis 3 Monate nach der Inokulation) histologisch verarbeitet wurden. Junge Tiere (bis zum Alter von 10 Tagen) haben wir total in Serienschnitte zerlegt, während bei älteren Mäusen und bei den Affen nur einzelne Organe geschnitten wurden, d. h. Hirnstamm, Cortex, Kleinhirn, großer Herzventrikel, Lunge, Milz, Leber, Niere, Nebenniere, Thyreoidea, Geschlechtsorgane, sowie Partien des Darmes, des Diaphragmas und der Skelettmuskulatur.

In diesen mehreren tausend Schnitten konnten keinerlei Gewebeformen im Sinne von *T. cruzi* gefunden werden. Die einzigen Parasitenformen, die wir in seltenen Fällen in Organschnitten und Quetschpräparaten beobachteten, waren Blutformen in Leber- und Herzblut stark parasitämischer Versuchstiere; sie sind von der Trypanosomenform im Peripherblut morphologisch nicht zu unterscheiden. Zur Frage der *Pathogenität* von *T. rangeli* für den Warmblüter können wir beitragen, daß weder bei den weißen Mäusen noch bei den Macacen irgendwelche Anzeichen histopathologischer Veränderungen zu beobachten waren.

Der zweite Teil der Publikation gibt eine Gegenüberstellung der wichtigsten diagnostischen Merkmale von *T. cruzi* und *T. rangeli*, die zur Beurteilung von Trypanosomenmaterial von Xenodiagnosen, in Blutkulturen und Blutpräparaten von Bedeutung sind.