

Ultrasonographic findings in a cow with ascites due to thrombosis of the caudal vena cava

Autor(en): **Braun, U. / Schefer, U. / Gerber, D.**

Objekttyp: **Article**

Zeitschrift: **Schweizer Archiv für Tierheilkunde SAT : die Fachzeitschrift für Tierärztinnen und Tierärzte = Archives Suisses de Médecine Vétérinaire ASMV : la revue professionnelle des vétérinaires**

Band (Jahr): **134 (1992)**

Heft 5

PDF erstellt am: **20.09.2024**

Persistenter Link: <https://doi.org/10.5169/seals-590387>

Nutzungsbedingungen

Die ETH-Bibliothek ist Anbieterin der digitalisierten Zeitschriften. Sie besitzt keine Urheberrechte an den Inhalten der Zeitschriften. Die Rechte liegen in der Regel bei den Herausgebern.

Die auf der Plattform e-periodica veröffentlichten Dokumente stehen für nicht-kommerzielle Zwecke in Lehre und Forschung sowie für die private Nutzung frei zur Verfügung. Einzelne Dateien oder Ausdrucke aus diesem Angebot können zusammen mit diesen Nutzungsbedingungen und den korrekten Herkunftsbezeichnungen weitergegeben werden.

Das Veröffentlichen von Bildern in Print- und Online-Publikationen ist nur mit vorheriger Genehmigung der Rechteinhaber erlaubt. Die systematische Speicherung von Teilen des elektronischen Angebots auf anderen Servern bedarf ebenfalls des schriftlichen Einverständnisses der Rechteinhaber.

Haftungsausschluss

Alle Angaben erfolgen ohne Gewähr für Vollständigkeit oder Richtigkeit. Es wird keine Haftung übernommen für Schäden durch die Verwendung von Informationen aus diesem Online-Angebot oder durch das Fehlen von Informationen. Dies gilt auch für Inhalte Dritter, die über dieses Angebot zugänglich sind.

ULTRASONOGRAPHIC FINDINGS IN A COW WITH ASCITES DUE TO THROMBOSIS OF THE CAUDAL VENA CAVA

U. BRAUN, U. SCHEFER, D. GERBER, J. FÖHN

ULTRASONOGRAPHISCHE BEFUNDE BEI EINER KUH MIT ASZITES INFOLGE THROMBOSE DER VENA CAVA CAUDALIS

Es wird eine 3jährige Braunviehkuh beschrieben, die an einem Aszites infolge Thrombose der Vena cava caudalis erkrankt war. Der klinische Verdacht des Aszites wurde mit Hilfe der ultrasonographischen Untersuchung des Abdomens bestätigt. Neben einer massiven Flüssigkeitsansammlung konnte eine deutliche Dilatation des abdominalen Teiles der Vena cava caudalis (4,8 cm) nachgewiesen werden. Diese Befunde liessen den Schluss zu, dass die Vena cava caudalis im kranialen Bereich durch einen Thrombus oder eine Kompression des Venenlumens von aussen gestaut sein musste. Bei der Schlachtung wurde ausser einer massiven Flüssigkeitsansammlung im Abdomen ein ca. 15 cm langer Thrombus im subphrenischen Teil der Vena cava caudalis gefunden. Die Lunge wies multiple Abszesse und eine hochgradige Thrombosierung ihrer Gefässe auf. Die Leber war gestaut. Die Labmagenfalten waren ödematisiert. Weiter hatte die Kuh hochgradige injektionsbedingte Thrombophlebitiden im Bereich der linken Jugularvene und beider Eutervenen. Da ein Aszites bei einer Thrombose der Vena cava caudalis infolge mehrerer, zum Herzen ziehender Kollateralvenen selten ist, wird vermutet, dass die beidseitige massive Thrombosierung der Eutervenen zur Entwicklung des Aszites beigetragen hat, da ein wichtiger Teil der Kollateralwege ebenfalls unterbrochen war.

SCHLÜSSELWÖRTER: Ultrasonographie - Thrombose Vena cava caudalis - Aszites - Thrombophlebitis Eutervenen - Lungenabszesse - Kuh

SUMMARY

This case report describes a three-year-old Swiss Braunvieh cow with ascites due to thrombosis of the caudal vena cava. Ultrasonography verified the ascites and revealed dilatation of the abdominal portion of the caudal vena cava (4.8 cm). It was presumed that the caudal vena cava was occluded by a thrombus or by perivenous compression cranial to the dilatation. Post mortem findings included: a massive accumulation of fluid in the abdominal cavity; a 15 cm long thrombus in the subphrenic region of the caudal vena cava; multiple pulmonary abscesses; severe thrombosis of the pulmonary vasculature; hepatic congestion; oedematous abomasal folds; and severe thrombophlebitis of the left jugular vein and both udder veins, due to poor intravenous injection technique. Ascites caused by thrombosis of the caudal vena cava is rare because collateral routes of venous return, including the udder veins, are usually established. It was therefore concluded that the ascites was attributable to bilateral thrombosis of the udder veins.

KEY WORDS: ultrasonography - thrombosis of the caudal vena cava - ascites - thrombophlebitis of the udder veins - pulmonary abscesses - cow

Herrn Prof. Dr. Dr. h.c. Stöber mit den besten Wünschen zum 65. Geburtstag

INTRODUCTION

Non-inflammatory ascites is characterized by an enormous accumulation of fluid in the abdominal cavity. Ascites is usually attributable to congestion; however, other causes in-

clude reduced osmotic pressure resulting from hypoalbuminaemia, sodium retention, secondary aldosteronism, and peritoneal diseases. Usually, a combination of these factors result in ascites.

The most important causes of ascites due to congestion are chronic heart disease and severe, chronic liver disease with portal hypertension. Ascites due to congestion may also develop after ileus and intestinal volvulus. Thrombosis of the caudal vena cava is a rare cause of ascites since venous return occurs via collateral routes such as the udder, azygos, and spinal veins (*Selman et al.*, 1974).

A clinical diagnosis of ascites is based on the following findings: a pear-shaped abdomen with symmetrical distension of the ventral abdomen, a flaccid abdominal wall, and a fluctuating abdominal content on palpation. Differential diagnosis must include rupture of the bladder which can be ruled-out by the results of abdominocentesis. Abdominal fluid in non-infectious ascites is clear, yellow and has a low specific gravity, a low protein content, and few cells.

In ascites caused by right-sided heart failure, the jugular veins are distended. If the jugular veins are normal, other causes of ascites must be considered; liver disease with portal hypertension, obstruction or compression of the caudal vena cava, and hypoalbuminaemia are possible rule-outs. Severe hypoalbuminaemia in cattle is associated with oedema. Serum liver enzyme activity is increased in liver disease and in obstruction or compression of the caudal vena cava; however, the degree of increase does not allow differentiation between the two. In human beings, ultrasonography has been used to diagnose thrombosis of the inferior vena cava (*Vollmer et al.*, 1990) and of the portal vein (*Letourneau et al.*, 1987) and liver abnormalities including tumors and abscesses (*Kremer and Dobrinski*, 1988). Ultrasonography of the healthy bovine liver and its vasculature has recently been described (*Braun*, 1990). In addition, liver abscesses and other abnormalities of the liver have been diagnosed by ultrasonography in cattle (*Itabisashi et al.*, 1987; *Jönsson et al.*, 1988; *Lechtenberg and Nagaraja*, 1991). To our knowledge, there are no published reports describing the diagnosis of obstruction of the caudal vena cava in cattle by use of ultrasonography.

The following report describes the clinical, ultrasonographic, clinical-pathologic, and post mortem findings of a three-year-old Swiss Braunvieh cow with ascites caused by thrombosis of the caudal vena cava. The cow had calved 11 weeks prior to admission and the calving and post partem periods were normal. Three weeks before admission, the cow had a decreased appetite and was treated several times by the referring veterinarian, although a specific diagnosis could not be

made. However, her condition deteriorated, and the cow was then admitted to our clinic.

CLINICAL EXAMINATION

The cow was very thin and had a lusterless haircoat, reduced dermal turgor, a pendulous abdomen, and brisket oedema. The general behaviour and attitude of the cow was moderately to severely disturbed; she was apathetic and anorexic. The lymph nodes were unremarkable. The heart rate was 72 beats per minute with strong, regular sounds. The respiratory rate was 24 breaths per minute and after forced breath holding the cow coughed twice. Auscultation of the lungs revealed increased vesicular sounds with super-imposed wheezes. Ruminal motility and content were reduced. Intestinal motility was normal. Tests for traumatic reticuloperitonitis and percussion and simultaneous auscultation of the abdomen revealed no abnormalities. A rectal examination could not be performed due to severe tenesmus. The faeces had a soupy consistency. The urine had a specific gravity of 1030, and a dipstick test was normal. The abdominal wall was soft. There was severe thrombophlebitis of the left jugular vein and both udder veins, caused by poor intravenous injection technique. There was a 30 x 15 cm firm, painful swelling over the right udder vein. The tentative diagnosis was ascites.

CLINICAL PATHOLOGY

The cow had leukocytosis with neutrophilia and moderately severe, regenerative, normochromic, normocytic anaemia (table 1). Plasma protein and fibrinogen concentrations were normal; however, the albumin concentration was lower than normal. Bilirubin concentration and gamma-glutamyltransferase activity were slightly increased. Blood gas analysis was normal. Examination of ruminal fluid revealed inactivity of the flora and fauna and an increased chloride concentration of 37 mmol/l.

ABDOMINOCENTESIS

Abdominocentesis, performed cranial to the right stifle joint, yielded a stream of clear, yellow fluid which had a specific gravity of 1020, a protein concentration of 30 g/l, and a cell count of 400 cells/ μ l.

ULTRASONIC EXAMINATION OF THE ABDOMEN

The right flank and area over the last seven intercostal spaces were clipped and the remaining hair was removed with hair removal cream. After application of transmission gel, the ultrasonic examination was performed using a 2.5 MHz

ULTRASONOGRAPHIC FINDINGS IN A COW WITH ASCITES

Table 1: Haematological and biochemical analyses of blood from a cow with ascites due to thrombosis of the caudal vena cava

Measurement		Value of the cow with ascites	Reference values
Erythrocyte count	($10^6 / \mu\text{l}$)	4.73	5.0–8.0
Haematocrit	(%)	19	28–38
Haemoglobin	(g / dl)	6.1	9.0–14.0
Leukocyte count	(/ μl)	13 000	4000–10 000
Total protein	(g / litre)	60	60–80
Fibrinogen	(g / litre)	6	4–6
Albumin	(g / litre)	23.4	30–40
Bilirubin	($\mu\text{mol} / \text{litre}$)	15.2	0.8–8.6
GLDH	(U / litre)	4.3	2.0–12.0
Gamma-GT	(U / litre)	27.0	6.0–17.0
SDH	(U / litre)	4.0	0–12.0
Urea	(mmol / l)	2.6	2.5–7.5
Sodium	(mmol / litre)	139.0	140–150
Chloride	(mmol / litre)	116.0	95–105
Potassium	(mmol / litre)	4.0	4.0–5.0

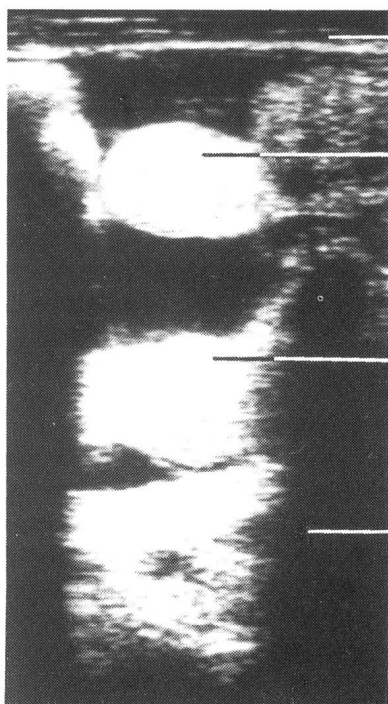


Fig. 1: Ultrasonogram of the abdomen imaged from the ventral region of the flank. Ultrasonic image shows fluid accumulation (ascites) and intestinal loops swimming in the fluid. Top line = abdominal wall; second and third lines = intestinal loops; bottom line = ascites fluid

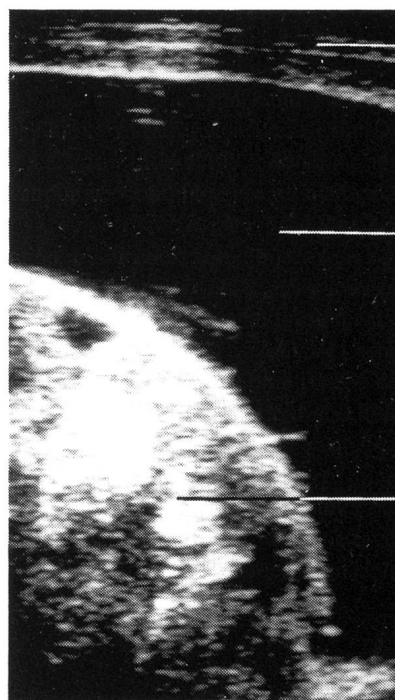


Fig. 2: Ultrasonogram of the abdomen imaged from the 8th intercostal space. Ultrasonic image shows fluid accumulation (ascites) between the abdominal wall and the omasum which normally is directly adjacent to the abdominal wall. Top line = abdominal wall; middle line = ascites fluid; bottom line = omasum

convex and a 3.5 MHz linear real-time scanner (LSC 7000, Picker International GmbH, Leu AG, St.-Karli-Strasse 21, CH-6004 Luzern). The abdomen was systematically examined with the scanner from dorsal to ventral, beginning caudally and advancing cranially. The most striking finding was an enormous accumulation of fluid in the abdomen. Intestinal

loops floating in fluid could be visualized in the entire ventral abdomen (Fig. 1). The liver and omasum, usually observed against the abdominal wall, were pushed away from it and were surrounded by ascitic fluid (Fig. 2). The liver structure was ultrasonically normal; however, the hepatic veins were dilated. The caudal vena cava near the liver was dilated. In

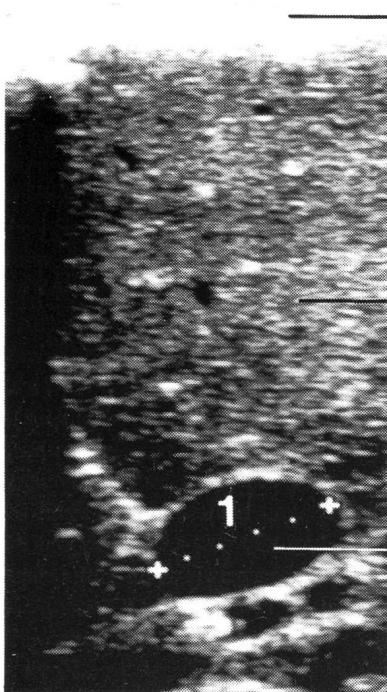


Fig. 3: Ultrasonogram of liver texture and caudal vena cava in a cow with thrombosis of the caudal v. cava in the subphrenic region. The ultrasonogram was obtained from the 11th intercostal space with a 3.5 MHz linear transducer about 20 cm distal to the midline of the back. The caudal v. cava has an oval shape and an enlarged diameter of 4.8 cm due to congestion; 1 diameter of caudal v. cava (4.8 cm). Top line = abdominal wall; middle line = liver texture; bottom line = caudal v. cava

Fig. 4: Ultrasonogram of normal liver texture and normal caudal v. cava in a healthy cow obtained from the 11th intercostal space with a 3.5 MHz convex transducer about 20 cm distal to the midline of the back. The caudal v. cava has a triangular shape on cross section. Top line = abdominal wall; second line = liver texture; third line = caudal v. cava

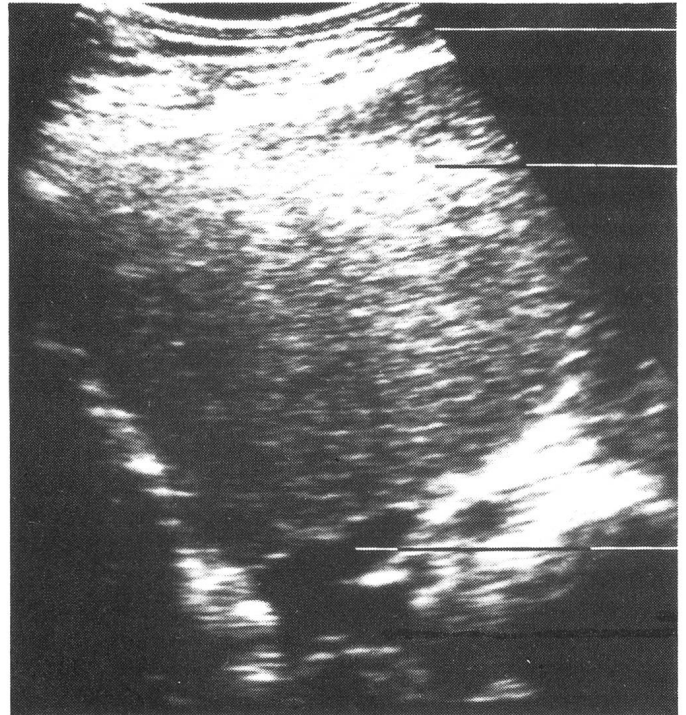


Fig. 5: Ultrasonogram of the right kidney and the caudal v. cava obtained through the so-called liver window from the 12th intercostal space. Top line = abdominal wall; second line = liver texture, third line = right kidney; bottom line = caudal v. cava

cross-section, the caudal vena cava had an oval shape with a diameter of 4.8 cm (Fig. 3). In ultrasonograms of healthy cows, the caudal vena cava near the liver has a triangular cross-sectional shape and a diameter of 2.5 to 4.0 cm (Braun, 1990; Fig. 4). The shape and diameter of the portal vein were normal. In addition, the ultrasonogram of the right kidney revealed no abnormalities. In the area of the right kidney, the caudal vena cava (Fig. 5) and the renal vein were dilated. The ureter was normal.

DIAGNOSIS

Based on the clinical, laboratory and ultrasonic findings, a diagnosis of ascites was made. A ruptured ureter could be ruled-out from the results of abdominocentesis and of ultrasonography. The ultrasonogram revealed dilatation of the abdominal portion of the caudal vena cava, which suggested that there was an obstruction cranially. It was concluded that the obstruction must have been in the caudal vena cava

ULTRASONOGRAPHIC FINDINGS IN A COW WITH ASCITES

because the jugular veins were not engorged. Possible causes of the obstruction were thought to be thrombosis or compression due to perivenous processes. Thrombosis was thought to be the most likely cause based on the abnormal pulmonary findings. The cow was slaughtered due to her deteriorating condition and poor prognosis.

POST MORTEM FINDINGS

Approximately 40 l of clear, yellow, inoffensive smelling fluid flowed out of the abdominal cavity. The 30 cm x 15 cm swelling over the right udder vein was a necrotic, foul smelling phlegmon with abscessation. The liver was congested and had a marbled appearance. The abomasal folds were oedematous. There was an abscess, 10 cm in diameter, in the left lung; it had a spongy texture, was compartmentalized and contained necrotic, watery and foul smelling fluid from which *Actinomyces pyogenes* was cultured. There were multiple small abscesses (1 to 2 cm in diameter) in the right lung. There was severe thrombosis of the pulmonary vasculature. There was a 15 cm long yellow, friable, foul smelling thrombus in the subphrenic area of the caudal vena cava. It almost entirely occluded the vein.

DISCUSSION

The clinical findings of thrombosis of the caudal vena cava in cattle have been described in detail (Rubarth, 1960; Stöber, 1966; Selman et al., 1974; Breeze et al., 1976; Jensen et al., 1976; Gudmundson et al., 1978; Rebhun et al., 1980; Ikawa et al., 1987; Mills and Pace, 1990). Reports dating back to the last century were summarized by Stöber (1966). The most commonly cited cause of thrombosis of the caudal vena cava is rupture of a liver abscess into this vein. The thrombus is usually situated in the caudal vena cava near the liver, and emboli may travel to the lung causing endarteritis, abscessation, and chronic suppurative bronchopneumonia. Aneurysms, resulting from hypertension in the pulmonary artery, may rupture causing massive intrapulmonary or intrabronchial haemorrhage. Haemorrhage may also result from the rupture of a pulmonary abscess into the airways. Sometimes the abscess causing clinical symptoms is in the perirenal, subphrenic or thoracic area of the caudal vena cava. Septic emboli from a nidus of infection in the udder, uterus, or foot may also result in thrombosis of the caudal vena cava (Smith, 1990). However, there have been cases in which no nidus was found (Selman et al., 1974). In this report, the thrombosis in the caudal vena cava was probably attributable to the phlegmon of the severely thrombosed udder veins.

Sudden death may occur in thrombosis of the caudal vena cava. However, most cases have a chronic course often with abnormal respiratory signs as well as other non-specific clinical symptoms. The behaviour and attitude of affected cattle are usually moderately disturbed, body condition is poor, and appetite is reduced. Body temperature is often over 40 °C. The respiratory rate is increased and there is often an abdominal expiratory effort, expiratory grunting and frothing at the mouth, and sometimes mouth breathing. Abnormal lung sounds may be heard on auscultation. Reports describing haemoptysis and epistaxis vary; these symptoms are usually only observed in the terminal stages or not at all (Rebhun et al., 1980; Mills and Pace, 1990). Similar to this report, the affected cattle are often anaemic.

Post mortem findings of cattle with thrombosis of the caudal vena cava are similar. The thrombus occludes over half of or even the entire lumen of the caudal vena cava. If the thrombus is situated cranial to the opening of the hepatic veins or if it occludes this opening, chronic congestion of the liver occurs. Cases of thrombosis of the caudal vena cava with ascites as the main clinical symptom are rare and seldom described in the literature (Stöber, 1966). Experimental research has determined that approximately half of the diameter of the caudal vena cava cranial to the liver must be occluded for marked venous stasis to occur (Adams, 1963). In cattle, complete occlusion of the caudal vena cava at the opening of the hepatic veins rarely causes ascites. This is because collateral circulatory routes via the udder (subcutaneous abdominal veins) and azygous veins develop to ensure venous return. When the udder veins function as an alternative route, the blood returns to the heart via the internal thoracic veins and the cranial vena cava. Nickel et al. (1984) have provided a detailed description of the abdominal venous system. In this report, the udder veins were severely thrombosed by poor intravenous infusion technique and thus, could not provide an alternative route for venous return. It was hypothesized that the blood flow together with emboli from the thrombosed udder veins reached the caudal vena cava via the external iliac veins and the superficial caudal epigastric veins. This hypothesis is supported by the fact that all macroscopic changes in the udder veins, in the thrombosed caudal vena cava, and in the lungs were similar. As well, these changes all had a foul odour characteristic of *A. pyogenes* infection. It is probable that the hypoalbuminaemia contributed to the ascites.

It is not known why an accumulation of emboli and thrombus formation occurred in the subphrenic portion of the caudal vena cava. Perhaps the large blood volume in the caudal vena cava resulted in a slowing of the blood flow caudal to the caval

foramen of the diaphragm; this may have favoured the deposition of septic emboli in the subphrenic region of the caudal vena cava. Damage caused by the massive dilatation of the caudal vena cava may have also favoured thrombus formation in this area.

It is evident from the results of this report that ultrasonography is a useful aid in verifying a clinical diagnosis of ascites and detecting changes in the caudal vena cava in cattle. Obstruction of the caudal vena cava may be presumed when the cross-sectional shape of this vein in the region of the liver is oval rather than triangular, and when its diameter is increased. The finding that the renal vein was dilated supports the suspicion that the kidneys are often enlarged when there are metastatic renal changes or when there is venous stasis attributable to obstruction of the caudal vena cava (Stöber, 1966). In cattle with thrombosis of the caudal vena cava, there are usually no typical clinical signs but rather a number of non-specific symptoms which may or may not occur concomitantly. A clinical diagnosis is therefore difficult, and the condition may only be differentiated from other diseases when the animals have characteristic clinical signs (Stöber, 1966). Thus, ultrasonography appears to be a useful, non-invasive technique in diagnosing thrombosis of the caudal vena cava in cattle.

REFERENCES

Adams O.R. (1963): Hepatic changes resulting from partial ligation of the posterior vena cava in cattle. *Am. J. Vet. Res.* 24, 557–564. — Braun U. (1990): Ultrasonic examination of the liver in cows. *Am. J. Vet. Res.* 51, 1522–1526. — Breeze R. G., Pirie H. M., Selman I. E., Wiseman A. (1976): Hemoptysis in cattle. *Bovine Pract.* 11, 64–72. — Gudmundson J., Radostits O. M., Doige C. E. (1978): Pulmonary thromboembolism in cattle due to thrombosis of the posterior vena cava associated with hepatic abscessation. *Canad. Vet. J.* 19, 304–309. — Ikawa H., Narushima T., Kohno T. (1987): Bacteriology of caudal vena caval thrombosis in slaughter cattle. *Vet. Rec.* 120, 184–186. — Itabisashi T., Yamamoto R., Satoh M. (1987): Ultrasonogram of hepatic abscess in cattle inoculated with *Fusobacterium necrophorum*. *Jpn. J. Vet. Sci.* 49, 585–592. — Jensen R., Pierson R. E., Braddy P. M., Saari D. A., Lauer mann L. H., England J. J., Benitez A., Horton D. J., McChesney A. E. (1976): Embolic pulmonary aneurysms in yearling feedlot cattle. *J. Amer. Vet. Med. Assoc.* 169, 518–520. — Jönsson G., Bergsten C., Carlsten J., Johnsson S., Liberg P. (1988): Ultrasonic diagnosis of liver abscesses in intensively fed beef cattle. In: Proceedings. 15th World Congress of Cattle Diseases, 1428–1430. — Kremer H., Dobrinski W. (1988): Leber. In: *Sonographische Diagnostik*. Eds.: H. Kremer und W. Dobrinski. 3. Auflage, Urban & Schwarzenberg, München, 63–81. — Lechtenberg K. F., Nagaraja T. G. (1991): Hepatic ultrasonography and blood changes in cattle with experimentally induced hepatic

abscesses. *Am. J. Vet. Res.* 52, 803–809. — Letourneau J. G., Day D. L., Ascher N. L., Snover D. C., Steely J. W., Crass J. R., Najarian J. S., Feinberg S. B. (1987): Abdominal sonography after hepatic transplantation: results in 36 patients. *Am. J. Roentgenol.* 149, 299–303. — Mills L. L., Pace L. W. (1990): Caudal vena cava thrombosis in a cow. *J. Amer. Vet. Med. Ass.* 196, 1294–1296. — Nickel R., Schummer A., Seiferle E. (1984): *Lehrbuch der Anatomie der Haustiere*. Band III. Kreislaufsystem, Haut und Hautorgane. Eds.: K.-H. Habermehl, B. Vollmerhaus und H. Wilkens. 2. Auflage, Paul Parey-Verlag, Berlin und Hamburg. — Rehman W. C., Rendano V. T., Dill S. G., King J. M., Pearson E. G. (1980): Caudal vena caval thrombosis in four cattle with acute dyspnea. *J. Amer. Vet. Med. Ass.* 176, 1366–1369. — Rubarth S. (1960): Hepatic and subphrenic abscesses in cattle with rupture into vena cava caudalis. *Acta Vet. Scand.* 1, 363–382. — Selman I. E., Wiseman A., Petrie L., Pirie H. M., Breeze R. G. (1974): A respiratory syndrome in cattle resulting from thrombosis of the posterior vena cava. *Vet. Rec.* 94, 459–466. — Smith J. A. (1990): Vena caval thrombosis and metastatic pneumonia. In: *Large Animal Internal Medicine*. Ed.: B.P. SMITH. C.V. Mosby Company, St. Louis, 594–596. — Stöber M. (1966): Pyogene Thrombosen der Vena cava caudalis beim Rind. *Schweiz. Arch. Tierheilk.* 108, 613–621. — Vollmer K., Allmendinger G., Schmid E. (1990): Sonographischer Nachweis venöser Thrombosen im Abdominalraum. *Schweiz. Rundschau Med. (PRAXIS)* 4, 67–68.

Ultrasonographie d'une vache présentant un ascite consécutif à une thrombose de la vena cava caudalis

Une vache de race brune de trois ans était atteinte d'un ascite suite à une thrombose de la vena cava caudalis. La suspicion clinique d'ascite fut confirmée par l'examen ultrasonographique de l'abdomen. Outre une accumulation massive de liquide, on put mettre en évidence une dilatation de la partie abdominale de la vena cava caudalis (4,8 cm). Ces constatations permettent de conclure à une occlusion de la partie craniale de la vena cava caudalis par un thrombus ou une compression extérieure.

L'abattage permit de mettre en évidence une accumulation massive de liquide dans l'abdomen, ainsi qu'un thrombus d'une longueur de 15 cm dans la partie subphrénique de la vena cava caudalis. Les poumons étaient affectés de multiples abcès et d'une thrombose sévère des vaisseaux. Le foie était congestionné et les plis de la caillette fortement oedémateux. En outre, la vache présentait de graves thrombophlébites de la veine jugulaire gauche et des deux veines du lait, dues à des injections intraveineuses incorrectes.

Vu la circulation collatérale bien développée (notamment par les veines du lait), un ascite suite à un thrombus de la veine cave caudale est extrêmement rare. On peut donc supposer que la thrombose massive des deux veines du lait a contribué

ULTRASONOGRAPHIC FINDINGS IN A COW WITH ASCITES

pour une grande part au développement de cette image clinique.

Risultati ultrasonografici in una mucca con ascite dovuta alla trombosi della vena cava caudale

Viene descritta una mucca di tre anni, avente una ascite, a causa di una trombosi della vena cava caudale. Il sospetto dell'ascite venne confermato con l'aiuto dell'indagine ultrasonografica dell'addome. Insieme al grave accumulo di liquidi si poté constatare una chiara dilatazione della parte addominale della vena cava caudale (4,8 cm). Questi risultati lasciarono presupporre che il lume della vena cava caudale doveva essere ridotto nella parte craniale, da un trombo o da una compressione esterna. Dopo il macello, si constatò nell'addome oltre all'accumulo di liquidi, anche un trombo nella vena cava caudale sottostante il diaframma. Nei polmoni si riscontrarono molteplici ascessi e una grave trombosi dei

vasi sanguigni polmonari. Il fegato appariva congestionato. Le pieghe dell'abomaso erano edematose. La mucca inoltre aveva delle gravi tromboflebiti dovute alle iniezioni, nella vena giugulare sinistra e in tutte e due le vene mammarie. Dal momento che è rara una ascite dovuta a una trombosi della vena cava caudale, causata da più vene collaterali in direzione del cuore, si presume che sia la trombosi delle due vene mammarie ad aver causato la formazione dell'ascite, suffragato dal fatto che anche una parte importante dei collaterali delle vene mammarie era interrotta.

Adresse: Ueli Braun, Prof. Dr. med. vet.
Veterinär-Medizinische Klinik
der Universität Zürich
Winterthurerstrasse 260
CH-8057 Zürich

Manuskripteingang: 13. August 1991

Jetzt mit dem ersten PC-gesteuerten Röntgen-Generator der Welt

Mit Fr. 19.- sind Sie dabei: (Basis 500 A/Jahr)
Mit unserem **neuen Röntgen-Vertriebs-System** berappen Sie **nachträglich** nur die ausgeführten Expositionen zu Fr. 19.-. Interessiert Sie diese risikofreie Beschaffung einer Röntgeneinrichtung, mit Service und **Vollgarantie**?

Bitte verlangen Sie unverbindlich unser Angebot für eine betriebsbereite, komplette Röntgenanlage mit Dunkelkammereinrichtung.

Vorteile: keine Kapitalinvestition; Vollgarantie während der Vertragsdauer. Nach 5 Jahren sind Sie Besitzer der kompletten Röntgeneinrichtung.

Revidierte Occasions-Röntgenanlage,
500 mA, 125 kV. Buckystand, fahrbarer Tisch, Fr. 22 000.-.

R. Liehti AG, Röntgen, 2075 Thielle, Tel. 032 88 21 27

NEU!

