

Zeitschrift: Schweizer Archiv für Tierheilkunde SAT : die Fachzeitschrift für Tierärztinnen und Tierärzte = Archives Suisses de Médecine Vétérinaire
ASMV : la revue professionnelle des vétérinaires

Herausgeber: Gesellschaft Schweizer Tierärztinnen und Tierärzte

Band: 137 (1995)

Heft: 5

Artikel: Echocardiographic diagnosis of a cardiac fibrosarcoma in the right atrium of a sheep

Autor: Braun, U. / Hagen, A. / Pusterla, N.

DOI: <https://doi.org/10.5169/seals-591828>

Nutzungsbedingungen

Die ETH-Bibliothek ist die Anbieterin der digitalisierten Zeitschriften auf E-Periodica. Sie besitzt keine Urheberrechte an den Zeitschriften und ist nicht verantwortlich für deren Inhalte. Die Rechte liegen in der Regel bei den Herausgebern beziehungsweise den externen Rechteinhabern. Das Veröffentlichen von Bildern in Print- und Online-Publikationen sowie auf Social Media-Kanälen oder Webseiten ist nur mit vorheriger Genehmigung der Rechteinhaber erlaubt. [Mehr erfahren](#)

Conditions d'utilisation

L'ETH Library est le fournisseur des revues numérisées. Elle ne détient aucun droit d'auteur sur les revues et n'est pas responsable de leur contenu. En règle générale, les droits sont détenus par les éditeurs ou les détenteurs de droits externes. La reproduction d'images dans des publications imprimées ou en ligne ainsi que sur des canaux de médias sociaux ou des sites web n'est autorisée qu'avec l'accord préalable des détenteurs des droits. [En savoir plus](#)

Terms of use

The ETH Library is the provider of the digitised journals. It does not own any copyrights to the journals and is not responsible for their content. The rights usually lie with the publishers or the external rights holders. Publishing images in print and online publications, as well as on social media channels or websites, is only permitted with the prior consent of the rights holders. [Find out more](#)

Download PDF: 07.02.2026

ETH-Bibliothek Zürich, E-Periodica, <https://www.e-periodica.ch>

Echocardiographic diagnosis of a cardiac fibrosarcoma in the right atrium of a sheep

U. Braun¹, A. Hagen¹, N. Pusterla¹, P. Caplazi²

Summary

This is a case report of a six-year-old female White Alpine sheep with a cardiac fibrosarcoma in the right atrium. Clinically, the sheep had right-sided cardiac insufficiency with tachycardia, engorgement of the jugular veins, brisket edema, and ascites. Chronic congestion of the liver resulted in increased hepatic enzyme activity. Based on clinical findings, a tentative diagnosis of endocarditis or pericarditis was made. Radiography of the thorax revealed hydrothorax. An echogenic mass was observed in the right atrium via echocardiography; it was interpreted as a tumor or thrombus. Ultrasonography of the abdomen revealed severe ascites and chronic congestion of the liver attributable to right-sided cardiac insufficiency. The clinical and sonographic findings were verified at *post mortem*. The mass in the right atrium was a pedunculated fibrosarcoma.

Key words: tumor – fibrosarcoma – heart – ascites – sheep

Echokardiographische Diagnose eines Fibrosarkoms im rechten Herzvorhof eines Schafes

Es wird ein 6 Jahre altes weibliches Weisses Alpenschaf mit einem Fibrosarkom im rechten Herzvorhof beschrieben. Klinisch wies das Tier eine Rechtsherzinsuffizienz mit Tachykardie, gestauten Jugularvenen, einem Trielödem und einem Aszites auf. Die Aktivitäten der Leberenzyme waren infolge der chronischen Leberstauung erhöht. Auf Grund der klinischen Befunde bestand Verdacht auf eine Perikarditis oder auf eine Endokarditis. Zur weiteren Abklärung wurden eine Röntgenuntersuchung des Thorax und eine Ultraschalluntersuchung von Herz und Abdomen durchgeführt. Bei der Röntgenuntersuchung wurde ein Hydrothorax festgestellt. Echokardiographisch wurde im rechten Herzvorhof eine echo-gene Masse, die als Tumor oder Thrombus angesprochen wurde, diagnostiziert. Die Ultraschalluntersuchung des Abdomens ergab als Folge der Rechtsherzinsuffizienz einen hochgradigen Aszites mit chronischer Leberstauung. Bei der Sektion wurden die klinischen und sonographischen Befunde bestätigt. Der im rechten Herzvorhof gelegene Tumor erwies sich als gestieltes Fibrosarkom.

Schlüsselwörter: Herztumor – Fibrosarkom – Aszites – Schaf

Meinem verehrten Lehrer, Herrn Prof. Dr. Dr. h.c. mult. Werner Leidl,
mit den besten Glückwünschen zum 70. Geburtstag

Introduction

Cardiac tumors can be primary or secondary and are a rare cause of disease in animals and in human beings. A description of cardiac tumors in human beings has been reported by Hall et al. (1990) and Colucci and Braunwald (1992). Cardiac tumors in animals have been detailed by Fox and Nichols (1988), Blood and Radostits (1990), McGuirk et al. (1990), and Robinson and Maxie (1993). Cardiac tumors may involve the pericardium, myocardium or endocardium and may be intracavitary in the left or right atrium or ventricle. Clinical symptoms depend predominantly on the size and anatomical location of the tumor and subordinately on its histological nature. Tumors in the myocardium often cause disturbances in cardiac rhythm and in conduction, which can be verified by electrocardiography. Depending on their size and location, such intramural tumors can impair ventricular function resulting in congestive, restrictive or hypertrophic cardiomyopathy. Intracavitary tumors may cause cavitory obliteration, valvular stenosis or cardiac insufficiency. Large tumors in the right atrium usually are accompanied by symptoms of right-sided cardiac insufficiency which include increased venous blood pressure, venous congestion, peripheral edema, ascites, and hepatomegaly. The sinus rhythm and ECG are usually normal with intracavitary tumors. The oscillating movement of a pedunculated tumor in the right atrium may impair the function of the tricuspid valve resulting in cardiac insufficiency. In such cases, a systolic or diastolic cardiac murmur may be auscultated.

Echocardiographic examination in normal sheep has been described (Moses and Ross, 1987; Kirberger and van den Berg, 1993). But, to our knowledge, there has been no report of a cardiac tumor diagnosed intra vitam in a sheep. This case report describes a six-year-old female White Alpine sheep with a fibrosarcoma in the right cardiac atrium. The sheep had given birth to healthy twin lambs seven weeks prior to examination. No abnormalities were noted at birth or during the puerperal period. Six weeks after lambing, the sheep had a severely reduced feed intake and was often recumbent. The owner noted that the sheep had a swollen brisket. The referring veterinarian administered antibiotics and an anthelmintic agent; however, there was no improvement in her condition, and one week later, the sheep was referred to our clinic.

Clinical findings

The general condition and behaviour of the sheep were moderately disturbed. The sheep was emaciated and had severe brisket edema and bilateral engorgement of the jugular veins (Fig. 1). In addition, the ventral abdomen was symmetrically dilated. The heart rate was increased (152 beats per minute) with pounding heart beats; cardiac rhythm was normal. The cardiac sounds were distinct, and no heart murmur was auscultated. Peripheral

body temperature was decreased, and ruminal and intestinal motility were reduced. All other clinical findings were normal. Based on clinical findings, a tentative diagnosis of right-sided cardiac insufficiency was made. Dilatation of the ventral abdomen indicated ascites. Endocarditis or pericarditis was thought to be the likely cause of the right-sided cardiac insufficiency. In addition to a complete blood count and a biochemical profile, radiographic examination of the thorax and ultrasonographic examination of the heart and abdomen were performed to aid in the diagnosis.




Fig. 1: Emaciated female White Alpine sheep with brisket edema and dilated ventral abdomen. The sheep had a cardiac tumor which resulted in right-side cardiac insufficiency and ascites.

Laboratory findings

Activities of liver enzymes were moderately to severely increased; the activity of GLDH, γ -GT, and SDH were 146 U/l, 105 U/l, and 294 U/l, respectively. Serum urea concentration was distinctly increased (19.4 mmol/l), and the hematocrit was slightly increased (44%). The concentrations of plasma protein and albumin were normal (66 and 25 g/l, respectively). The concentration of fibrinogen was decreased (2 g/l). Venous blood gas analysis revealed metabolic acidosis; blood pH was 7.26, bicarbonate was 17.2 mmol/l, pCO₂ was 35.6 mmHg, and there was a base excess of -8.2 mmol/l.

Radiographic and ultrasonographic examinations

Radiographic examination of the thorax revealed extensive pleural effusion. Echocardiographic examination was performed over the thorax with the sheep in right lateral recumbency and using a 5.0 MHz sector transducer. An echogenic round mass with a diameter of approximately 4 cm was observed in the right atrium immediately above the tricuspid valve (Fig. 2). It moved freely, had a smooth surface, and did not appear to be attached to the endocardium. Mild pericardial effusion and distinct dilatation of the right atrium and ventricle also were seen.

Ultrasonographic examination of the abdomen using a 3.5 MHz convex transducer revealed severe ascites. The reticulum, liver, omasum, right kidney, and loops of small intestine, which normally are situated immediately adjacent to the abdominal wall, were surrounded by a wide border of anechoic fluid (Fig. 3 and 4). The contour of the reticulum was smooth and had no abnormalities. The liver parenchyma appeared echogenic and coarse. The caudal vena cava was dilated and was not triangular in cross section, as seen in healthy sheep (Braun and Hausmann, 1992), but instead round (Fig. 5). The wall of the gallbladder and the wall of the small intestine were thickened, probably due to edema.

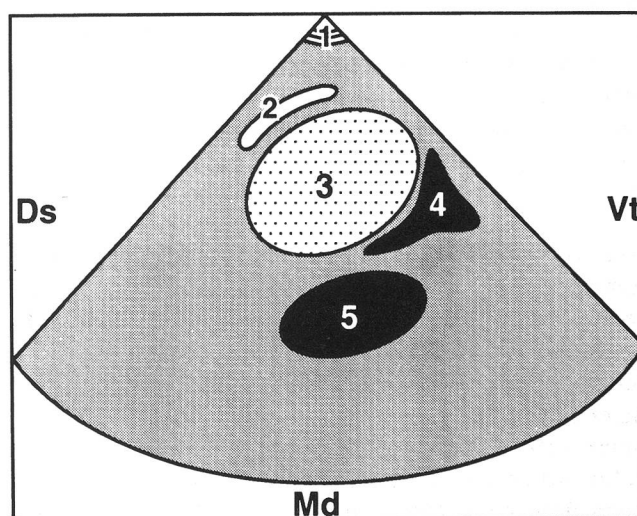
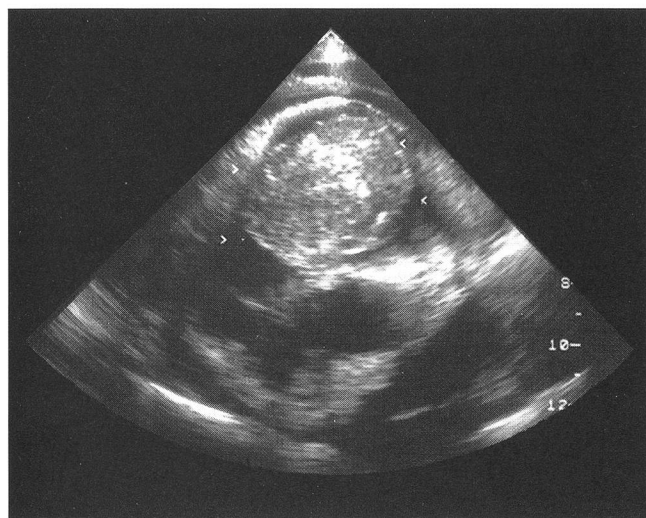

Fig. 2: Ultrasonogram (A) and schematic representation (B) of a fibrosarcoma in the right cardiac atrium of a sheep. 1 = thoracic wall; 2 = wall of the right atrium; 3 = tumor in the right atrium; 4 = blood in the right atrium; 5 = aorta; Ds = dorsal; Vt = ventral; Md = medial.

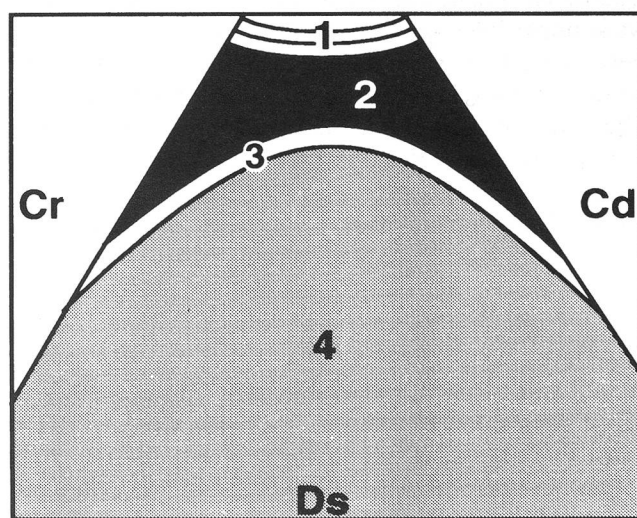
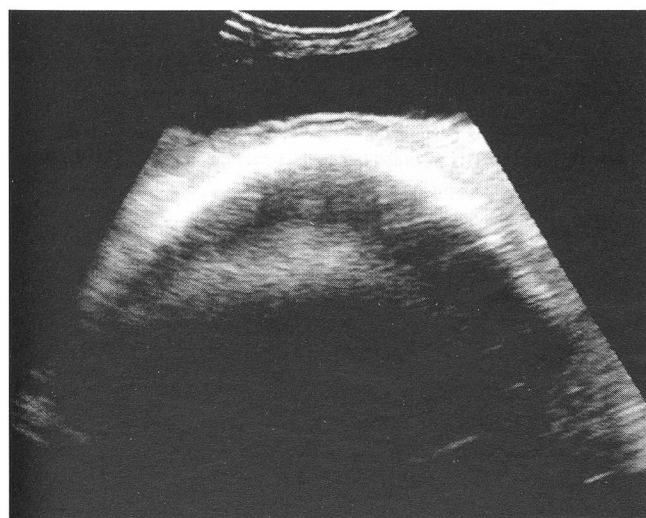


Fig. 3: Ultrasonogram (A) and schematic representation (B) of the reticulum and accumulation of fluid (ascites) in the abdomen of a sheep with right-sided cardiac insufficiency due to a fibrosarcoma in the right atrium. The reticulum is displaced from the peritoneum and is surrounded by ascitic fluid. 1 = ventral abdominal wall; 2 = ascitic fluid; 3 = reticular wall; 4 = reticulum. Cr = cranial; Cd = caudal; Ds = dorsal.

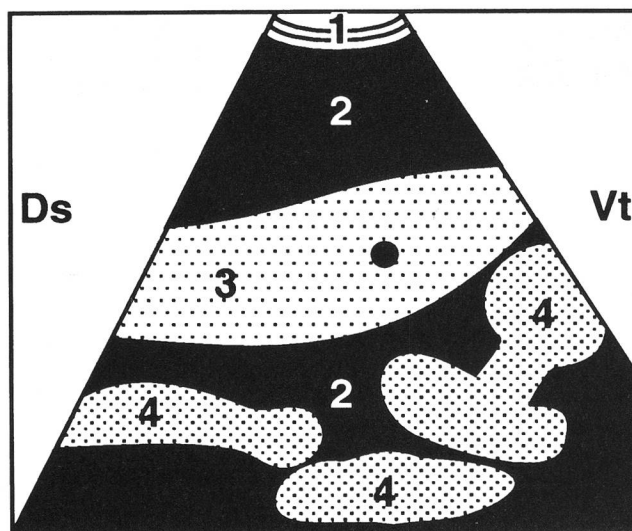
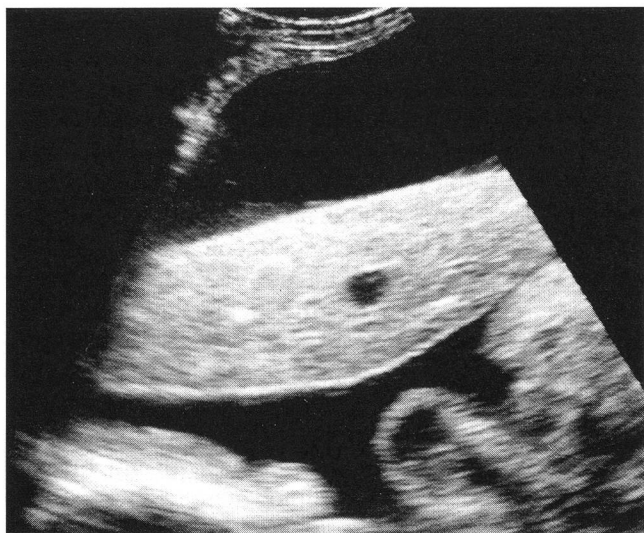

Fig. 4: Ultrasonogram (A) and schematic representation (B) of the liver, loops of small intestine, and accumulation of fluid (ascites) in a sheep with right-sided cardiac insufficiency due to a fibrosarcoma in the right atrium. The liver and loops of small intestine are surrounded by ascitic fluid. The liver parenchyma is more echogenic and coarser than normal. 1 = abdominal wall; 2 = ascitic fluid; 3 = liver; 4 = intestine. See Fig. 2 for key.

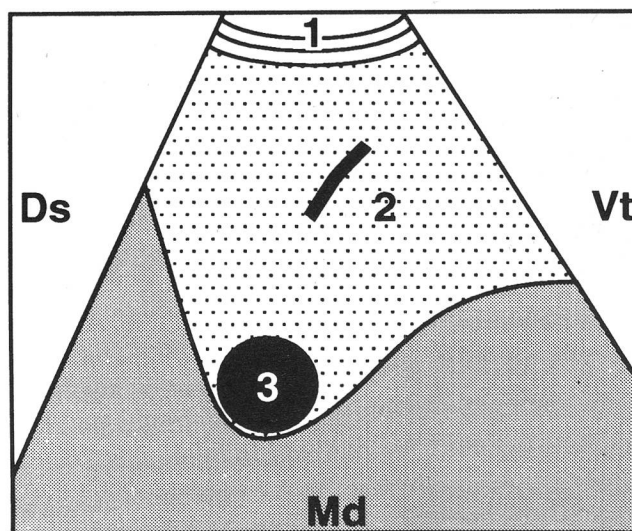
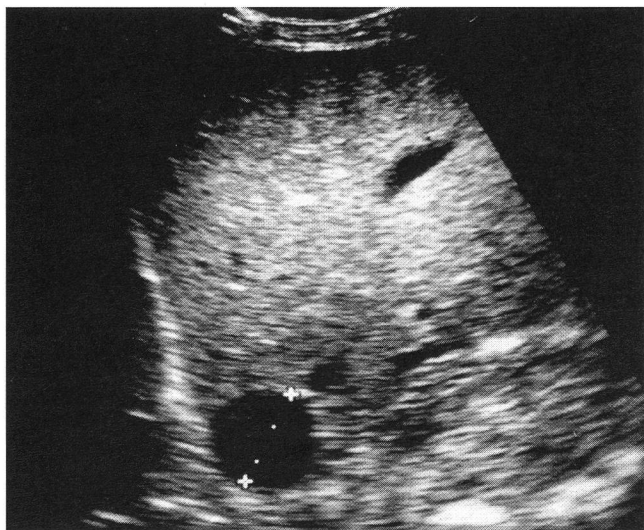


Fig. 5: Ultrasonogram (A) and schematic representation (B) of the liver and caudal vena cava in a sheep with right-sided cardiac insufficiency due to a fibrosarcoma in the right atrium. Due to congestion, the caudal vena cava appears round on cross section. 1 = abdominal wall; 2 = liver texture; 3 = caudal vena cava. See Fig. 2 for key.

Diagnosis

Based on the clinical and sonographic findings, a diagnosis of right-sided cardiac insufficiency was made. The cause was thought to be a tumor or thrombus in the right atrium. Pericarditis was ruled-out. There was no sonographic evidence of endocarditis. The ascites was thought to be attributable to right-sided cardiac insufficiency. Because of the unfavorable prognosis, the sheep was euthanatized and a *post mortem* examination was performed.

Post mortem findings

The heart was enlarged; the right atrium and right ventricle were severely dilated, and there was slight hypertrophy of the myocardium of the left ventricle. There was a firm, pedunculated, ovoid mass measuring 6 cm × 4 cm × 3 cm, that protruded from the myocardium immediately above the tricuspid valve into the right atrium and ventricle (Fig. 6). The mass was covered by smooth shiny endothelium, and the soft cut surface was cream colored and had a dark red mottled appearance. Histo-

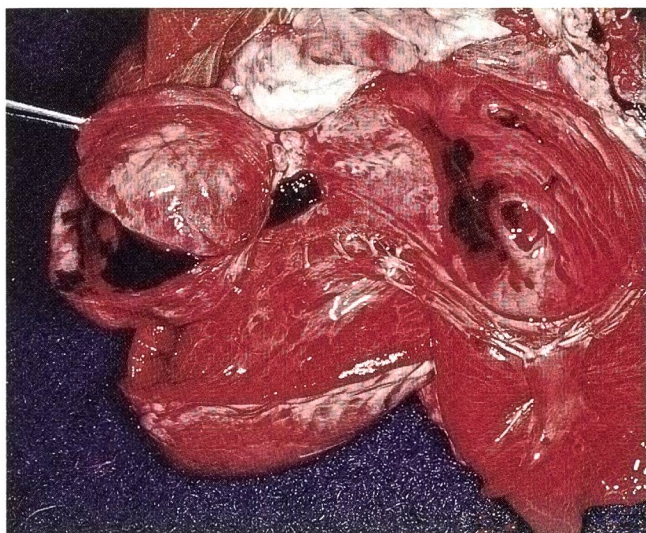


Fig. 6: A fibrosarcoma in the right atrium of a White Alpine sheep. The heart and the fibrosarcoma have been opened; the latter is held open with a pair of forceps.

logical examination identified the mass as a fibrosarcoma. It had a predominantly solid architecture, although there were spongy areas, and it was composed of tightly packed, pleomorphic cells with indistinct cell margins and eosinophilic cytoplasm. The nuclei were large, polymorphic, euchromatic, and often oval or elongated with

clumped chromatin. The nucleoli were often difficult to identify and small; occasionally, there were two or three nucleoli per nucleus. Mitotic activity was low. Immunohistochemically, the neoplastic cells were desmine-negative, Factor VII-related antigen-negative, S-100-negative and vimentin-positive.

Other pathological findings included subcutaneous edema in the brisket and ventral aspects of the body, 2.0 liters of thoracic transudate, 0.2 liters of pericardial transudate, 6.5 liters of abdominal transudate, chronic hepatic congestion, and severe interstitial and alveolar edema in the lungs.

Discussion

Brisket edema, congestion of the jugular veins, and ascites are typical symptoms of right-sided cardiac insufficiency or pericardial effusion. Possible causes which must be considered include cardiac diseases such as pericarditis, myocarditis or endocarditis, cardiomyopathy, and cardiac leukosis. The differential diagnosis should include obstruction of the cranial vena cava by a thrombus or by compression from a mediastinal mass. Clinical differentiation between the possible causes was not possible. Electrocardiographic and phonographic examinations were not performed because no abnormalities in cardiac rhythm or tone were auscultated. Echocardi-

Diagnostique échocardiographique d'un fibrosarcome dans l'atrium droit du cœur d'un mouton

Le cas d'une brebis âgée de 6 ans de la rasse Blanc des Alpes avec un fibrosarcome dans l'atrium droit du cœur est décrit. L'examen clinique a révélé une insuffisance cardiaque à droite avec tachycardie, une stase des veines jugulaires, un œdème du fanon et un ascite. Les activités des enzymes du foie étaient élevées à la suite de la stase hépatique chronique. Sur la base des examens cliniques, une péricardite et une endocardite ont été suspectées. Afin d'éclaircir ce point, un examen radiographique du thorax et un examen par ultrasons du cœur et de l'abdomen ont été effectués. Au cours de l'examen radiographique, un hydrothorax a été identifié. L'examen échocardiographique a révélé une masse échogène interprétée comme étant une tumeur ou un thrombus. L'examen par ultrasons de l'abdomen a identifié un ascite prononcé avec stase hépatique chronique, une conséquence de l'insuffisance cardiaque à droite. A l'autopsie, les observations cliniques et sonographiques ont été confirmées. La tumeur présente dans l'atrium droit était un fibrosarcome pédonculé.

Diagnosi ecocardiografica di un fibrosarcoma nell'atrio destro del cuore di una pecora

Viene descritto un caso di una pecora bianca di 6 anni affetta da un fibrosarcoma dell'atrio destro del cuore. I sintomi clinici riscontrati erano un'insufficienza cardiaca destra con tachicardia, vene jugulari congestionate, un edema del petto et un ascite. L'attività degli enzimi del fegato era maggiorata a causa della congestione cronica del fegato. Sulla base dei sintomi clinici veniva sospettata una pericardite o una endocardite. Al fine di ottenere maggiori informazioni, furono effettuate delle radiografie del torace ed un'ecografia del cuore e dell'addome. Dalla radiografia si è potuto constatare un idrotorace. Dall'ecografia si è potuto diagnosticare una massa nell'atrio destro del cuore, che fu riconosciuta come tumore o trombo. L'analisi ecografica dell'addome lasciava trasparire un grave ascite con congestione cronica del fegato in conseguenza all'insufficienza cardiaca destra. Durante la sezione dell'animale furono confermati i referti clinici ottenuti mediante ecografia. Il tumore presente nell'atrio destro del cuore è risultato essere un fibrosarcoma allungato.

graphic examination revealed an obstructing mass in the right atrium. It was assumed to be a tumor or thrombus causing signs of congestion throughout the systemic circulation that included engorgement of the jugular veins, brisket edema, and ascites. It was interesting to note that congestion of the caudal vena cava in sheep resulted in a change in the cross-sectional shape of the vein on ultrasonograms; this also has been reported in cattle. In both species, the healthy caudal vena cava is characteristically triangular on cross section on ultrasonograms because it is embedded in the *sulcus venae cavae* in the liver parenchyma (Braun, 1990; Braun and Hausammann, 1992). The most important criterion for diagnosis of dilatation of the caudal vena cava is not an increase in the diameter of the vein, but rather a change in the cross-sectional shape from triangular to round or oval on ultrasonograms (Braun et al., 1992).

The increased activities of the hepatic enzymes were attributable to congestion of the liver. The decreased concentration of plasma fibrinogen also was a result of severely disturbed liver function with impaired production of fibrinogen.

Post mortem examination verified the tentative diagnosis of a tumor and revealed a fibrosarcoma in the right atrium of the heart. In human beings, 75% of cardiac tumors are benign. The most commonly occurring are myxomas, followed by numerous other benign tumors such as lipomas, rhabdomyomas, fibromas, and hemangiomas (Hall et al., 1990; Colucci and Braunwald, 1992). Sarcomas predominate among malignant cardiac tumors; they occur in decreasing frequency in the right and left atria, in the right and left ventricles, and in the interventricular septum. Sarcomas are of mesenchymal origin and therefore have numerous morphological forms such as angiosarcoma, rhabdomyosarcoma, and fibrosarcoma (Colucci and Braunwald, 1992). Twenty per cent of sarcomas are pedunculated or polypoid. Sarcomas typically have a fast rate of growth. Death usually occurs within a few weeks to two years of the onset of clinical symptoms. Of human beings with cardiac sarcomas, 75% have metastases at death. Cardiac lymphosarcoma predominates among tumors of the heart in cattle and in horses (Blood and Radostits, 1990). In these species, there also are reports of hemangiosarcoma, metastasized carcinoma, and other tumors in the heart such as neurofibroma in cattle (Blood and Radostits, 1990; Robinson and Maxie, 1993). In dogs, the most common primary tumor of the heart is hemangiosarcoma (Fox and Nichols, 1988).

Before 1960, *ante mortem* diagnosis of cardiac tumors in human beings was rarely possible (Hall et al., 1990; Colucci and Braunwald, 1992). Today, two-dimensional echocardiography is the most important method of diagnosing heart tumors because of its high sensitivity. The size, location, and mobility of a cardiac tumor can be determined by use of echocardiography. Radiographically determined changes in cardiac contour and size, specific enlargement of the cardiac chambers, changes in the pulmonary vascularization, and intracardial calcification may indicate a cardiac tumor. The advantage of computer tomography in the diagnosis of cardiac tumors is its high degree of tissue discrimination and thus to identify intramural tumors and their dimensions.

To our knowledge, there have been no reports of ultrasonographic examination of heart tumors in sheep. The results of this paper indicate that ultrasonography is an ideal method of diagnosing right-sided heart insufficiency in sheep. Ultrasonography of the abdomen also clearly revealed the severe manifestations of congestion of the caudal vena cava.

References

- Blood D.C., Radostits O.M. (1990): Cardiac neoplasia. In: Veterinary Medicine. A Textbook of the Diseases of Cattle, Sheep, Pigs, Goats and Horses, 7th ed. Baillière Tindall, London, 333.
- Braun U. (1990): Ultrasonographic examination of the liver in cows. *Am.J.Vet.Res.*, 51, 1522-1526.
- Braun U., Hausammann K. (1992): Ultrasonographic examination of the liver in sheep. *Am.J.Vet.Res.*, 53, 198-202.
- Braun U., Schefer U., Gerber D., Föhn J. (1992): Ultrasonographic findings in a cow with ascites due to thrombosis of the caudal vena cava. *Schweiz.Arch.Tierheilk.*, 134, 235-241.
- Colucci W.S., Braunwald E. (1992): Primary tumors of the heart. In: Heart Disease. A Textbook of Cardiovascular Medicine, 4th ed. E. Braunwald, Ed., W.B. Saunders Company, Philadelphia, 1451-1462.
- Fox P.R., Nichols C.E.R. (1988): Neoplasia. In: Canine and Feline Cardiology. P.R. Fox, Ed., Churchill Livingstone, New York, Edinburgh, London, Melbourne, 579-580.
- Hall R.J., Cooley D.A., McAllister H.A., Frazier O.H. (1990): Neoplastic heart disease. In: The Heart, 7th ed. J.W. Hurst, R.C. Scblant, C.E. Rackley, E.H. Sonnenblick, N.K. Wenger, Eds., McGraw-Hill, New York, 1382-1403.
- McGuirk S.M., Sbaftoe S., Lunn D.P. (1990): Cardiac tumors. In: Large Animal Internal Medicine. B.P. Smith, Ed., The C.V. Mosby Company, St. Louis, 481-483.
- Robinson W.F., Maxie M.G. (1993): Neoplasms of the heart. In: Pathology of Domestic Animals, 4th ed, Vol. 3. K.V.F. Jubb, P.C. Kennedy, N. Palmer, Eds., Academic Press, Inc., San Diego, 45-48.

Address of the authors: Ueli Braun, Klinik für Wiederkäuer- und Pferdemedizin, Winterthurerstrasse 260, CH-8057 Zürich

Manuskripteingang: 2. März 1994