Zeitschrift: Schweizer Archiv für Tierheilkunde SAT : die Fachzeitschrift für Tierärztinnen und Tierärzte = Archives Suisses de Médecine Vétérinaire ASMV : la revue professionnelle des vétérinaires

Herausgeber: Gesellschaft Schweizer Tierärztinnen und Tierärzte

Band: 136 (1994)

Heft: 4

Artikel: The long-term influence of biotin supplementation on hoof horn quality in horses

Autor: Geyer, H. / Schulze, J.

DOI: https://doi.org/10.5169/seals-590989

Nutzungsbedingungen

Die ETH-Bibliothek ist die Anbieterin der digitalisierten Zeitschriften auf E-Periodica. Sie besitzt keine Urheberrechte an den Zeitschriften und ist nicht verantwortlich für deren Inhalte. Die Rechte liegen in der Regel bei den Herausgebern beziehungsweise den externen Rechteinhabern. Das Veröffentlichen von Bildern in Print- und Online-Publikationen sowie auf Social Media-Kanälen oder Webseiten ist nur mit vorheriger Genehmigung der Rechteinhaber erlaubt. Mehr erfahren

Conditions d'utilisation

L'ETH Library est le fournisseur des revues numérisées. Elle ne détient aucun droit d'auteur sur les revues et n'est pas responsable de leur contenu. En règle générale, les droits sont détenus par les éditeurs ou les détenteurs de droits externes. La reproduction d'images dans des publications imprimées ou en ligne ainsi que sur des canaux de médias sociaux ou des sites web n'est autorisée qu'avec l'accord préalable des détenteurs des droits. En savoir plus

Terms of use

The ETH Library is the provider of the digitised journals. It does not own any copyrights to the journals and is not responsible for their content. The rights usually lie with the publishers or the external rights holders. Publishing images in print and online publications, as well as on social media channels or websites, is only permitted with the prior consent of the rights holders. Find out more

Download PDF: 25.11.2025

ETH-Bibliothek Zürich, E-Periodica, https://www.e-periodica.ch

Institute of Veterinary Anatomy, University of Zürich[1], and F. Hoffmann-La Roche AG, Basel, Division of Vitamin and Nutrition Research[2]

The long-term influence of biotin supplementation on hoof horn quality in horses*

H. Geyer[1] and J. Schulze[2]

Summary

The influence of dietary biotin in horses with brittle hoof horn and chipped hooves was investigated in a long-term study, which was performed over a period from one to six years. 97 horses received 5 mg of biotin per 100 to 150 kg of body weight, per os, daily; 11 horses were not supplemented with biotin and served as controls. The hooves of all horses were evaluated macroscopically every three to four months. Hoof horn specimens of the proximal wall were examined histologically and physically in 25 and 15 horses, respectively. The tensile strength of normal coronary horn was 60 N/mm^2 or greater; it was reduced in areas of histological alterations, the lowest value being 20 N/mm^2.
The hoof horn condition of the biotin-supplemented horses improved after eight to 15 months of supplementation as determined by macroscopic and histologic examinations. The hoof horn condition of most control horses remained constant throughtout the study. The growth rate of the coronary horn of horses supplemented with biotin and of control horses was the same.
The hoof horn condition deteriorated in 7 of 10 horses after biotin supplementation was reduced or terminated. It was concluded that biotin should be continuously supplemented at the full dosage in horses with severe hoof horn alterations.

Key words: **hoof – horn-quality – biotin – horse**

Langzeituntersuchungen über den Einfluss von Biotin auf die Hufhornqualität des Pferdes

An Pferden mit bröckeligem Hufhorn und Tragrandausbrüchen wurde der Einfluss von Biotin auf die Hufhornqualität in einem Zeitraum von 1–6 Jahren untersucht. 97 Pferde erhielten täglich 5 mg Biotin pro 100–150 kg Körpergewicht per os; 11 Pferde wurden nicht behandelt und dienten als Kontrolle. Der Hufstatus aller Pferde wurde makroskopisch-klinisch alle 3–4 Monate bewertet. Zur Beurteilung der Hornqualität wurden bei 25 Pferden Proben aus dem proximalen Teil der Hornwand entnommen und histologisch untersucht sowie bei 15 Pferden auch auf Zugfestigkeit geprüft. Die Zugfestigkeit von unverändertem Kronhorn betrug 60 N/mm^2 oder mehr; in Bereichen von histologischen Veränderungen war die Zugfestigkeit vermindert, wobei der niedrigste Wert nur 20 N/mm^2 betrug.
Auf Grund der makroskopischen und histologischen Beurteilung verbesserte sich der Hufstatus der mit Biotin supplementierten Pferde nach einer Behandlungsdauer von 8–15 Monaten. Der Hufstatus der unbehandelten Kontrolltiere blieb während der Versuchsdauer weitgehend konstant. Die Wachstumsrate des Kronhorns war bei behandelten und unbehandelten Pferden gleich. Nach Verminderung der Biotindosis oder Beendigung der Behandlung verschlechterte sich der Hufstatus bei 7 von 10 Pferden. Für Pferde mit schweren Hufhornveränderungen wird daher eine Dauerbehandlung mit der vollen Dosis Biotin empfohlen.

Schlüsselwörter: **Huf – Hornqualität – Biotin – Pferd**

* Dedicated to Prof. Dr. J. Frewein on the occasion of his 60. birthday

Introduction

The proverb «no hoof - no horse» is well-known; the fact that many horses have hooves with poor horn quality is less well-known. Crumbly friable horn and chipped areas in the hoof wall are frequently seen. The anatomy and function of the equine hoof have been investigated by various authors e.g. Nickel (1938), Ziegler (1951), Leach and Oliphant (1983), Geyer et al. (1988), Budras et al. (1989), Bolliger (1991). However, information concerning the structure and function of the equine hoof and hoof horn quality is still insufficient. In horses with poor quality hoof horn, damage to the horn can have serious consequences; shoeing may be impossible, thus incapacitating the horse for work.

Supplementation with biotin has been reported to have a beneficial effect on hoof horn quality not only in pigs (Brooks et al., 1977; Triebel and Lobsiger, 1979; Brooks and Simmins, 1980; Penny et al., 1980; de Jong and Sytsema, 1983; Webb et al., 1984; Bryant et al., 1985) but also in horses (Comben et al., 1984; Wintzer, 1986; Leu, 1987). The goal of this study was to investigate the effect of long-term biotin supplementation on the quality and growth of hoof horn in horses. The following paper represents a synopsis of the thesis of Leu (1987)[1] and subsequent investigations. Details concerning materials and methods as well as results can be seen in the original version of the thesis. The thesis of Leu was supervised by H. Geyer, who also performed the subsequent studies. In addition, the effect of biotin supplementation in horses with hoof horn problems was assessed in a field trial by J. Schulze.

Animals, materials and methods

The influence of biotin on hoof horn quality was investigated in 100 horses that were supplemented with biotin and in 10 horses, that were untreated and served as controls. The horses were divided into different groups as described in table 1.

The horses of groups A, B, and C belonged to three different stables (A, B, C). In each group horses supplemented with biotin and control horses were stabled and worked similarly. The assignment to the subgroups «biotin» or «control» was performed using the degree of hoof alteration as a criterium. It was attempted to have horses with poor and better hoof horn condition equally represented in both subgroups. Groups D and E consisted of horses from various stables, which were reported to suffer from poor hoof horn quality. They were supplemented with biotin.

The feed-regimen included mainly hay and oats and was identical for supplemented animals and controls. In supplemented horses biotin-therapy was the only variable, while feeding, housing, work and regular hoof-care were maintained throughout.

Table 1: Groups and breeds of control horses and of horses supplemented with biotin

Group	Breed	Biotin supplementation	Untreated controls	Time of supplementation and observation
A	Belgian Hanoverian	4 1	5* 1	3-6 years 5-6 years
B	Shires	3	2	8 months 11 months observation
C	Icelandic ponies	2	3	15 months
D	various breeds 10 of which were warmbloods	15	-	1-5 years 8 horses: more than 2 years
E	various breeds 60 of which were warmbloods	70	-	more than 1 year

* Of 5 horses 2 horses were untreated for 3-3½ years. After this time they were supplemented with biotin so that a total of 6 Belgians received biotin.

The concentration of *plasma biotin* was measured before and after the start of biotin supplementation in each horse, as described by Frigg and Brubacher (1976). During the study, the concentration of plasma biotin was periodically measured using the same method to ensure correct dosage.

The horses supplemented with biotin received 5 mg of biotin/100-150 kg body weight, per os, daily. The standard dose for a 500-600 kg warmblood horse was 20 mg of biotin per day. The biotin tablets were administered in a piece of apple to horses in groups A and B, twice daily; horses in groups C, D, and E received the biotin tablets once daily. After three and two years of biotin treatment, respectively, the dosage of biotin was reduced to 25% of the initial dose in five horses in group A and in four horses in group D.

The *growth rate* of the coronary horn was measured at the dorsal, lateral and palmar wall (Fig. 1) in groups A, B, and C and in most horses of group D. Grooves were placed 2-3 cm beneath and parallel to the coronary border by use of a drilling machine. The distance from the coronary border to the grooves was measured in the direction of the tubules as depicted in Figure 1. During the first year, the growth rates were measured in all four hooves of each horse in groups A, B, and C. Subsequently the measurements were limited to the left fore and the right hind hooves of horses in groups A and D.

The *hoof horn condition* was assessed by adspection and palpation, every three to four months in horses in groups A, B, and C and at least every four to six months in horses in groups D and E. Alterations such as crumbly horn, cracks in the coronary horn, chips in the weight-

[1] Leu, U. (1987): Thesis submitted to the Veterinary Faculty, University of Zürich as fulfillment of the requirements for the Dr. med. vet. degree.

Fig.1

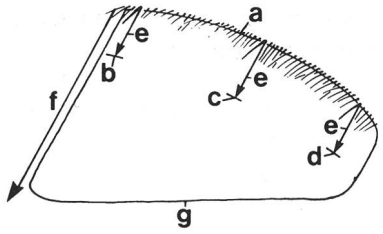

Figure 1: Measurement of the growth rate of the horn wall.
(a) Coronary border; (b–d) grooves, (b) dorsal, (c) lateral, (d) palmar; (e) direction of tubules and of measurements; (f) length of the anterior wall; (g) weight-bearing border.

Fig.2

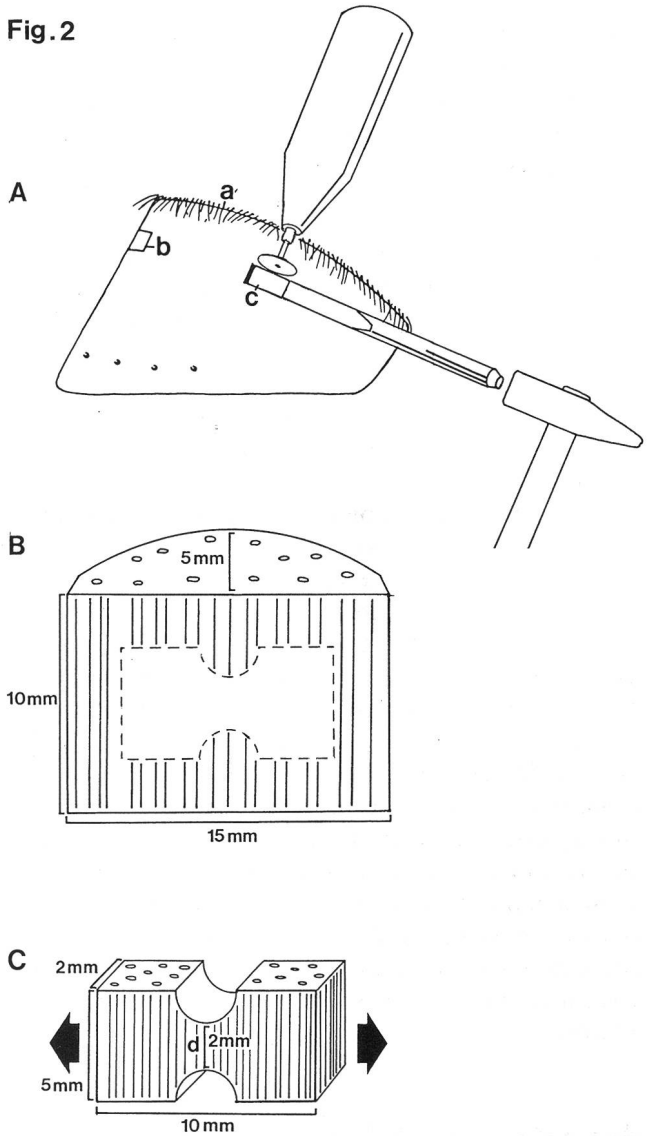

Figure 2: A. Location of horn specimen taken from a live horse, 30–40 mm below the coronary border. The proximal and distal edges of the specimen are sawed. After carving grooves at both ends of the specimen with a steel cutter, the specimen is excised with a sharp chisel. (a) Coronary border; (b) dorsal specimen; (c) lateral specimen.

B. Raw specimen showing the arrangement of horn tubules. Histological sections were taken from the proximal surface. The dashed line shows the geometry of the tensile specimen to be used in testing. A milling machine is used to manufacture the tensile specimen.

C. Specimen for tensile strength measurements. The specimen is mounted in the tensile testing machine with grips attached to both ends. The force required to fail the specimen in tension is measured. (d) area of failure; arrows: direction of force.

bearing border and decayed horn in the sole and frog were recorded at each assessment. The condition of each hoof was graded semiquantitatively as, 0, no changes; 1, mild changes; 2, moderate changes; or 3, severe changes. The average grade of all four hooves of each horse was calculated; the average grades determined at each assessment were compared.

The hooves of horses in groups A, B, and C were photographed every six months. Photographs of the hooves of horses in groups D and E were occasionally taken.

The assessment of hoof horn condition was performed for each horse by the same person. Groups A – D were assessed by Geyer using the previously described grading system. Group E was judged by Schulze according to the same criteria; the hoof condition was graded and compared before and after treatment using a modified method i.e. the hooves were graded as «cured», «improved», or «unchanged».

To investigate *histological alterations and physical properties* of the hoof horn, specimens of coronary horn were obtained from live animals approximately 3 cm (warmbloods, Icelandic ponies) or 4 cm (Belgians, Shires) under the coronary border (Fig. 2) as described in the thesis of Leu (1987). The excised horn was replaced with acrylic. The specimens were 15 mm long, 10 mm wide and 5 mm thick. They were obtained from the dorsal and lateral wall of the left fore and the right hind hooves every seven to eight months in groups A, B, and C. In 6 horses from group D the specimens were obtained at irregular intervals. Histological sections were cut from the proximal surface of the specimens by use of a microtome cryostat. The sections were stained by floating them in haematoxylin and eosin or alcian blue periodic acid-Schiff stains and mounted in glycerine jelly. The specimens were evaluated histologically and graded according to the previously described method i.e., 0, no changes; 1, mild changes; 2, moderate changes; 3, severe changes.

After histological sections had been made, the rest of each raw specimen was trimmed with a milling machine to a flat specimen of 10 x 5 x 2 mm (= tensile specimen). In the middle of the specimen the tensile strength of the

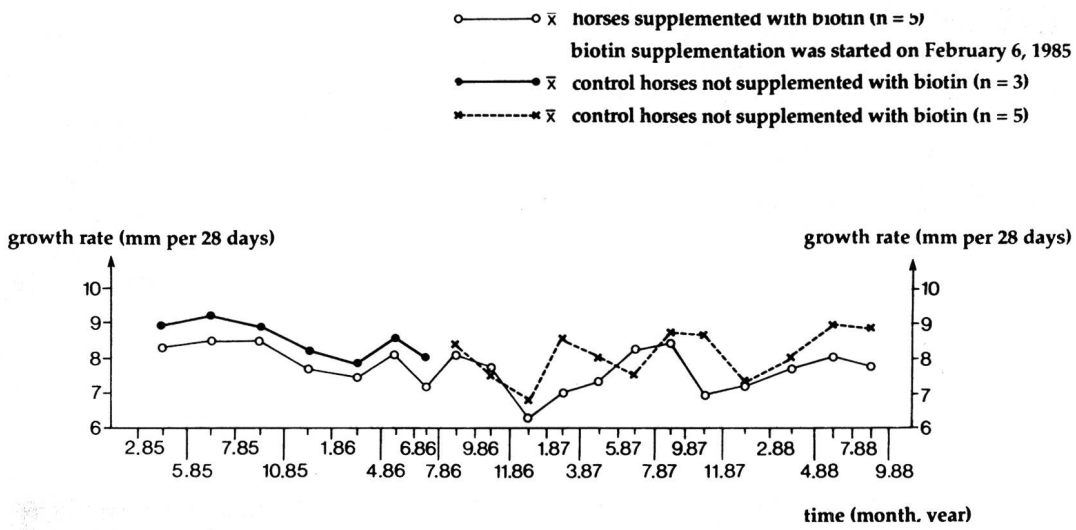

Figure 3: Mean growth rates of the hoof wall measured every 2-3 months (Group A).

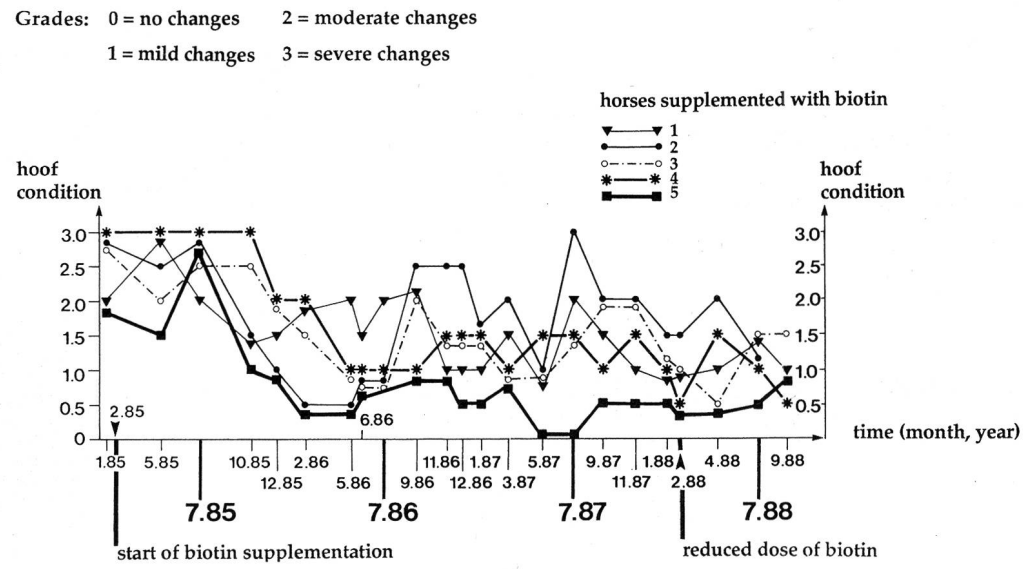

Figure 4: Macroscopic assessment of hoof condition in horses supplemented with biotin (Group A). The grades in Figures 4 and 5 represent the average of the condition of all 4 hooves of each horse at each assessment.

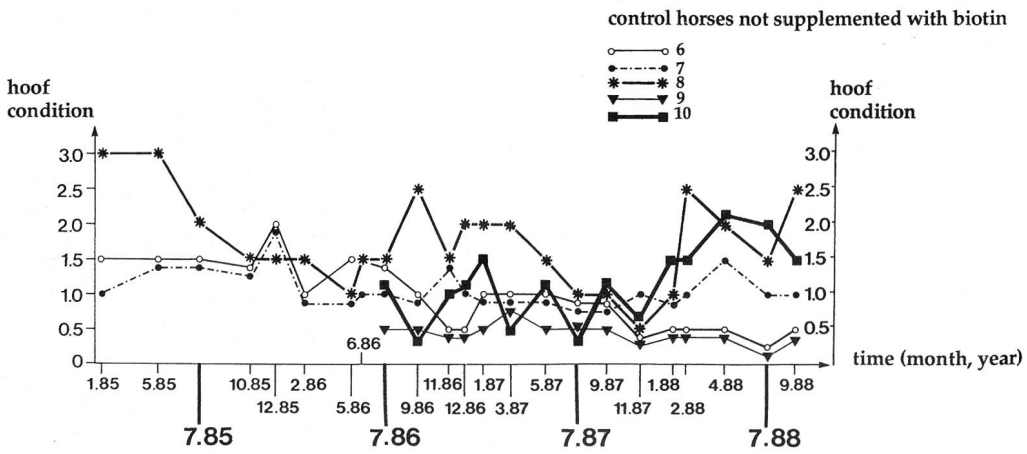

Figure 5: Macroscopic assessment of hoof condition in control horses not supplemented with biotin (Group A).

horn was then tested in a 2 x 2 mm area (Fig. 2; see also Küng, 1991). The *tensile strength* is the force in Newtons (N)/mm^2 or kilopond/mm^2 (1 kp = 9.81 N), required to tear the horn specimen into two pieces. The specimens were obtained from defined locations and prepared under the same conditions. Prior to the tensile strength test, the tensile specimens were stored in a chamber at 65% relative humidity and 20° C for 96 hours. The tensile strength was measured in hoof specimens from horses in groups A and B. In group C (Icelandic ponies), the raw specimens were not large enough for testing the tensile strength.

Results

The mean concentration of *plasma biotin* in horses not supplemented with biotin was 200 ng/l (range 150–450 ng/l) in horses of group A, B, D, and E and 300 ng/l (range 150–540 ng/l) in group C. After oral administration of biotin, the plasma concentration increased immediately to very high levels ranging around 20 000 ng/l. The highest values occurred within one hour of oral administration of biotin. Twenty-four hours after oral admini-stration of biotin, the concentration of plasma biotin was more than 1000 ng/l.

The *growth rate* of the coronary horn was calculated at each assessment by determining the mean value of all measurements at the three locations in two or four hooves.

In warmbloods, Belgians and Shires, the coronary horn, which forms the main part of the horn wall, grew an average of 8 mm/28 days (range 6–11mm/28 days; Fig. 3). In Icelandic ponies however, the horn wall grew only 4–5 mm/28 days. In group D, five of 15 horses (not warmbloods) each weighing 400 kg also had growth rates of only 5 mm/28 days.

In groups A, B, and C, there was *no difference between the growth rate* of the coronary horn *in horses supplemented with biotin and those not supplemented* with biotin (Fig. 3).

The *renewal time* of the entire hoof horn was calculated by dividing the length of the anterior wall by the growth rate.

The mean length of the anterior horn wall was 100 mm in warmbloods, 120 mm in Belgians and Shires and 90 mm in the Icelandic ponies.

The renewal time of the horn wall was approximately 12 months for warmbloods, 15 months for Belgians and Shires and 15–20 months for Icelandic ponies; the longer renewal time in the latter was attributable to the low growth rate of the coronary horn.

During *winter* the growth rates of the coronary horn decreased by 1–2 mm/ 28 days (Fig. 3).

The different locations of the horn wall (dorsal, lateral and palmar/plantar) had similar growth rates. The palmar/plantar part of the wall tended to have a lower growth rate in comparison to the dorsal and lateral parts.

The *hoof horn condition* of horses in *group A* was assessed macroscopically over a six year period; the results

Table 2: Hoof horn condition assessed macroscopically in horses supplemented with biotin (+) and in horses not supplement with biotin (controls; -) of Group A

Horse No.	Year of birth	Biotin	1984–85	1985–86	1986–87	1987–88	1988–89	1989–90	1990–91
1	*1972	+	2.33	1.75	1.35	1.25	1.00	† 7.6.89	•
2	*1980	+	2.50	1.25	1.86	1.86	† 24.7.88	•	•
3	*1976	+	2.67	1.75	1.35	1.33	1.08	2.00	1.83
4	*1977	+	3.00	2.00	1.29	1.17	.95	1.63	1.25
5	*1979	+	1.67	1.17	.79	.42	.67	.56	.50
6	*1979	-	1.33	1.50	1.00	.67	.29	1.06	† 14.9.90
7	*1981	-	1.00	1.33	1.08	1.08	1.17	1.38	1.00
8	*1977	- + from Sep. 88	3.00	1.50	1.86	1.33	1.67	1.38	1.42
9[1]	*1982	- + from Jun. 89	•	•	.93	1.17	2.08	1.75	1.67
10	*1983	-	•	•	.71	.50	.63	.63	.83
11	*1983	-	•	•	•	•	.88	.38	.75

Mean grades based on three to six assessments performed annually are reported: 0, no changes; 1, mild changes; 2, moderate changes; 3, severe changes.

• hoof condition not determined, horse not in trial in this period.

[1] † 22.4.1991

† all horses slaughtered because of illness unrelated to hoof problems.

over 3.5 years are reported in Figures 4 and 5. The mean grades determined every 12 months for each horse are reported in table 2. These grades were based on three to six assessments per year.

In November, 1984 and at the start of this study (February, 1985), the hooves of *horses supplemented with biotin* had a mean grade of 2.6 i.e., the hooves had severe changes.

The horn wall frequently had chipped-out areas at the weight-bearing border, and the surface of the horn was often uneven and crumbly. After three to six months of biotin supplementation, the surface of the proximal half of the hoof horn was smoother; however, the distal half still had severe changes. Eight to 15 months after the beginning of biotin supplementation, improvement was also observed in the distal parts of the hoof. There were fewer cracks and chipped-out areas in the horn wall, and thus the grades for hoof condition improved as well (Fig. 4). After 16 months of biotin supplementation, the mean grade for hoof condition was 1.1 i.e., mild changes.

With continuous biotin supplementation, the hoof condition of four horses in group A remained nearly constant. In horse No. 2, the condition of the hoof horn after

Figure 6: The severely chipped (a) right hind hoof of a Hanoverian horse (No. 5) at the beginning of biotin supplementation.

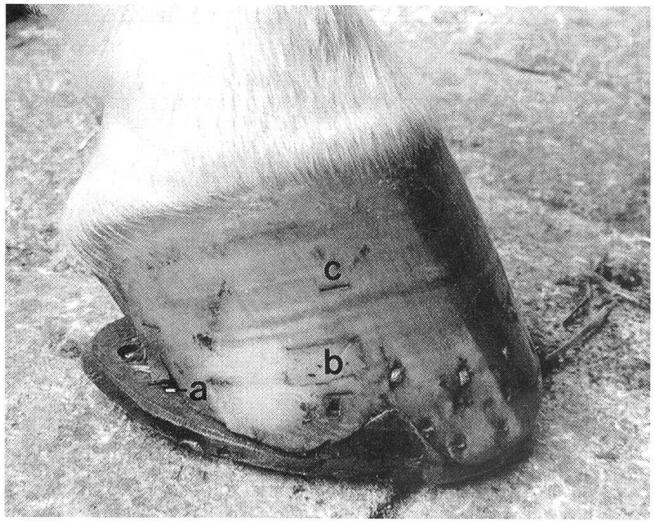

Figure 7: The same hoof as depicted in Figure 6 in good condition after one year of biotin supplementation.
(a) Small chip; (b) location of horn specimen taken 5 months prior to the photograph and closed with acrylic material ("hoof-repair"); (c) groove for measurements of growth rate.

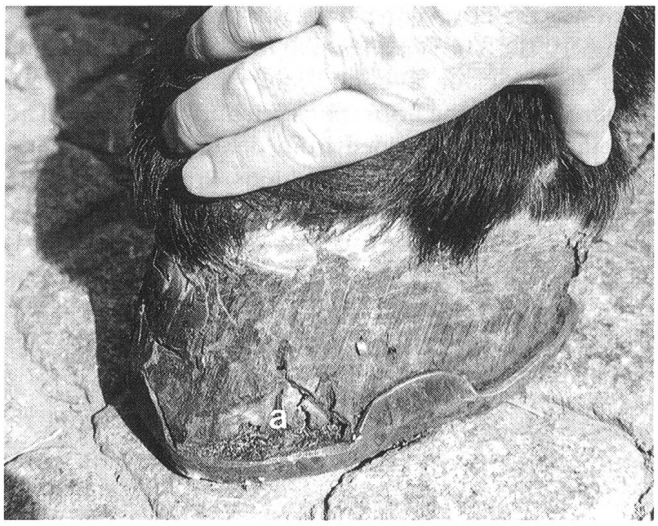

Figure 8: Medial view of the right hind hoof of a Belgian horse (No. 4). A large chipped area (a) can still be seen after 8 months of biotin supplementation.

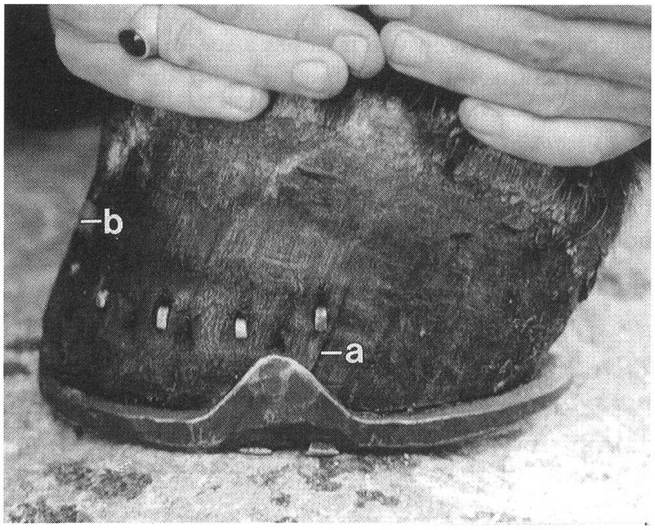

Figure 9: The same hoof as depicted in Figure 8 after 16 months of biotin supplementation.
The hoof is in fairly good condition and only a thin crack (a) is still present. (b) Location of dorsal horn specimen that was obtained 5 months prior to the photograph.

one year of biotin supplementation was graded as 1.25; this was substantiated histologically. Although the hoof horn condition deteriorated later, it was still better than at the start of the study. Continuous improvement in the hoof horn condition was observed in horse No. 5 (Fig. 6, 7) and No. 4 (Fig. 8, 9).

Control horses No. 6 and 7 had a better hoof horn condition at the start of the study than the horses supplemented with biotin. Horse No. 8 initially had hooves with severe changes. It was planned to include a second control horse with severe hoof horn alterations in this group; however, this horse, which had an average hoof horn grade of 3 in 4 of 5 assessments, was slaughtered in 1985 because of arthrosis of the hock joint.

Four of the control horses (No. 6, 7, 10 and 11) of group A subjected to the same management conditions as the other horses of this group had relatively good hoof horn condition which was constant over several years (Fig. 5, table 2).

Control horse No. 8 repeatedly had phases of poor hoof horn condition interrupted by phases in which the hoof horn improved. The first phase of improvement without treatment (1985/86) is explained in the results of histology and tensile strength measurements. In the third phase of a poor hoof horn condition, biotin treatment was initiated. Another horse, (No. 10) initially had relatively good hoof horn status, which after 1.5 years started to deteriorate; biotin supplementation was started in June 1989 because this horse had chipped areas in the front hooves, most pronounced in the medial wall of the right front hoof.

The Shires in *group B* were supplemented with biotin for eight months. Before supplementation, the mean grade of the hoof horn condition was 1.5 (mild to moderate changes); after eight months the condition of the hoof horn had improved slightly (mean grade = 1.25). The hoof horn condition of the two control horses in group B had a grade of 1.3 throughout the eight months.

In *group C,* the hoof horn condition of two horses improved from an initial grade of 2.0 (moderate changes) to 1.0 after 16 months of biotin supplementation. The mean grade of the hoof horn condition of the two control horses remained constant at 2.0 throughout the study.

After approximately one year of biotin supplementation, the hoof horn condition of horses in *group D* generally showed a good improvement. The average grade for hoof horn condition of 14 of the horses was 2.4 at the start and 1.0 at the end of the study. One horse had intermittent laminitis and crumbly horn which was chipped at the weight-bearing border; the hoof horn condition of this horse did not improve during the study.

The hoof condition of the 70 horses of *group E* was assessed by palpation and adspection but was not graded. Of the 70 horses in group E, 42 (60%) had healthy hoof horn and 28 (40%) showed an improvement in hoof horn condition after one year of biotin supplementation.

The following long-time observations should address *the question, whether or not biotin therapy should be continued* after a satisfactory hoof condition has been achieved. The results show that biotin supplementation should not be reduced or terminated.

After approximately one year of biotin supplementation, the hoof horn condition of two warmblood horses in group D showed a good improvement. Biotin supplementation was then discontinued and after one year, the hoof horn condition deteriorated and the hoof horn was once again brittle.

Five mg of biotin per 100–150 kg body weight was administered daily to the five horses in group A for three years; then the daily dose of biotin was reduced to 1.25 mg per 100–150 kg (February, 1988) for three years. During the second and third years of reduced biotin supplementation, the hoof horn condition of horses 3 and 4 was *worse* than during full biotin supplementation but better than before biotin supplementation (Table 2). The hoof horn condition of horse 5 did not change after reduction of the daily dose of biotin. Horses 1 and 2 were slaughtered after 16 and 5 months of reduced biotin supplementation, respectively, and therefore the effect of a reduced dose could not be assessed macroscopically.

Four horses of group D were supplemented daily with 5 mg of biotin per 100–150 kg body weight for two years. The daily dose was then reduced to 1.25 mg per 100–150 kg body weight for a minimum of two years. The hoof horn condition of two of these horses was good after the first two years of biotin supplementation and did not change with the reduced biotin dosage. The other two horses also obtained a good hoof condition with full biotin dosage; however, after two years of reduced biotin dosage, the hoof horn condition worsened (grades 2.0 and 1.5) but did not deteriorate to the initial condition

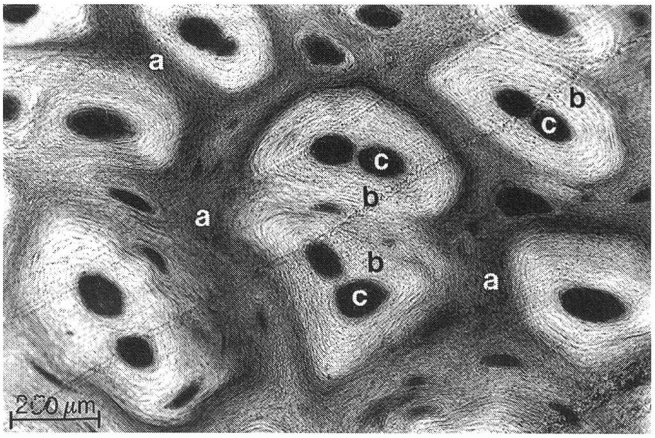

Figure 10: Transverse section of the coronary horn from the proximal horn wall with severely altered intertubular horn (a) before biotin supplementation. Alcian blue-PAS staining.
(a) Intertubular horn, cell membranes or whole cells are stained intensely with PAS; (b-c) deformed tubules, (b) tubular cortex, (c) tubular marrow.

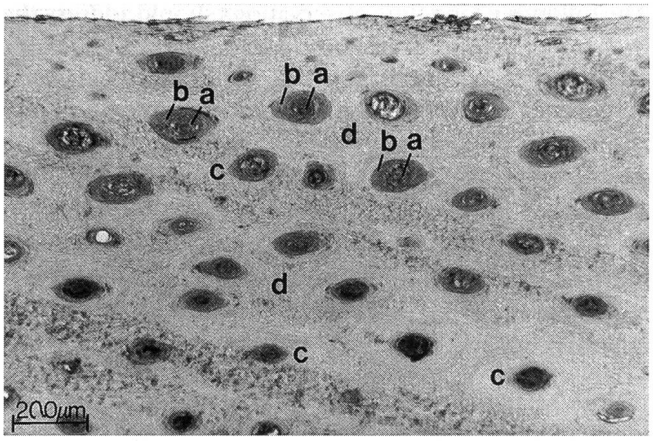

Figure 11: Transverse section through the outer part of the coronary horn before biotin supplementation. The specimen was taken from the proximal part of the horn wall of a Thoroughbred (Group D). Alcian blue-PAS staining.
Note the marrows (a) which are enlarged by decayed cortical cells (b). (c) Unchanged cortial cells; (d) intertubular horn.

before biotin supplementation. The daily dose of biotin was then increased to 5.0 mg per 100–150 kg body weight.

Histological examination of hoof horn specimens revealed that there were alterations in the coronary horn of the proximal part of the horn wall of horses in groups A – D. These alterations included more intense positive PAS staining of the cell membranes than normal (Fig. 10) and positive PAS staining of the entire horn cells, indicating cell disintegration. Decayed inner cortical cells of the horn tubules which stain positively with PAS resulted in enlargement of the marrows (Fig. 11).

Hoof horn specimens were evaluated histologically by use of the same grading system used to assess the macroscopic appearance of the hoof horn (Table 3). Histological alterations of hoof horn specimens obtained 3–4 cm under the coronary border were not as severe as the macroscopical alterations; in the macroscopic assessment, the entire hoof including the frequently altered weight-bearing border was assessed.

The coronary horn of *horses supplemented with biotin* in all three groups improved histologically after seven to eight months of biotin supplementation (Table 3); this improvement was maintained after 15 months of biotin supplementation. In comparison to the start of the study, the histological alterations of the coronary horn were less frequent and less severe after eight months of biotin supplementation. However, the horn did not recover completely and remained slightly altered during biotin supplementation.

This result is demonstrated in Figures 11 and 12. The coronary horn of the dorsal hoof wall of a horse supplemented with biotin (group D) had many tubules with enlarged marrows at the start of the study (Fig. 11). After 16 months of biotin supplementation, the tubular structure had improved, and the marrows were smaller than before but some decayed cortical cells were still present (Fig. 12). By use of histometry, it was determined that the percentage of the marrows in the horn of this area was reduced from 25%, at the start of the study, to 12% after biotin supplementation. The entire specimen had severe changes (3.0) at the start of the study and mild to moderate changes (1.5) at the end; the mean grade of all four specimens, which were obtained from this horse, improved from 1.75 to 1.0.

Table 3: Histological evaluation of horn specimens from the proximal half of the horn wall

Group	Biotin	Beginning of the trial		after 7–8 months		after 15 months	
A	+	$\bar{x}$	1.59	$\bar{x}$	0.96	$\bar{x}$	0.95
		n	20	n	19	n	20
	–	$\bar{x}$	0.71	$\bar{x}$	0.94	$\bar{x}$	0.89
		n	12	n	12	n	11
B	+	$\bar{x}$	1.29	$\bar{x}$	1.06	$\bar{x}$	–
		n	12	n	11	n	–
	–	$\bar{x}$	1.0	$\bar{x}$	1.08	$\bar{x}$	–
		n	8	n	8	n	–
C	+	$\bar{x}$	1.13	$\bar{x}$	0.63	$\bar{x}$	0.69
		n	8	n	8	n	8
	–	$\bar{x}$	1.34	$\bar{x}$	1.13	$\bar{x}$	1.88
		n	12	n	12	n	8

$\bar{x}$ = average grade of n specimens; as a rule, four specimens (dorsal and lateral of the left fore and the right hind hooves) were obtained from each horse.

Grades: 0, no changes; 1, mild changes; 2, moderate changes; 3, severe changes.

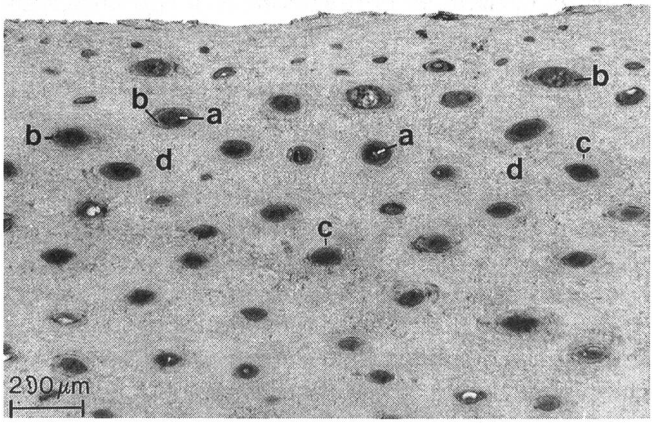

Figure 12: Transverse section through the same part of the coronary horn as depicted in Figure 11 after 16 months of biotin supplementation. Alcian blue-PAS staining.
The marrows (a) are smaller than before, but some decayed cortical cells (b) are still present.
(c) Unchanged cortical cells; (d) intertubular horn.

The histological structure of the hoof horn of *horses not supplemented with biotin* in group A, B, and C remained nearly constant during the study, or deteriorated slightly (Table 3).

In group A, the histological and macroscopic findings initially indicated that the hoof horn condition of the control horses was better than that of the horses supplemented with biotin. It is important to note that the hoof horn condition of horse No. 8 improved macroscopically for 15 months (Fig. 5) without biotin supplementation; initially the coronary horn specimens of the proximal hoof wall were already in good condition and had a mean histological grade of 0.63, which increased to 0.75 after seven months and reached a value of 1.06 after 15 months.

The measurements of tensile strength were performed *in the exterior part of the coronary horn* two to three times in group A and once in group B. Due to technical problems, only a small number of specimens could be processed at the beginning of the trial, whereas after eight and 15 months, three to four specimens from every horse were physically tested. The tensile strength of normal unaltered coronary horn in the proximal part of the horn wall was 60 N/mm^2 or more. The tensile strength of histologically altered portions of horn was reduced. This could be demonstrated in several horses of group A when the tensile strength was measured in portions of horn with histological alterations. The tensile strength of the horn specimen in Figure 10 with altered intertubular horn was only 28 N/mm^2.

In another specimen with similar alterations and from the same horse, the tensile strength was 26 N/mm^2. The lowest value of altered hoof horn in group A was 20 N/mm^2.

The initially low tensile strength values measured in group A improved after eight months of *biotin supplementation* in specimens obtained from the same locations. After 15 months of supplementation, the tensile strength had reached nearly normal values at these locations.

The average tensile strength of coronary horn specimens increased from 53 N/mm^2 (n = 12 specimens) to 64 N/mm^2 (n = 19) after eight months and reached 67 N/mm^2 (n = 20) after 15 months of biotin supplementation. It is important to note that especially the very low values of tensile strength mentioned above improved markedly at the same locations after biotin supplementation, to values higher than 50 N/mm^2.

The mean tensile strength of the coronary horn improved in the *control horses* from 58 N/mm^2 (n = 5 specimens) at the start of the study to 67 N/ mm^2 (n = 12) after eight months, and to 70 N/mm^2 (n = 11) after 15 months. Two hoof horn specimens from control horse No. 8 had a tensile strength of 53 and 72 N/mm^2 at the beginning of this study, indicating good quality coronary horn in the proximal hoof wall.

Control horse No. 6 also had good quality horn with a tensile strength of 63 N/mm^2 at the beginning of the study, 76 N/mm^2 after 8 months and 79 N/mm^2 after 15 months; three years later, when this horse was slaughtered, coronary horn specimens obtained from the same locations had a mean tensile strength of only 66 N/mm^2.

The tensile strength of hoof horn specimens from *group B* could not be measured at the start of the trial, because the specimens were too small. Seven months after the start of the study, there was no difference between the tensile strength of hoof horn specimens between the horses supplemented with biotin (x = 63 N/mm^2) and two control horses (x = 66 N/mm^2). The macroscopic and histologic results prove, however, that two of three supplemented horses had a poorer hoof horn condition at the start of the study than the two control horses.

The following results of tensile strength measurements may provide some additional information about the *consequences of ending or reducing biotin supplementation.*

One horse of group B was supplemented with biotin for eight months, and the mean tensile strength of the four proximal coronary horn specimens at this time was 62 N/mm^2. Eleven months after the end of biotin supplementation, the horse was slaughtered; the mean tensile strength of the four coronary horn specimens obtained from the same locations was 44 N/mm^2.

When this horse was slaughtered, the weight-bearing border of the dorsal wall consisted of horn produced during biotin supplementation. The average of 6 specimens taken from the dorsal part of the weight-bearing border (produced during biotin supplementation) was 49 N/mm^2. In comparison, six horn specimens of the dorsal wall of the proximal part of the hoof (produced without biotin) had a mean tensile strength of only 43 N/mm^2. It should be remembered that the tensile strength of coronary horn is usually lower at the weight-bearing border than in the proximal part of the hoof (Küng, 1991; Zenker, 1991).

The tensile strength of proximal hoof horn specimens from horses No. 1 and 2 of group A was 58 N/mm^2 and 68 N/mm^2, respectively, during supplementation with the full biotin dose. When the biotin dose was reduced, the tensile strength decreased to 53 N/mm^2 and 55 N/mm^2. In comparison, the tensile strength of proximal coronary horn specimens from horse No. 9 of group A, which had been supplemented with the full dose of biotin for two years, was 60 N/mm^2.

Discussion

The *plasma concentration of biotin* in untreated horses with mean values near 200 ng/l (range 150–450 ng/l) is very low (see also Schulze and Scherf, 1989). It should be noted that the lowest measurable value is 150 ng/l. In group C (Icelandic ponies) the mean concentrations were 300 ng/l (range 150–540 ng/l). This approximates the results of Josseck (1991) in Lipizzan horses, whose mean concentrations were 350 ng/l.

Normal biotin plasma levels vary greatly among different species: In ruminants the plasma biotin levels are slightly

higher (450–600 ng/l, Comben, 1987) than in horses. The plasma concentrations of pigs ranges between 400 ng and 1000 ng/l. (Whitehead et al., 1980; Geyer et al., 1984; Bryant et al., 1990). According to Frigg et al. (1989) the biotin blood level of dogs ranges within 600–2500 ng/l. Schulze (1987) observed mean plasma levels of 1500 ng/l in yearling beagles compared with 2200 ng/l in beagles which were 6 months old.

In pigs, plasma concentrations of biotin below 400 ng/l are indicative of biotin deficiency (Völker, 1977). However, the low plasma concentrations are not indicative of biotin deficiency in horses. In Lipizzan horses with frequent hoof horn alterations Zenker (1991) measured carboxylase activities of lymphocytes, which revealed no signs of biotin deficiency. In the horses of our study (untreated, or before biotin supplementation) no correlation could be demonstrated between plasma level and hoof horn condition. Horses with good and those with bad hoof horn quality had very low plasma biotin levels. Biotin deficiency in pigs results in dramatic hair loss (Geyer et al., 1981); the hair coat of horses with hoof problems in this study and the study of Josseck (1991) and Zenker (1991) were in good condition.

The plasma concentration of biotin can be used to determine whether or not a horse is being supplemented with biotin. Supplementation may be suspected with concentrations above 500 ng/l and is certain with concentrations above 1000 ng/l.

Biotin supplementation did not increase the growth rate of the coronary horn. This is in agreement with the results of studies involving Lipizzan horses (Josseck, 1991) and pigs (Johnston and Penny, 1989). It is important to remember that the growth rate of the coronary horn varies between individuals (Josseck, 1991) and between breeds. In warmblood, Belgian and Shire horses, the mean growth rate of coronary horn was 8 mm per 28 days, whereas in Icelandic ponies, it was 4 to 5 mm per 28 days. Based on the growth rate of the coronary horn, the time required for the renewal of the entire hoof is at least one year and in breeds with a low horn growth rate, may be almost two years. In horses with alterations in the weight-bearing border of the horn, improvement can be expected only when the better quality horn produced at the coronary band during biotin supplementation or another therapy reaches the weight-bearing border. In contrast, improvement of frog and sole alterations may be observed sooner because the time required for renewal of the sole horn, based on a growth rate of 4 to 4.5 mm/ 28 days, is approximately 100 days (Josseck, 1991).

The growth rate of the coronary horn was often lower in winter than during the rest of the year. This was also reported by Josseck (1991). Perhaps reduced digital blood flow is the cause of the lower growth rate in winter. In studies involving sheep housed at different temperatures, Wheeler et al. (1972) observed a dramatic decrease in the growth rate of hoof horn from 4 mm/28 days when the sheep were kept at 20C to 1 mm/28 days when the sheep were housed at 0C.

The aim of the *macroscopic investigations* was to examine the hoof status of horses supplemented with biotin and of untreated controls *over a long time.* The horses in group A were observed for a period up to 6 years. By use of protocol sheets, photographs and the previously described grading system, which summarized all findings at a certain date in one grade, it was possible to compare the results from different dates in a simple manner (Fig. 4–5). In long time observations it was possible to determine which horses had hoof horn of permanent good quality, and it was observed that horses with hoof horn problems had alterations for many years (Fig. 5). From the results of this study it was evident that hoof horn alterations will usually not improve over a long period of time without any treatment. In most cases poor quality hoof horn is a lifetime problem when left untreated i.e. therapy is not initiated or environmental factors are not addressed.

In addition to the horses of groups A-C, where biotin treated and control horses were kept under equivalent conditions, groups D and E (comprised only of biotin treated horses from different stables) were involved in this study with the aim of obtaining more information on the effect of biotin therapy in a large number of clinical cases with hoof horn problems. Each horse was maintained under uniform conditions before and during biotin supplementation; biotin therapy was the only factor which varied.

In horses supplemented with biotin, there was generally an improvement in macroscopically assessed horn condition. (Fig. 4, Table 2). Improvment was observed eight to 15 months after the start of biotin supplementation, because most of the initial problems were in the weight-bearing border of the hoof. In a recently performed blind study involving Lipizzan horses with brittle coronary horn and soft horn in the white line, the horses supplemented with biotin showed a significant improvement in hoof condition in comparison to the control horses and compared with their initial hoof condition (Josseck, 1991; Zenker, 1991).

The *histological findings* obtained from consistent locations of the proximal horn wall were compared with the normal structure as described by Bucher (1987) and Bolliger (1991). Periodical sampling of specimens allowed comparison of the histological structure before and during biotin therapy.

Histological alterations were seen in the proximal horn, about 2 to 3 cm distal to the live epidermal cells that produce the perioplic and coronary horn. It was concluded that altered horn already has defects when it is produced. These defects become visible when the horn is later subjected to loading and environmental factors. The results of the histological examination in this study indicate that brittle, crumbly horn has specific morphological alterations (Fig. 10, 11). In another study involving proximal horn specimens from the horses in group A, Budras and Geyer (1989) observed ultrastructural alterations in the membrane coating material, which is a

glue-like substance (Budras and Bragulla, 1990), responsible for adhesion of the horn cells.

In horses supplemented with biotin, the histological alterations of the proximal horn wall decreased in severity and frequency but did not disappear completely. An improvement in the histological structure was evident after seven to eight months of biotin supplementation.

Zenker (1991) made periodical investigations of the histological structure of horn specimens from the weight-bearing border of Lipizzan horses. In these specimens it was more difficult to interpret the histological results than in specimens from the proximal part of the horn wall, because specimens from the weight-bearing border were subjected to marked environmental influences. Improvements in structure induced by therapy are observed much later in specimens from the weight-bearing border than in specimens from the proximal part of the horn wall. Zenker (1991) reported that there was no significant histological improvement in horn specimens from the weight-bearing border after 14 months of biotin supplementation; however, there was a significant improvement after 19 months of biotin supplementation. In an ultrastructural study, Kempson (1987, 1990) reported that the loose structure of brittle horn in specimens from the weight-bearing border improved after the horses were supplemented with biotin or «Farrier's Formula», which contains biotin and ten other components such as methionine, zinc, etc.. In women with brittle nails, biotin supplementation resulted not only in improvement of the macroscopic nail condition (Floersheim, 1989) but also in the ultrastructure of the nails (Colombo et al., 1990). The horn cells of fingernails were denser and had a more regular arrangement after biotin supplementation (Colombo et al., 1990).

In this study, hoof horn specimens with histological alterations had a lower *tensile strength* than healthy or unchanged specimens. Thus, histological alterations can influence the mechanical properties of hoof horn. The tensile strength of all but one altered hoof horn specimens improved after eight months of biotin supplementation. After seven to 15 months of biotin supplementation, there was a further improvement in the tensile strength of hoof horn specimens, although there was no improvement in the histological grades of these specimens. It can be concluded that prolonged biotin supplementation is necessary for improvement of the histological structure and of the tensile strength of the hoof horn.

It is difficult to explain the improvement of tensile strength of hoof horn specimens of the control horses in group A. At the start of the study, very few specimens of the control group could be measured. Perhaps at the initial phase of measurements possible technical irregularities during treatment of the specimens could have influenced the results. In the measurements performed after 8 and 15 months of biotin supplementation, differences due to variations in humidity cannot be completely excluded; climatisation of specimens, which preceeds the tensile test, is a very important factor. In normal specimens, which are very dry, the tensile strength is higher than in humid specimens (Küng, 1991). Furthermore it has to be considered that a faulty application of biotin to the control horses is also possible in a stable, where some horses are treated with biotin. In the monthly controls of the plasma biotin levels in group A the plasma level of the «untreated» horses exceeded 1000 ng /l three times in horse No. 7 and once in horse No. 8 within 16 months.

The results of histological examination and tensile strength measurements of the proximal part of the coronary horn provide valuable information about the «young part» of the hoof. If this part of the hoof is in good condition (in biotin supplemented or in untreated horses), one may expect that after several months, the horn of the weight-bearing border will also be of good quality.

How biotin influences the hoof epidermis is not known. It has been reported that in cell cultures of keratinocytes, the keratin pattern changed when biotin was added to the medium (Fritsche, 1991; Fritsche et al., 1991). It may be that biotin inhibits premature decay of horn cells. The cell membrane and the membrane coating material are important for good adhesion of the horn cells, and thus influence the mechanical properties of the horn. Perhaps biotin has an influence on the cell membrane or the membrane-coating material. The results of histological examination and measurements of tensile strength provide more detailed information about the quality of the hoof horn than the macroscopical evaluation. However, the macroscopical evaluation concerns the entire hoof, whereas the histological and tensile strength evaluations only involve a small part of the hoof.

The results of this study indicated that biotin improved the hoof horn quality but did not stimulate the growth rate of coronary horn. In addition, the hoof horn quality deteriorated after reduction of the daily dose of biotin or discontinuation of biotin supplementation. Thus, continuous biotin supplementation at the full dosage is recommended for horses with hoof horn problems. Based on the results of Josseck (1991) and Zenker (1991), it is recommended that only horses with good hoof horn quality should be used for breeding purposes.

References

Bolliger C. (1991): The equine hoof – morphological and histochemical findings. Diss. med. vet. Zürich.

Brooks P.H., Simmins D.H., Irwin V.C.R. (1977): Biotin supplementation of diets; the incidence of foot lesions, and the reproductive performance of sows. Vet. Rec. *101*, 46–50.

Brooks P.H., Simmins D.H. (1980): Recent findings on the effect of biotin supplementation on reproductive performance and the maintenance of hoof integrity in the female pig. Roche Symposium, London, October 1980.

Bryant K.L., Kornegay E.T., Knight J.W., Veit H.P., Notter D.R. (1985): Supplemental biotin for swine, III: Influence of supplementation to corn- and wheat-based diets on the incidence and severity of toe lesions, hair and skin characteristics and structural soundness of sows housed in confinement during four parities. J. Animal Sci. *60*, 154–162.

Bryant K.L., Kornegay E.T., Knight J.W., Notter D.R. (1990): Uptake and clearance rates of biotin in pig plasma following biotin injections. Internat. J. Vit. Nutr. Res. *60*, 52-57.

Bucher K. (1987): Zum mikroskopischen Bau der Epidermis an umschriebenen Stellen des Pferdehufes. Diss. med. vet. Zürich.

Budras K.D., Geyer H. (1989): Elektronenmikroskopische Untersuchung über abnorm verändertes Horn in der Schutzschicht des Pferdehufes. Anat. Histol. Embryol. *18*, 268.

Budras K.D., Hullinger R.J., Sack W.O. (1989): Light and electron microscopy of keratinization in the laminar epidermis of the equine hoof with reference to laminitis. Am. J. Vet. Res. *50*, 1150-1160.

Budras K.D., Bragulla H. (1990): Besonderheiten des Membrane Coating Material (MCM; Kittsubstanz zwischen Keratinozyten) im harten Horn des Pferdehufes. 85. Versammlung der anatomischen Gesellschaft, München 1.-4.4.1990, S. 39.

Comben N., Clark R.J., Sutherland D.J.B. (1984): Clinical observation on the response of equine hoof defects to dietary supplementation with biotin. Vet. Rec. *115*, 642-645.

Comben N. (1987): Dairy cows: Biotin and claw health - Pilot studies. Biotin Workshop CH-4310 Rheinfelden, September 1987.

Colombo V.E., Gerber F., Bronhofer M., Floersheim G.L. (1990): Treatment of brittle fingernails and onychoschizia with biotin: scanning electron microscopy. J. Am. Acad. Dermatol. *23*, 1127-1132.

Floersheim G.L. (1989): Treatment of brittle fingernails with biotin. Z. Hautkrankheiten, *64*, 41- 48.

Frigg M., Brubacher G. (1976): Biotin deficiency in chicks fed a wheatbased diet. Int. J. Vitam. Nutr. Res. *46*, 314-321.

Frigg M., Schulze J., Völker L. (1989): Clinical study on the effect of biotin on skin conditions in dogs. Schweiz. Arch. Tierheilk., *131*, 621-625.

Fritsche A. (1991): Biotin verändert das Zytokeratinmuster von kultivierten Keratinozyten. Diss. med. vet. Zürich.

Fritsche A., Mathis G., Althaus F.R. (1991): Pharmakologische Wirkungen von Biotin auf Epidermiszellen. Schweiz. Arch. Tierheilk. *133*, 277-283.

Recherches à long terme sur l'influence de la biotine sur la qualité de la corne du sabot chez le cheval

L'influence de la biotine sur la qualité de la corne a été examiné durant une période de 1-6 années chez des chevaux possédant une corne friable et des parois dérobées. 97 chevaux ont reçu oralement 5 mg de biotine par 100-150 kg poids vif et par jour; 11 chevaux n'ont reçu aucun traitement et ont servis de contrôle.
L'état macroscopique des sabots de tous les chevaux a été contrôlé tous les 3-4 mois. Pour obtenir plus d'information sur la qualité de la corne, des échantillons provenant de la paroi proximale ont été prélevés et examinés histologiquement chez 25 chevaux; la résistance à la traction de la corne a été également testées chez 15 de ces chevaux. La corne coronaire saine présente une résistance à la traction de 60 N/mm^2 et plus; dans des zones présentant des altérations histologiques elle diminue, la valeur la plus basse atteignant 20 N/mm^2.
D'après l'examen macroscopique et histologique la qualité de la corne des sabots a été améliorée par un traitement de biotine de 8-15 mois. L'état des sabots du groupe de contrôle est resté plus ou moins constant durant la période de recherche. Le taux des croissance de la corne coronaire a été identique chez le groupe de contrôle et le groupe soumis au traitement. Après réduction de la dose de biotine ou après un arrêt de traitement l'état des sabots s'est détérioré chez 7 des 10 chevaux. Un traitement de biotine permanent et à dose complète est recommandé chez des chevaux présentant de graves altérations de la corne du sabot.

Ricerca di lunga durata sull'influsso di biotina sulla qualità cornea dello zoccolo equino

L'influsso di biotina fu esaminato sulla qualità cornea dello zoccolo equino, con corneo dello zoccolo sminuzzato e con rotture del orlo plantare per una durata di 1-6 anni. 97 cavalli ricevettero giornalmente 5 mg di biotina per 100-150 kg peso per os; 11 cavalli non vennero trattati e servirono come controllo. Lo stato dello zoccolo di tutti i cavalli venne valutato macroscopicamente e clinicamente ogni 3-4 mesi. Per la valutazione della qualità cornea dello zoccolo, vennero prelevati dei campioni da 25 cavalli dalla parte prossimale della parete cornea ed esaminati istologicamente come vennero pure esaminati 15 cavalli anche sulla resistenza alla tensione. La resistenza alla tensione di corneo coronario inalterato misurò 60 N/mm^2 oppure di più; nel raggio di mutamenti istologici la resistenza alla tensione fu ridotta; mentre il coefficiente più basso ascese solo fino a 20 N/mm^2.
Secondo le valutazioni macroscopiche ed istologiche lo stato dello zoccolo si migliorò per i cavalli supplementati con biotina dopo una durata del trattamento di 8-15 mesi. Lo stato dello zoccolo degli animali di controllo non trattati rimase ampiamente costante durante l'esperimento. La quota di accrescimento corneo coronario fu identica per i cavalli trattati come non trattati. Dopo una riduzione della dose di biotina oppuro dopo terminazione del trattamento lo stato corneo si peggiorò per 7 di 10 cavalli. Per i cavalli con mutamenti gravi cornei dello zoccolo, viene per ciò raccomandato un trattamento di lunga durata con piena dose di biotina.

Geyer H., Pohlenz J., Völker L. (1981): Morphologische und histochemische Untersuchungen von Haut, Schleimhäuten und Klauen bei Schweinen mit experimentellem Biotinmangel. Zbl. Vet. Med. A, *28*, 574-592

Geyer H., Schulze J., Streiff K., Tagwerker F., Völker L. (1984): Der Einfluss des experimentellen Biotinmangels auf Morphologie und Histochemie von Haut und Klauen des Schweines. Zbl. Vet. Med. A, *31*, 519-538.

Geyer H., Frigg M., Schulze J. (1988): La structure du sabot et l'influence de la biotine sur la qualité de la corne. Infor-Maréchalerie *15*, 25-32.

Johnston A.M., Penny R.H.C. (1989): Rate of claw horn growth and wear in biotin-supplemented and non-supplemented pigs. Vet. Rec. *125*, 130-132.

de Jong M.F., Sytsema J.R. (1983): Field experience with d-biotin supplementation to gilt and sow feeds. Vet. Quart. *5*, 58-67.

Josseck H. (1991): Hufhornveränderungen bei Lipizzanerpferden und ein Behandlungsversuch mit Biotin. Untersuchungen des makroskopischen Hufstatus und des Hornwachstums sowie zum Verlauf des Plasmabiotinspiegels und über genetische Grundlagen der Hufhornschäden. Diss. med. vet. Zürich.

Kempson S.A. (1987): Scanning electron microscope observations of hoof horn from horses with brittle feet. Vet. Rec. *120*, 568-570.

Kempson S.A. (1990): Ultrastructural observation on the response of equine hoof defects to dietary supplementation with Farrier's Formula. Vet. Rec. *127*, 494-498.

Küng M. (1991): Die Zugfestigkeit des Hufhornes von Pferden. Diss. med. vet. Zürich.

Leach D.H., Oliphant L.W. (1983): Ultrastructure of the equine hoof wall secondary epidermal lamellae. Am J. Vet. Res. *44*, 1561-1670.

Leu U. (1987): Vergleichende Untersuchungen über den Einfluss von oral verabreichten Biotin auf das Hufhorn beim Pferd. Diss. med. vet. Zürich.

Nickel R. (1938): Über den Bau der Hufröhrchen und seine Bedeutung für den Mechanismus des Pferdehufes. Gegenbaur's Morphol. Jb. *82*, 119-160.

Penny R.H.C., Cameron R.D.A., Johnson S., Kenyon P.J., Smith H.A., Bell A.W.P., Cole J.P.L., Taylor J. (1980): Foot rot in pigs: The influence of biotin supplementation on foot lesions in sows. Vet. Rec. *107*, 350-351.

Schulze J. (1987): Biotin in dogs: Clinical studies. Biotin Workshop CH-4310 Rheinfelden, September 1987.

Schulze J., Scherf H. (1989): Klinische Studie zur Therapie mit Biotin beim Pferd. Tierärztl. Umschau *4*, 198-190.

Völker L. (1977): Biotin in der Tierernährung. Übers. Tierernährg. *5*, 185-220.

Webb N.G., Penny R.H.C., Johnston A.M. (1984): Effect of a dietary supplement of biotin on pig hoof horn strength and hardness. Vet. Rec. *114*, 185-189.

Wheeler J.L., Bennet J.W., Hutchinson J.C.D. (1982): Effect of ambient temperature and daylength on hoof growth in sheep. J. Agric. Sci. Camb. *79*, 91-97.

Whitehead C.C., Brooks P.H., Simmins P.H. (1980): Recent research on the responses of poultry and pigs to supplementary biotin. Proceedings of Roche Symposium London, October 23, 1980.

Wintzer H.-J. (1986): Der Einfluss einer Vitamin-H-Substitution auf Wachstum und Beschaffenheit des Hufhornes. Tierärztl. Praxis *14*, 495-500.

Zenker W. (1991): Hufprobleme bei Lipizzanern und ein Behandlungsversuch mit Biotin. Histologische Untersuchungen an veränderten Hufen und Bestimmung biotin-abhängiger Enzyme. Diss. med. vet. Zürich.

Ziegler H. (1951): Über die Bildung des Hufhorns. Schweiz. Arch. Tierheilk. *93*, 295-307.

Acknowledgements

We are grateful to
all owners of the horses used in this study for their good collaboration.
Mrs. J. Engler and collaborators, Hoffmann-La Roche, Basel, for the measurements of plasma biotin concentrations.
Mrs. A. Hulftegger and Mrs. U. Färber for the histological technique.
Dr. V. Esslinger and Mr. P. Wiget from the Swiss Federal Laboratory for Material Testing and Research, Dübendorf for their assistance in measurements of tensile strength.
Mrs. J. Peter and Mrs. A. Hug for the diagrams and photographs.
Mrs. Dr. Chris Winder-Wälchli and Mrs. Denise Myers for the translation.
Mrs. M. Balushev for typing the manuscript.

Adresses of the authors:
Prof. Dr. H. Geyer, Veterinär-Anatomisches Institut, Winterthurerstr. 260, CH - 8057 Zürich
Dr. J. Schulze, Société Chimique Roche S. A., Dépt. CRNA, B. P. 170, F - 68 305 Saint-Louis Cedex

Manuskripteingang: 21. September 1992