

Zeitschrift: Schweizer Archiv für Tierheilkunde SAT : die Fachzeitschrift für Tierärztinnen und Tierärzte = Archives Suisses de Médecine Vétérinaire ASMV : la revue professionnelle des vétérinaires

Herausgeber: Gesellschaft Schweizer Tierärztinnen und Tierärzte

Band: 132 (1990)

Heft: 8

Artikel: Experimentally induced liver granulomas after long-term inhalation of quartz in non-human primates

Autor: Rosenbruch, M.

DOI: <https://doi.org/10.5169/seals-593702>

Nutzungsbedingungen

Die ETH-Bibliothek ist die Anbieterin der digitalisierten Zeitschriften auf E-Periodica. Sie besitzt keine Urheberrechte an den Zeitschriften und ist nicht verantwortlich für deren Inhalte. Die Rechte liegen in der Regel bei den Herausgebern beziehungsweise den externen Rechteinhabern. Das Veröffentlichen von Bildern in Print- und Online-Publikationen sowie auf Social Media-Kanälen oder Webseiten ist nur mit vorheriger Genehmigung der Rechteinhaber erlaubt. [Mehr erfahren](#)

Conditions d'utilisation

L'ETH Library est le fournisseur des revues numérisées. Elle ne détient aucun droit d'auteur sur les revues et n'est pas responsable de leur contenu. En règle générale, les droits sont détenus par les éditeurs ou les détenteurs de droits externes. La reproduction d'images dans des publications imprimées ou en ligne ainsi que sur des canaux de médias sociaux ou des sites web n'est autorisée qu'avec l'accord préalable des détenteurs des droits. [En savoir plus](#)

Terms of use

The ETH Library is the provider of the digitised journals. It does not own any copyrights to the journals and is not responsible for their content. The rights usually lie with the publishers or the external rights holders. Publishing images in print and online publications, as well as on social media channels or websites, is only permitted with the prior consent of the rights holders. [Find out more](#)

Download PDF: 03.04.2026

ETH-Bibliothek Zürich, E-Periodica, <https://www.e-periodica.ch>

retroviruses (4), as these would induce primary tumour transformation.

Microscopically, the tumour mass is covered by a hyperplastic respiratory epithelium, while on the inside of the lamina propria there is loose connective tissue rich in oedematous liquid which is P.S.A. positive. In the central part of this connective stroma, marked neoplastic glandular development is evident in the form of numerous acinotubular glandular structures of various sizes, with an irregular lumen occupied by cellular debris and an acidophilic, P.A.S. positive substance. There were neoplastic structures surrounded by intense lymphocyte and plasma cell infiltration. Other glandular structures were clearly cyst-like, with a planocuboidal epithelium, but in no case did they exhibit any cellular reaction.

Ultrastructurally, it could be seen that the tumour mass was covered by a hyperplastic respiratory epithelium, in which ciliated mucous cells with microvilli could be distinguished. Numerous plasma cells were found within the mass. These had a highly-developed granular endoplasmic reticulum, and the cisternae, whose core was fairly

electron dense, were considerably dilated. This could suggest the development of an important immune response from the neoplastic tissue. Equally evident was the presence of numerous multinucleated cells with irregular nuclei and a dilated granular endoplasmic reticulum.

Many viral particles were present, both in the intracellular and extracellular spaces. They were coated with a capsid and the core was moderately electron dense. These particles were always found in dense aggregates.

References

1. *Yonemichi H.* et al. (1978): *Am. J. Vet. Res.* 39, 1599-1606. — 2. *Rings D. M.* et al. (1980): *J.A.V.M.A.* 178, 737-738. — 3. *McKinnon A. D.* et al. (1982): *Can. Vet. J.* 23, 88-94. — 4. *Heras M. y cols.* (1985): *Med. Vet.* 2, 281-290. — 5. *Nieto J. M. y cols.* (1980): *Vet. Praxis* 2, 50-53. — 6. *Gazquez A.* et al. (1990): *Vet. Pat.* (In Press). — 7. *Sabatini D. D.* et al. (1963): *J. Cel. Biol.* 17, 19-58.

Dep. Vet. Pathology – Faculty of Veterinary Medicine – Naples University, Italy

ATYPICAL BASAL BODIES IN THE OVIDUCTAL MUCOSA (AMPULLA) OF GILTS WITH PRIMARY CILIARY DYSKINESIA (PCD)

F. Roperto, P. Galati, P. Maiolino, S. Papparella

The basal bodies/centrioles have a remarkable degree of constancy in size, shape, location and ultrastructure, so that atypical ones are very rarely seen in normal and pathological tissues.

Abnormalities of the basal bodies are more frequently observed in the «immotile cilia syndrome» in human and canine cases.

We describe atypical basal bodies in the oviductal mucosa of gilts affected by the primary ciliary dyskinesia (PCD).

In fact, we examined 500 cross-sectioned basal bodies and found roughly 3% of atypical basal bodies.

Defective basal bodies of so-called «half-centrioles» type were present in a fairly high percentage (1.8%).

Other abnormalities were represented by the distortion of geometrical configuration, the presence inside the lumen of electron-dense granular material. Only one basal body was characterized by 8 triplets and one singlet.

We discuss this report on the basis of the most recent genetic studies about the molecular composition of basal bodies/centrioles.

Med. Inst. Umwelthygiene, Düsseldorf, FRG

EXPERIMENTALLY INDUCED LIVER GRANULOMAS AFTER LONG-TERM INHALATION OF QUARTZ IN NON-HUMAN PRIMATES

M. Rosenbruch

Extrapulmonary lesions of silicosis are well known in human pathology. They mainly occur in the liver, spleen and bone marrow (2, 6). In experimental medicine, hepatic granulomas could be induced by intravenous injection of silica in rats and mice (3, 4). The experiments reported here were carried out to study the effect of simultaneous exposure to quartz and excess pressure on the development of interstitial lung fibrosis. Additionally to alterations of lungs and lung associated lymph nodes, quartz induced liver lesions were detectable (5).

Material and methods

Cynomolgus monkeys were exposed for 26 months, 5 days per week and 8 hours per day to conditions listed below:

group	n	quartz (mg/m ³)	pressure (bar)
I	5	—	1.0
II	7	5.0	1.0
III	4	5.0	2.5
IV	5	—	2.5

At the end of the study, computed tomography as well as X-ray examination were undertaken. The respiratory tract was fixed by instillation. Additionally, a retrograde perfusion via the abdominal aorta was carried out. The morphologic and morphometric evaluation was done on paraffin embedded histological sections stained with haematoxylin-eosin (H&E) and after silver impregnation according to Gomori. Morphometric evaluation was carried out with the

ASM-68K (Analyse-System Manuell, Fa. Leitz) to determine the number and the amount of quartz induced reaction areas as percentage of slide area. For ultrastructural investigations tissue was plastic embedded (Durcupan-ACM, Fluka) and semithin sections (1µm) were stained with methylene-blue /AzurII. Ultrathin sections were post-fixed with osmium tetroxide and contrasted with uranyl acetate and lead citrate.

Results

Histomorphology: The liver of animals from groups I and IV reveals the normal hepatic structure. Silver impregnation shown a homogeneous black stained network. In the liver of all dust exposed animals numerous reaction areas of various size are obvious (Fig. 1). The smallest areas are clusters of cells. Phagocytosed quartz particles in the macrophages can be seen best in polarized light. Bigger roundish or oval areas predominantly consist of macrophages and fibroblasts, together with some polymorphonuclear leucocytes and lymphocytes. In silver impregnation, clearly visible nets of fibers can be seen. Some areas reveal many collagenous fibers. Liver cells surrounding these fibrotic granulomas show severe signs of degeneration.

Electron microscopy: TEM evaluation demonstrates quartz within the phagocytes, in sinuses as well as in granulomatous reaction areas. Furthermore in marginal zones of the reaction areas degenerative changes of the hepatocytes and proliferation of collagenous fibers are obvious.

Morphometry: Evident differences occur between the two dust exposed groups. The amount of granulomatous reaction areas in animals exposed to quartz dust only is 2.5 fold higher than after additional exposure to excess pressure.

Discussion

The morphology of liver granulomas reported here resembles hepatic lesions in man as well as in rats and mice, due to various kinds of occupational dust exposure (1, 6) and intravenous injection of silica (3, 4), respectively. Inhalation experiments did not reveal hepatic granulomas due to quartz of similar severity, yet. Additionally to lungs, lung associated lymph nodes and liver, quartz containing cells were detectable in the mesenterial lymph nodes and spleen (5). Different pathogenetic pathways have been discussed, but the lympho-hematogenous spread is the most probable route (6). The results of morphometric evaluation of hepatic lesions are comparable

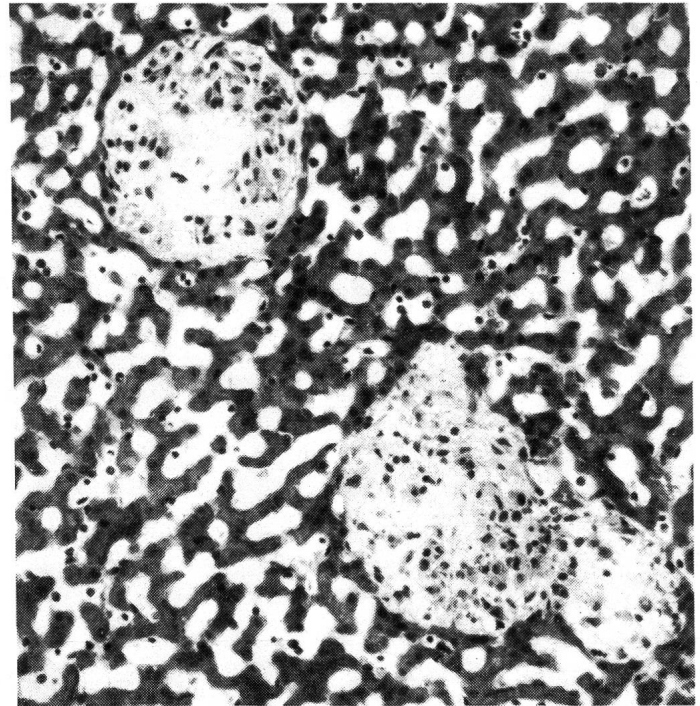


Fig. 1: Liver granulomas (H&E)

to those of lung granulomas (5). Finally, it has to be realized that due to the inhalation of fibrotic dusts, additionally to lung fibrosis, hepatic disorders may occur. These hepatic changes, including the development of granulomas, possibly cause structural as well as biochemical alterations, and may have a marked influence on the clinical symptoms.

References

1. Carmichael G. P. et al. (1980): Am. J. Clin. Pathol. 73, 720-722. — 2. Eide J. et. al. (1984): Histopathol. 8, 693-703. — 3. Kanta J. et al. (1986): Brit. J. Exp. Path. 67, 889-899. — 4. Rivers D., Morris T. G. (1958): In: Die Staublungenerkrankungen Band III: 66, Hrsg. Jötten und Klosterkötter; S. 181-189, Steinkopff Verlag, Darmstadt. — 5. Rosenbruch M. et al. (1988): Proc. VIIth Int. Pneumocon. Conf., Pittsburgh, in press. — 6. Slavin R. E. et al. (1985): Hum. Pathol. 16, 393-412.

Institute of Veterinary Pathology, University of Berne, Switzerland

IN VIVO NEUTROPHIL MOBILIZATION AFTER INTRADERMAL INJECTION OF COMPLEMENT FACTORS AND ENDOTOXIN: FUNCTIONAL DIFFERENCES BETWEEN NEWBORN CALVES AND ADULT CATTLE

D. Roth, R. Zwahlen

The high mortality of neonates due to bacterial infections is partly attributed to abnormalities in the host defense system, particularly to incompetence of neonatal phagocytes. We demonstrated earlier *in vitro* that bovine neonatal neutrophils (N-PMN) have an enhanced migratory capacity in a chemotaxis assay, thus representing a major

functional difference to N-PMN of other species. This hyperirritability status of bovine N-PMN should function to enhance inflammatory defense mechanisms, although clinical findings suggest the contrary. We therefore conducted the following study to assess the mobilization of intradermal neutrophils by chemotaxins: 5 healthy crossbred newborn calves and 5 healthy adult crossbred cows wer-