

Zeitschrift: Schweizer Archiv für Tierheilkunde SAT : die Fachzeitschrift für Tierärztinnen und Tierärzte = Archives Suisses de Médecine Vétérinaire
ASMV : la revue professionnelle des vétérinaires

Herausgeber: Gesellschaft Schweizer Tierärztinnen und Tierärzte

Band: 132 (1990)

Heft: 8

Artikel: Exocytosis of enterochromaffin-like (ECL) cells in rat fundic mucosa after potent acid inhibition

Autor: Rohr, I. / Tuch, K.

DOI: <https://doi.org/10.5169/seals-593698>

Nutzungsbedingungen

Die ETH-Bibliothek ist die Anbieterin der digitalisierten Zeitschriften auf E-Periodica. Sie besitzt keine Urheberrechte an den Zeitschriften und ist nicht verantwortlich für deren Inhalte. Die Rechte liegen in der Regel bei den Herausgebern beziehungsweise den externen Rechteinhabern. Das Veröffentlichen von Bildern in Print- und Online-Publikationen sowie auf Social Media-Kanälen oder Webseiten ist nur mit vorheriger Genehmigung der Rechteinhaber erlaubt. [Mehr erfahren](#)

Conditions d'utilisation

L'ETH Library est le fournisseur des revues numérisées. Elle ne détient aucun droit d'auteur sur les revues et n'est pas responsable de leur contenu. En règle générale, les droits sont détenus par les éditeurs ou les détenteurs de droits externes. La reproduction d'images dans des publications imprimées ou en ligne ainsi que sur des canaux de médias sociaux ou des sites web n'est autorisée qu'avec l'accord préalable des détenteurs des droits. [En savoir plus](#)

Terms of use

The ETH Library is the provider of the digitised journals. It does not own any copyrights to the journals and is not responsible for their content. The rights usually lie with the publishers or the external rights holders. Publishing images in print and online publications, as well as on social media channels or websites, is only permitted with the prior consent of the rights holders. [Find out more](#)

Download PDF: 18.01.2026

ETH-Bibliothek Zürich, E-Periodica, <https://www.e-periodica.ch>

— above all — in MPS, mainly in Kupffer cells. Subsequent Prussian-blue staining revealed that not only the localizations mentioned showed higher stainability, but also the cytoplasm of the hepatocytes themselves, and that the pigment represented iron. Massive deposits of iron-positive cells were also found in the sinuses of the lymph nodes. The pigment deposits were not confined to inguinal or popliteal lymph nodes (which would be understandable, being the direct places of resorption after intramuscular injection), but, in some cases affected lymph nodes throughout the body. Further deposits of pigment were found in the spleens, the skeletal muscles of the hind legs, in the perineural connective tissue — especially of the sciatic nerve(s), within reticulocytes of the bone marrow, and sometimes in endothelial cells of adrenocortical sinuses. However, the central findings were pigment deposits in the kidneys of again 94 out of 96 animals. Interestingly enough, the pigment was located mainly intraglomerularly, and only isolated deposits could be detected in mesangial cells at the glomerular vascular pole. The Prussian-blue reaction turned out to be positive, identifying the pigment as trivalent iron. The glomeruli concerned were located mainly in the inner or cortical region, while in the outer glomeruli only a light yellow pigment could be detected. The Turnbull-blue reaction showed this to be protein-bound or bivalent iron. Furthermore focal sclerotic glomeruli were observed, mainly located in the juxtamedullary zone, which contained iron pigment as well. As a further consequence of glomerular ischemia due to vascular occlusion, a periglomerular fibrosis could be shown in some cases.

Discussion

Well-known examples of excessive iron storage in man are thalassemia and especially idiopathic hemochromatosis. The latter disease usually results in a cirrhotic transformation of the liver, of which the pathogenesis is still unclear. Massive iron deposits in the liver and kidneys of animals are familiar after chronic hemorrhaging, in equine infectious anemia, and due to copper or cobalt deficiency in swine and goats. In the kidneys, siderin was located mainly in the epithelial

cells of proximal tubules or Henle's loops. Iron deposits were not observed intraglomerularly, either in the diseases mentioned or in experimental studies, which attempted to simulate idiopathic hemochromatosis by means of chronic parenteral iron administration to rats and dogs. With respect to intraglomerular iron-(pigment-)storage in man and animals, the literature search found only two references (1, 2). Both give accounts of iron overload with subsequent glomerulosclerotic changes in pigs, and this pathological alteration seems to be specific to this species.

A possible explanation of the glomerular sclerosis is, we think, the age of the glomeruli. At the time of iron injection, some of the glomeruli have not matured (3, 4) and therefore the endothelium of the immature glomerulus, which is mostly unfenestrated, offers a barrier to the ferritin passage (5). The ontogenetically older glomeruli of the juxtamedullary region, which were more often sclerotic, perhaps received a higher iron concentration, and their mesangial cells, capable of phagocytosis, may have filtered out molecules, which were too large to pass through the endothelial pores. This large mass of deposits may possibly lead to the subsequent glomerulosclerosis. On the other hand, it is also conceivable, that the transferrin's iron-binding capacity is exhausted. Some observations indicate that the administered iron is not mobilized. Certainly there is no need for its mobilization because of the high iron supply of commercial feeds. For these reasons, and that because mini-pigs grow more slowly than farm swine, we think that for animals of this strain one additional iron injection, containing 50 mg available iron, should be enough to prevent iron deficiency anemia and to avoid kidney disturbances.

References

1. Paul I., Bazgan O. (1971): *Lucrari Stiintifice. II. Zootehnie-Medicine Veterinara* 311–314. — 2. Katkiewicz M. et al. (1986): *Polskie Archiwum Weterynaryjne* 25, (4) 75–84. — 3. Friis C. (1980): *J. Anat.* 130, 513–526. — 4. Wesemeier H. et al. (1986): *Arch. exper. Vet. med.* 40, 910–919. — 5. Farquhar M. G. et al. (1960): *J. Exp. Med.* 113, 47–66.

Institute of Pathology and Toxicology, Byk Gulden Pharmaceuticals, Hamburg, FRG

EXOCYTOSIS OF ENTEROCHROMAFFIN-LIKE (ECL) CELLS IN RAT FUNDIC MUCOSA AFTER POTENT ACID INHIBITION

I. Rohr, K. Tsch

Enterochromaffin-like (ECL) cells of the rat gastric fundus display a high degree of degranulation and a marked increase of exocytosis after short-time treatment with B831-78, a potent H^+ , K^+ -ATPase inhibitor. (1).

The present paper describes the mode of granula release of rat fundic ECL cells.

Material and methods

4 female rats (Sprague-Dawley) were used for electron microscopic investigation of the fundic ECL cells. 2 animals were treated with 50 mg B831-78 per kg body weight daily for two days and 2 animals served as controls receiving vehicle only.

24 hours after the last dosing the rats were anesthetized with ether and the stomachs perfused via the abdominal aorta with glutaraldehyde 5%. Specimens from the fundic mucosa were embedded in Epon and ultrathin sections were stained with uranyl acetate and lead citrate.

Results

After 2 administrations of B831-78 the ECL cells showed a massive granule depletion and an increased number of exocytic figures. Lysosomal structures occurred more frequently in ECL cells of treated animals. The density of the typical vesicular type granules was markedly reduced and a major part of the granules was empty. The exocytotic figures opened mainly towards chief cells, occasio-

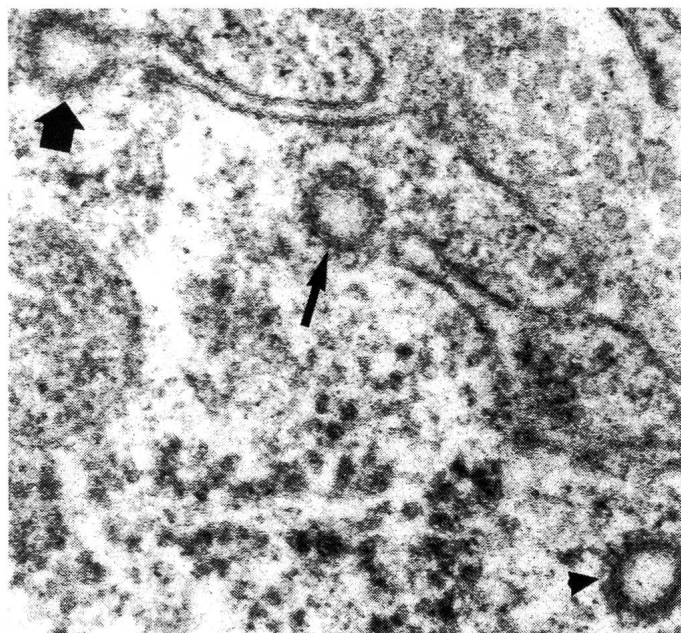


Fig. 1: ECL-cell: invagination of the basal plasma membrane with a coated segmentation (big arrow); coated vesicle in the immediate vicinity of a plasma membrane invagination (small arrow); coated vesicle near the basal plasma membrane (arrow head). 136 000X

nally towards the basal lamina and seldom towards parietal cells. The most interesting observation was the occurrence of smooth invaginations of the plasma membrane with coated segmentation and coated vesicles in the vicinity (fig. 1).

Dpt. Histología y Anatomía Patológica. Facultad de Veterinaria, Cáceres. España.

EXPERIMENTAL INTOXICATION WITH LEAD NITRATE: HISTOLOGICAL STUDIES OF HEPATIC CELLS FROM TENCH

V. Roncero, A. Gazquez, J. A. Vicente, E. Duran, J. Masot, E. Redondo

Lead, one of the highly toxic heavy metals, is found in increasing amount in living matter, in both marine and terrestrial ecosystems, largely due to the continuous and increasing pollution of the environment in industrialised regions all over the world.

The abundant sources of environmental pollution involving lead include fumes from combustion engines, the dumping of industrial waste, the use of lead piping for water supplies and the use in the past of lead-based paints. This pollution gives rise to the progressive accumulation of lead compounds in the aquatic environment (1, 2). Because they are in direct and continuous contact with water, teleost act as ideal primary biological indicators of the degree of pollution present in an aquatic ecosystem (3). This article describes hepatic lesions in tench following acute experimental lead nitrate poisoning – due to the consumption of large amounts of lead over a short period of time – and also considers the extrapolation of the results to other animals.

Discussion

Neuroendocrine cells release their products by exocytosis (2, 3). From their findings on endocrine cells of the pituitary gland and adrenal medulla Douglas et al (2) and Nagasawa (3) postulated the exocytosis-vesiculation-sequence (EVS). According to the EVS, exocytosis proper is followed by the sementation of coated vescles from the fusionated granule. The vesicles move into the cytoplasm where they lose their coats and become smooth vesicles that are partly taken up by lysosomes for degradation.

The appearance ot exocytotic figures of the rat fundic ECL cells and the enhanced proportion of lysosomes after treatment with B831-78 is in accordance with the EVS.

Conclusion

Under conditions of potent acid suppression the ECL cells in the rat gastric fundus show a massive degranulation and an increased number of exocytotic figures. The occurrence of smooth invaginations with coated segmentation of vesicles for the first time gives evidence that the EVS applies to the rat fundic ECL cells.

References

1. Rohr I. (1990): Vet. med. Diss. Hannover. —
2. Douglas W. W. et al. (1971): Man. Soc. Endocrinol. 19, 353–378. —
3. Nagasawa J. (1977): Arch.Histol. Jpn. 40, 31–47.

Material and methods

The adult tench (*Tinca tinca*, L.) used in this experiment were sacrificed as shown in Table 1.

Table 1

Batch	No. Tench	Duration of Exposure
I	3	24 h.
II	3	48 h.
III	3	4 days
IV	3	7 days
V	3	9 days
VI	3	12 days
VII	3	15 days
Control	22	same as principals
Total	43	