

**Zeitschrift:** Schweizer Archiv für Tierheilkunde SAT : die Fachzeitschrift für Tierärztinnen und Tierärzte = Archives Suisses de Médecine Vétérinaire  
ASMV : la revue professionnelle des vétérinaires

**Herausgeber:** Gesellschaft Schweizer Tierärztinnen und Tierärzte

**Band:** 131 (1989)

**Heft:** 9

**Artikel:** The woolly monkey (*Lagothrix Lagothricha*) : a possible model for human hypertension research

**Autor:** Müller, M. / Heldstab, A. / Luginbühl, H.

**DOI:** <https://doi.org/10.5169/seals-592651>

### **Nutzungsbedingungen**

Die ETH-Bibliothek ist die Anbieterin der digitalisierten Zeitschriften auf E-Periodica. Sie besitzt keine Urheberrechte an den Zeitschriften und ist nicht verantwortlich für deren Inhalte. Die Rechte liegen in der Regel bei den Herausgebern beziehungsweise den externen Rechteinhabern. Das Veröffentlichen von Bildern in Print- und Online-Publikationen sowie auf Social Media-Kanälen oder Webseiten ist nur mit vorheriger Genehmigung der Rechteinhaber erlaubt. [Mehr erfahren](#)

### **Conditions d'utilisation**

L'ETH Library est le fournisseur des revues numérisées. Elle ne détient aucun droit d'auteur sur les revues et n'est pas responsable de leur contenu. En règle générale, les droits sont détenus par les éditeurs ou les détenteurs de droits externes. La reproduction d'images dans des publications imprimées ou en ligne ainsi que sur des canaux de médias sociaux ou des sites web n'est autorisée qu'avec l'accord préalable des détenteurs des droits. [En savoir plus](#)

### **Terms of use**

The ETH Library is the provider of the digitised journals. It does not own any copyrights to the journals and is not responsible for their content. The rights usually lie with the publishers or the external rights holders. Publishing images in print and online publications, as well as on social media channels or websites, is only permitted with the prior consent of the rights holders. [Find out more](#)

**Download PDF:** 10.08.2025

**ETH-Bibliothek Zürich, E-Periodica, <https://www.e-periodica.ch>**

# THE WOOLLY MONKEY (LAGOTHRIX LAGOTHRICHA): A POSSIBLE MODEL FOR HUMAN HYPERTENSION RESEARCH

M. MÜLLER, A. HELDSTAB, H. LUGINBÜHL

## SUMMARY

The anatomical-pathological findings of 15 woolly monkeys were comparable with those described in man with essential benign or malignant hypertension. Kidneys revealed arterio- and arteriolosclerosis or an onion peel-like proliferation, in some cases necrotizing endarteritis. Obesity due to restricted physical activity, unnatural feeding, and psychical and physical stress could have contributed to the development of this condition. Further, high vulnerability of the genus woolly monkey is postulated. Thus, essential hypertension of woolly monkeys appears to be a multifactorial disease.

**KEY WORDS:** essential hypertension – pathology of kidneys – woolly monkey

## DER WOLLAFFE (LAGOTHRIX LAGOTHRICHA): EIN MÖGLICHES TIEMODELL IN DER HYPERTONIEFORSCHUNG

Die pathologisch-anatomischen Befunde bei 15 Wollaffen waren mit der benignen und malignen Form der essentiellen Hypertonie des Menschen vergleichbar. Arterio- und Arteriolosklerose, sowie eine «onion peel-like» proliferative Endarteritis, in einigen Fällen nekrotisierend, waren charakteristische Nierenläsionen. Obesitas infolge geringer körperlicher Aktivität, unphysiologischer Ernährung und psychischer wie physischer Stress waren prädisponierende Faktoren. Eine erhöhte Anfälligkeit der Spezies Wollaffe wird postuliert. Die essentielle Hypertonie der Wollaffen scheint auf einer multifaktoriellen Genese zu basieren.

**SCHLÜSSELWÖRTER:** Essentielle Hypertonie – Nierenpathologie – Wollaffe

## INTRODUCTION

Arterial hypertension of man, a well-known disease complex, is classified into essential (primary) and symptomatic (secondary) hypertension, the latter subdivided into renal, endocrine, neurogenic, cardiovascular hypertension, and the miscellaneous hypertensive syndrome comprising metabolic and toxic disorders. Differences in clinical course and pathology in primary and secondary hypertension lead to differentiation between a benign and a malignant form (Cottier, 1980; Meadows, 1973).

Spontaneous essential hypertension in man has a morbidity of 15–30%. Reports on spontaneous hypertension in animals are rare and limited to Syrian hamsters (Slauson et al., 1978), selectively bred rats (Gattone et al., 1983; Somova et al., 1975), guinea pigs (Takeda, Grollman, 1970) and an adult chimpanzee (Stout and Lemmon, 1971). Further, high blood pressure is suggested to be the origin of a familiar renovascular disease in Norwegian elkhounds (Finco et al.,

1970). Experimental hypertension has been induced in mice (Henry et al., 1967), rats (Seewer, 1973), sheep (Parker et al., 1966) and nonhuman primates (Benirschke et al., 1978; Bourne, 1973; Hill and Thomsen, 1972; Mitchell et al., 1982).

In this communication, clinical history and pathological changes of adult woolly monkeys at the Basle Zoological Garden are compared with aspects of spontaneous essential benign and malignant hypertension in man.

## MATERIALS AND METHODS

A colony of woolly monkeys was observed clinically at the Basle Zoological Garden for 15 years. Tissues from 15 adult animals, three males and twelve females, which died spontaneously, were fixed in 4% formalin, embedded in paraffin, sectioned at 5 µm and routinely stained with van Gieson, periodic acid-Schiff (PAS), and a modified Movat silver impregnation. Some kidney specimens were post-fixed in 1% osmiumtetroxide, embedded in Spurr medium and sec-

tions stained with toluidine blue. Routine bacteriological cultures were made on spleen, liver, kidney, lung and, in special cases, also on brain and small intestine.

Body-, heart- and kidney weights of woolly monkeys have been recorded. The equation of the linear function in Fig. 15 is  $y = a + b$ ; the solution is

$$a = \frac{m \sum x_i y_i - \sum x_i \sum y_i}{m \sum x_i^2 - (\sum x_i)^2} = 4,175$$

$$b = \frac{1}{m} (\sum y_i - a \sum x_i) = 2,430$$

Hematology, blood chemistry and urine analysis have been worked up in ten animals. Blood pressure could be measured only in animal 15.

## RESULTS

### Clinical

The monkeys had a terminal period of weight loss (No. 4: 3 kg in a 3-month period), apathy, and anorexia (Fig. 16). They appeared to have had headache for months, retracting the head deep between their shoulders or supporting it with their hands. Animals 13 and 14 became unable to climb or snatch at objects properly. For some time before death, animal 13 seemed to be totally blind and was unilaterally paralyzed. Hemorrhagic diarrhea was regularly combined with vomitus and hiccup. Breathing was labored. Urea nitrogen varied between 3,2 and 56,8 mmol/l (normal: 1,7–7,5 mmol/l). Renin activity was normal or suppressed (5–0,9 ng/ml/hr). Occasionally, proteinuria (–5 g/l), hematuria, or bacteriuria were recognized. One month before death, blood pressure of the anesthetized animal 15 was 180/130 mmHg.

### Pathological changes

Animals were obese (eight), normal (two) or underweight (five). The kidney weight varied between 14 and 30 g. Normal and contracted kidneys were yellowish brown with fine granulated surfaces. Irregular scars and reduced cortical widths were seen (Fig. 1). Histological studies revealed conspicuous arteriosclerotic lesions in arteries of the cortex and cortico-medullary region. Arcuate arteries had duplication of the internal elastic lamina and mild to severe fibrous intimal thickening, sometimes with a hypertrophic media (Fig. 2). Interlobular arteries and afferent arterioles were segmentally occluded by eccentric or concentric fibrinoid intimal deposits (Fig. 3, 4, 6). A few interlobular arteries were occluded by thrombi. Focal granular fibrinoid necrosis (Fig. 3) with intramural hemorrhage (Fig. 5, 7, 8) fa-

vored the development of aneurysms as a result of decreased stability of the vascular wall (Fig. 5). The effect of these stenosing deposits was regularly accompanied by concentrically arranged mucoid or fibrous intimal hyperplasia (Fig. 5, 6). These onion peel-like vessels often had undergone necrosis with extravasation of erythrocytes into the surrounding tissue (Fig. 5). Depending on the severity of intimal and subintimal lesions, the media was atrophic, hyperplastic, or sclerotic. The associated tubular atrophy rendered the vessels prominent and crowded (Fig. 4).

Nephrons were segmentally damaged due to ischemia. Collapsed glomeruli were often associated with wrinkled glomerular basement membranes, hyalin, partly collagenous material in the dilated capsular spaces, and large, fibrous Bowman's capsules (Fig. 10, 11). Complete ischemic glomerular destruction and fibrosis were seen (Fig. 9). In radial sclerotic areas most tubules were atrophic and replaced by fibrous tissue. Foci of lymphocytic and plasma-cellular infiltration were regularly seen. Ectatic tubules contained hyalin casts. Animals 13 and 14 had segmental or panglomerular necrotic tufts with focal microthrombi and hemorrhage consequent to arterial necrosis (Fig. 12, 13). Apart from these ischemic lesions, a disseminated focal membrano-proliferative process caused enlarged glomeruli. Segmentation of tufts with solid and hypercellular areas were characteristic (Fig. 14). The juxtaglomerular apparatus was not prominent.

The multifocal tubulo-interstitial polymorphonuclear inflammatory response in animal 3 and 7 was associated with bacterial infection. Fibrinoid arterio- and arteriosclerosis or necrosis caused hemorrhage in the spleen, pancreas, liver, gastrointestinal tract, ovary, and brain. Left ventricular hypertrophy with pericardial effusion, heart failure cells in pulmonary alveoli, and acute to chronic congestion of the liver were further typical pathological features.

## DISCUSSION

Macroscopic and microscopic changes in our woolly monkeys are comparable with lesions of human essential benign and malignant hypertension: arterio- and arteriosclerosis, ischemic shrinking of glomeruli, and dilatation of glomerular capsules. These lesions develop progressively over a period of years (Anderson, 1980). Onion peel-like proliferative endarteritis, fibrinoid arterio- and arteriosclerosis and necrotic glomerular tufts are typical for malignant hypertension (Brenner and Rector, 1984). In man, this form is characterized by a relatively short clinical course of 6–9 months. Normal or suppressed serumrenin values together

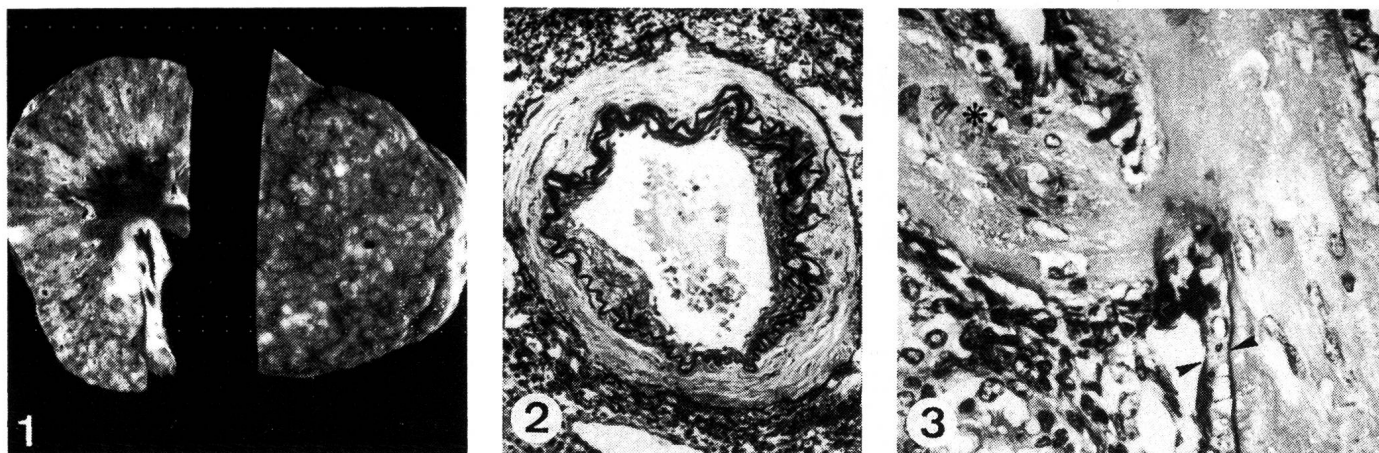


Fig. 1: Shrunken kidney with scar formation and granular surface.

Fig. 2: Arcuate artery with multiplication of internal elastic lamina and fibrous intimal proliferation (van Gieson elastica).

Fig. 3: Intimal fibrinoid necrosis (\*) and medial atrophy (arrows) of obliterated interlobular artery (van Gieson elastica).

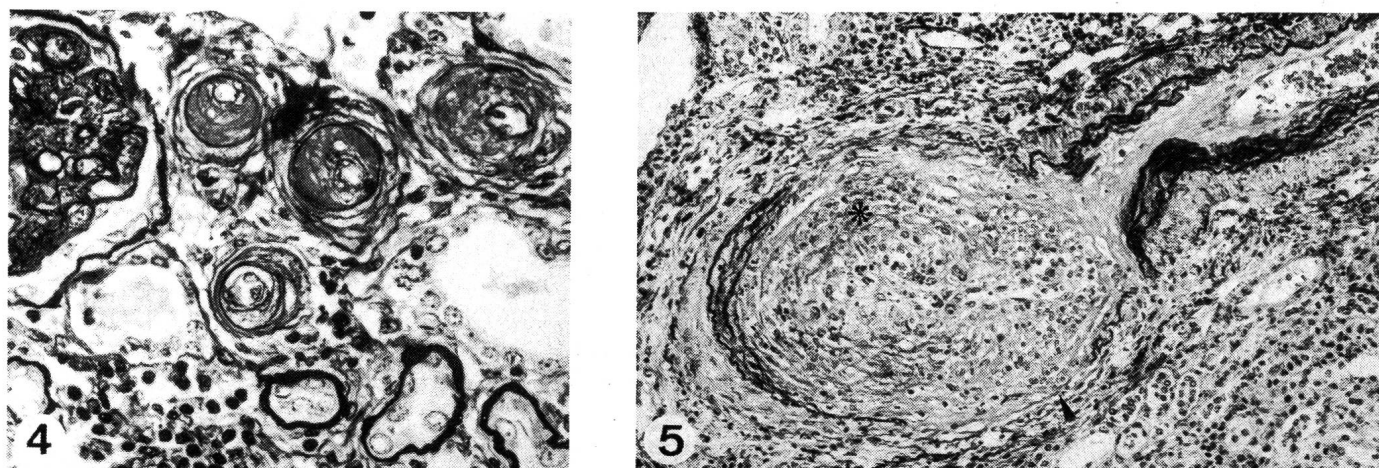


Fig. 4: Intimal eccentric hyalin deposits in a meandering afferent artery (Movat silver impregnation).

Fig. 5: Proliferative endarteritis (onion peel-like) of interlobular artery with necrosis of vessel wall (arrow) and fibrous intimal proliferation (\*) (van Gieson elastica).

with a morphologically inconspicuous juxtaglomerular apparatus are findings when benign hypertension proceeds to the malignant form. In man, the kidney size appears to be related to the duration of the malignant hypertensive disease (Brenner and Rector, 1984; Heptinstall, 1966). This correlation was not found in our monkeys.

As in man, the cause of death in woolly monkeys varies with malignant and benign hypertension: septicemia and cardiovascular accidents are complications of the benign form; renal failure with uremia, congestive heart failure, and hypertensive encephalopathy are complications of malignant hypertension (Anderson, 1980; Brenner and Rector, 1984; Heintz and Losse, 1969; Sambhi, 1980). Left ventricu-

lar hypertrophy, an important diagnostic feature in hypertensive man (Stuart et al., 1976) has regularly been seen in woolly monkeys. Woolly monkeys without the described pathological changes had a linear heart/body-weight correlation. In contrast, with one exception, all woolly monkeys with hypertension-like lesions had a strongly elevated heart weight (Fig. 15).

Human males are predisposed for hypertension. Among woolly monkeys considered hypertensive, 80% were females and 20% males. Males only developed lesions comparable with the benign, whereas those in six of nine females were comparable with the malignant form.



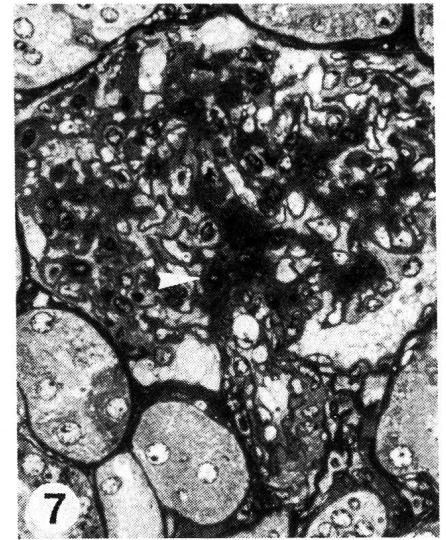
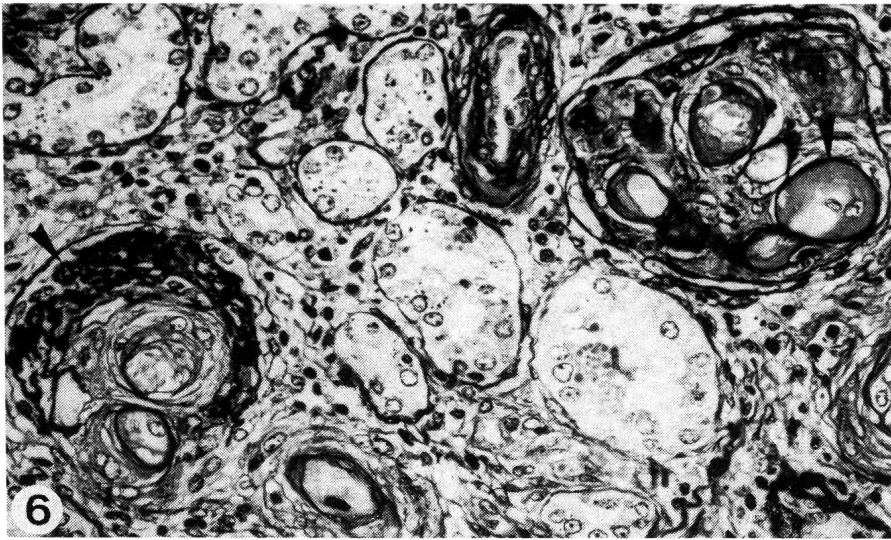


Fig. 6: Collapsed ischemic glomerular tufts with typical wrinkling of basement membranes (left arrow). Severe hyaline sclerosis of capillaries (right arrow) (PAS).

Fig. 7: Segmental granular fibrinoid necrosis of afferent arteriole (arrow) extending into glomerular tufts (semithin section, Toluidin blue).

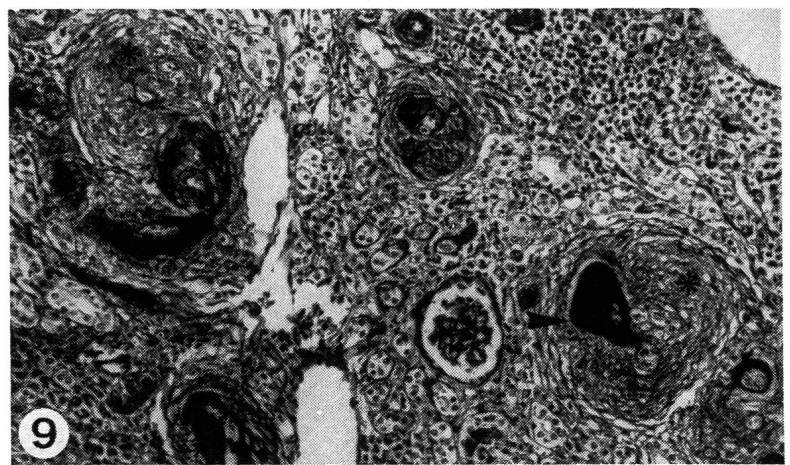
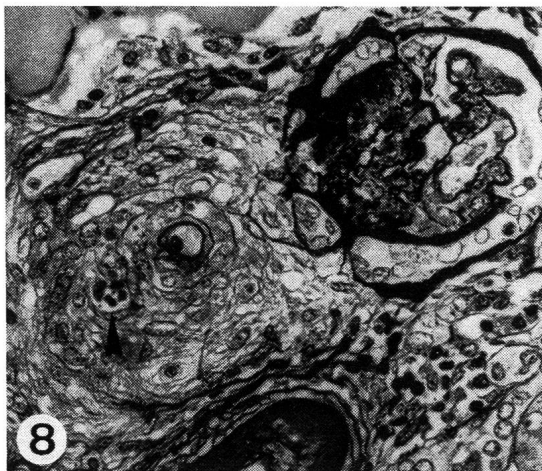


Fig. 8: Proliferative endarteritis of afferent artery with focal necrosis and extravasation of erythrocytes (arrow) (Movat silver impregnation).

Fig. 9: Obliterated afferent arteries (arrow) favouring progressive glomerulonephritis (\*) (PAS).

The minimal diastolic blood pressure in malignant hypertension in man varies according to author between 110–150 mmHg (Brenner and Rector, 1984; Heintz and Losse, 1969). Under anesthesia, a value of 130 mmHg had been measured in monkey 15. Anesthesia had no significant decreasing effect on blood pressure values in mice that had reached a stage of «fixed» hypertension (Henry et al., 1967). Essential hypertension is a multifactorial disease caused by environmental and genetic factors (Cottier, 1980; Heintz

and Losse 1969; Sambhi, 1980). Among acquired factors in man, obesity predisposes to hypertension. Most woolly monkeys of our colony reached an obese condition of twice the normal body weight of 7 kg (Fig. 16) (Berger and Tylinek, 1984; Frädrieh, 1973; Martin, 1978; Milton et al., 1984; Napier et al., 1967; Walker, 1964). In their natural habitat woolly monkeys are seasonal vegetarians, while fruits are available on which they accumulate subcutaneous fat (Heinemann, 1979; Hernandez-Camacho and Cooper, 1976; Jones,

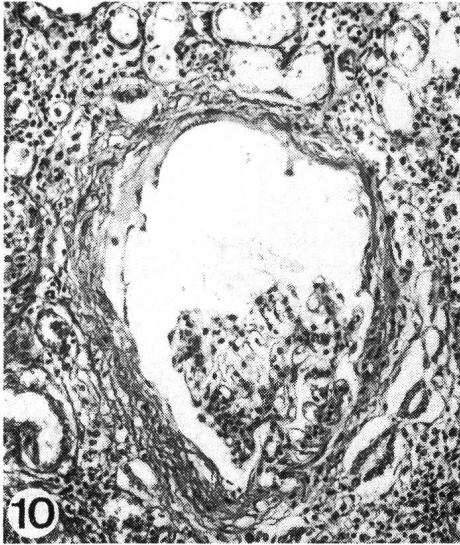

Fig. 10: Capsular space dilatation and contracted glomerular tufts. Mononuclear inflammatory response in the interstitium (van Gieson).

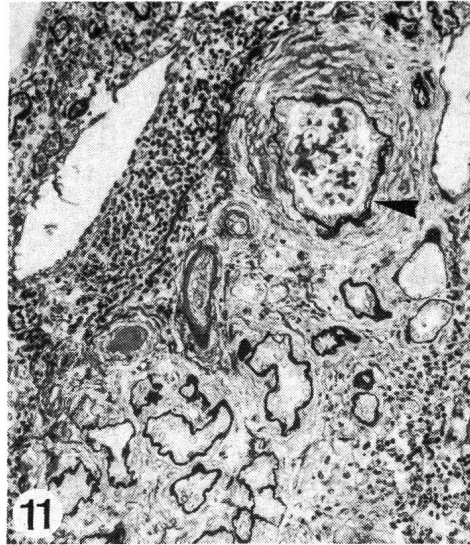

Fig. 11: Duplication of capsular basement membrane (arrow), periglomerular fibrosis, tubular atrophy and interstitial fibrosis (Movat silver impregnation).

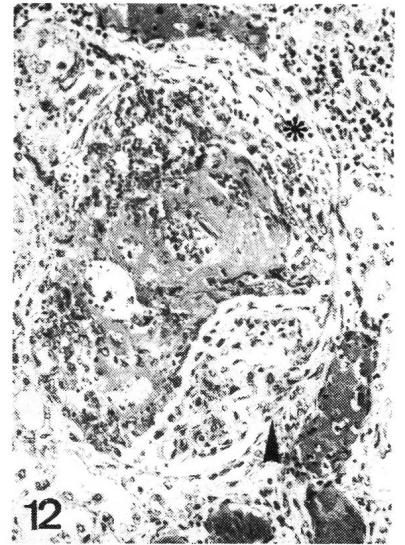


Fig. 12: Segmental fibrinoid necrosis of glomerular tufts. Local capsular adhesion (arrow) and crescent formation (\*) (HE).

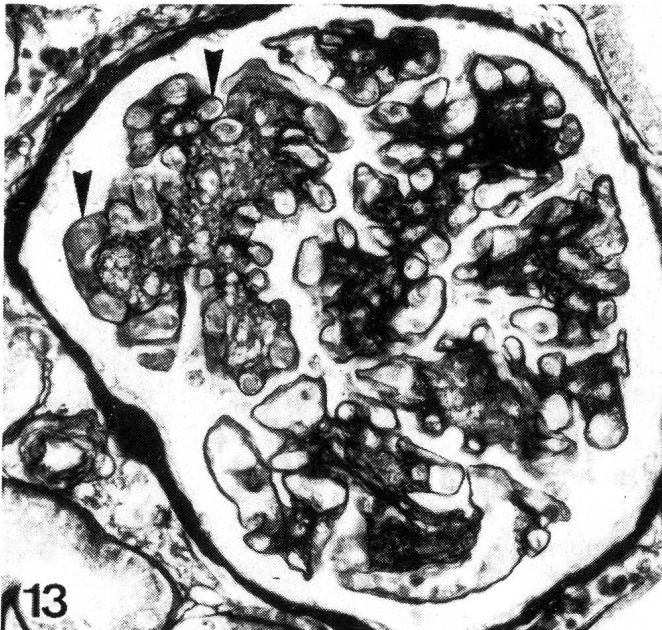


Fig. 13: Segmental obstruction of glomerular capillaries by fibrinous thrombi (arrows) (Movat silver impregnation).

1972). They are adapted to the intake of diets of extremely low caloric nutritive density; the rest of the year they are insectivorous (Milton and Nessimian, 1984; Portmann, 1970; Williams, 1967). In captivity there is no season of catching

and eating insects; the offer of fruits and vegetables is uniform during the whole year. Motion deficiency and unnatural feeding habits seem to play a key role in the development of overweight. In our monkeys the obesity maximum has regularly been followed by an interval of weight loss. In contrast to man this weight loss was not correlated to lesions compatible with malignant hypertension.

Psychical and physical stress are further factors promoting hypertension (Brenner and Rector, 1984; Cottier, 1980; Henry et al., 1967; Hill and Thomsen, 1972). Figure 17 shows the frequency of internal stressors as bites, births, and deaths as well as external stressors as therapies, change in group composition, or construction work. It is interesting that stress peaks coincided with the time during which the weights of several individuals deviated from the normal curve.

Fulfillment of requirement for space and physiological size of colonies seems to be essential for keeping and breeding woolly monkeys in captivity. Compared to a successful breeding colony in England (Williams, 1967), indoor and outdoor play areas for woolly monkeys at the Basle Zoological Garden are unsatisfactory. Insufficient space may be an additional stressor in our colony. Natural group size has been reported from several habitats as between four and seventyfive monkeys (Frey, 1982; Goodwin and Holloway,

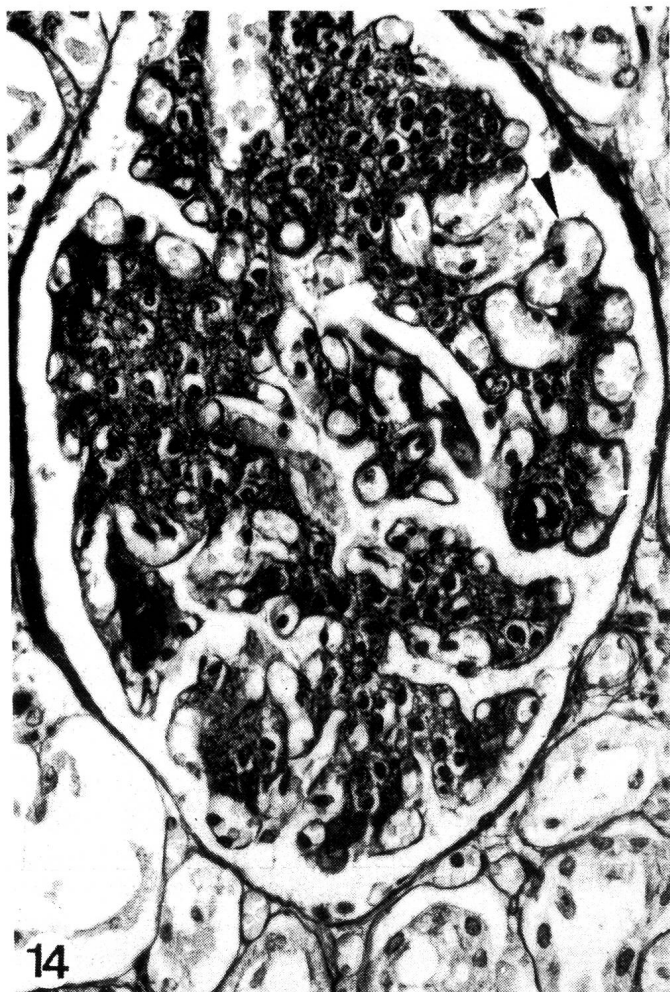

Fig. 14: Segmental mesangioproliferative glomerulonephritis and irregular distended capillaries (arrow) (HE).

1978; Heinemann, 1979; Hernandez-Camacho and Cooper, 1976; Mack and Kafka, 1977). With nine to fifteen animals, our colony lies within these limits.

In pregnant women, hypertension has severe consequences for the baby. From the second part of Fig. 17 it is obvious that the increasing number of abortions and stillbirths in our colony during the last few years made a successful rearing impossible. A third important factor in human hypertension is a familiar disposition (Cottier, 1980; Heintz and Losse, 1969). This does not appear to be the case in our monkeys. However, we postulate a high vulnerability of woolly monkeys to hypertension. This hypothesis has been recently confirmed by the observation of similar pathologic features in the Woodland Park Zoo (Seattle), the National Zoological Park (Washington, D. C.), the Pittsburgh Zoo, the Louisville Zoological Garden (Klein et al.,

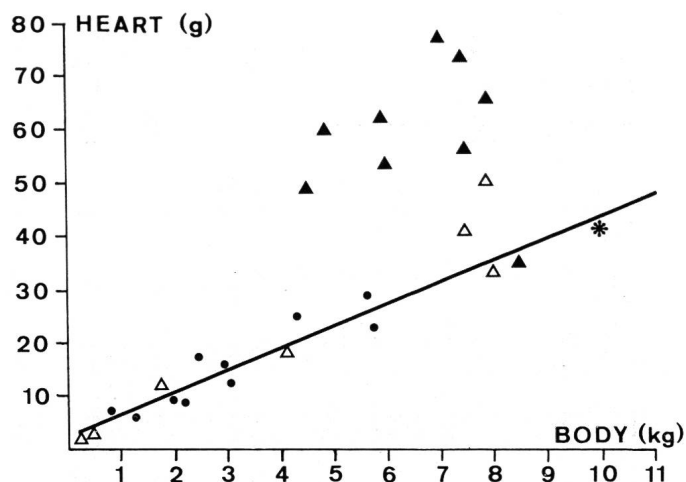


Fig. 15: Body and heart weight correlation of normo- and hypertensive monkeys

- ▲ = hypertensive woolly monkey
- △ = normotensive woolly monkey
- = cynomolgus monkey
- \* = spider monkey

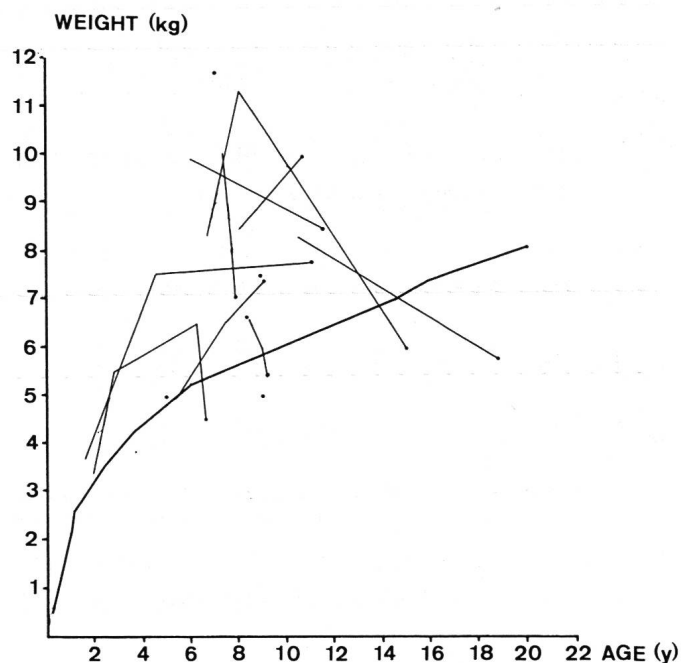


Fig. 16: Overweight, weight loss in hypertensive woolly monkeys

- = normotensive woolly monkey
- = hypertensive woolly monkey
- = exitus



## THE WOOLLY MONKEY – A MODEL IN HYPERTENSION RESEARCH

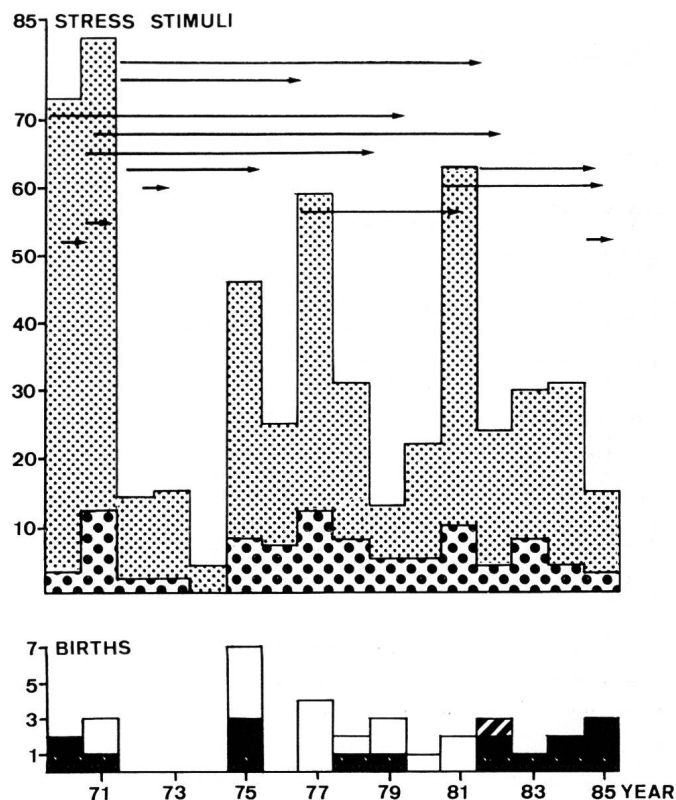
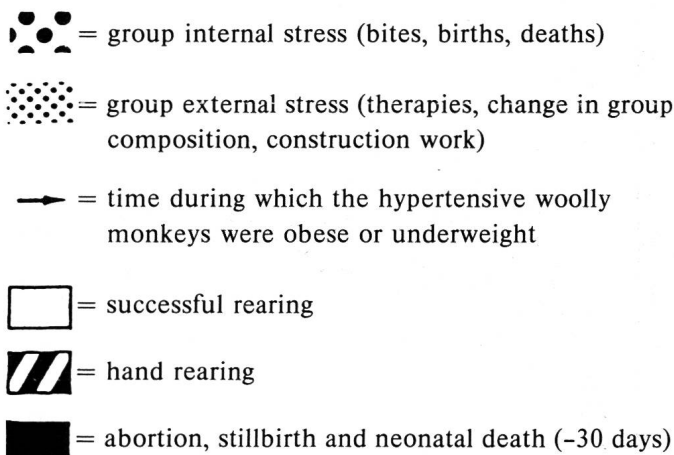


Fig. 17: Stress – and birth-frequency between 1970 and 1985



Stress peaks coincided with periods of body weight loss and increasing numbers of abortion and stillbirth.

1984) and in the Zoological Gardens of Zurich, Hannover, and Apeldoorn (personal communications).

Thus, the woolly monkey is an extremely stress-sensitive species. Its adaptability is not great enough to convert in captivity from a frustrated to a balanced, active group

member. The woolly monkey may be an adequate spontaneous animal model for research in human hypertensive disease.

When this study was finished, Giddens et al., (1987) reported on pathological changes in different organs of woolly monkeys considered hypertensive. The heterogeneous case material was derived from different US Zoological Gardens, and the authors did not discuss aspects of pathogenesis.

### REFERENCES

- Anderson J. R. (1980): Muir's Textbook of Pathology, 11th ed., Edward Arnold, London. — Berger G., Tylinek E. (1984): Das Grosse Affenbuch, Landbuch-Verlag, Hannover. — Benirschke K., Garner F. M., Jones T. C. (1978): Pathology of Laboratory Animals, Springer-Verlag, New York, Heidelberg, Berlin. — Bourne G. H. (1973): Nonhuman Primates and Medical Research, 252–253, Academic Press, London, New York. — Brenner B. M., Rector F. C. (1984): Arteriolar-nephrosclerosis. In: The Kidney, 2nd ed., 1684–1701, WB Saunders, Philadelphia. — Cottier H. (1980): Arterielle Hypertonie und Hypotonie im grossen Kreislauf. In: Pathogenese, 516–535, Springer-Verlag, Berlin. — Finco D. R., Kurtz H. J., Low D. G., Perman V. (1970): Familial renal disease in Norwegian elkhound dogs. *JAVMA* 156, 747–760. Frädrich H. (1973): Zooführer Säugetiere, Gustav Fischer-Verlag, Stuttgart. — Frey J. (1982): Verhaltensdifferenzierung und soziale Position in einer Wollaffengruppe (*Lagothrix lagothricha*). Diplomarbeit, Phil.-Nat. Fakultät, Universität Basel. — Gattone V. H., Evan A. P., Willis L. R., Luft F. C. (1983): Renal afferent arteriole in the spontaneously hypertensive rat. Hypertension – Giddens W. E., Combs C. A., Smith O. A., Klein E. C. (1987): Spontaneous hypertension and its sequelae in woolly monkeys (*Lagothrix lagothricha*). *Lab. Anim. Sci.* 37, 750–756. — Goodwin H. A., Holloway C. W. (1978): Red Data Book, Mammalia Vol. 1, International Union for Conservation of Nature and Natural Resources, Morges. — Heinemann D. (1979): Kapuziner-artige Neuweltaffen. In: Grzimeks Tierleben, eds Friedler, W., Gewalt, W., Grzimek, B., Heinemann, D., Herter, K., Thenius, E., Bd. 10, 310–347, Deutscher Taschenbuch-Verlag, München. — Heintz, R., Losse, H. (1969): Arterielle Hypertonie, Georg Thieme-Verlag, Stuttgart. — Henry J. P., Meehan J. P., Stephans P. M. (1967): The use of psychosocial stimuli to induce prolonged systolic hypertension in mice. *Psychosom. Med.* 24, 408–432. — Heptinstall R. H. (1966): Vascular disease of the kidney. In: The Kidney, eds Mostofi, F. K., Smith, D. E., 213–225, International Academy of Pathology Monograph, Baltimore. — Hernandez-Camacho



J., Cooper R. W. (1976): Neotropical primates, field studies and conservation. In: Proceedings of a Symposium on the Distribution and Abundance of Neotropical Primates, eds Thorington, R. W., Heltne, P. G., 61–63, National Academy of Sciences, Washington D. C. — Hill C. W., Thomsen C. E. (1972): Stress. In: Pathology in Simian Primates, ed Fiennes, R. N., part 1, 331–341, S Karger, Basel. — Jones C. (1972): Natural diets of wild primates. In: Pathology in Simian Primates, ed Fiennes, R. N., part 1, 58–77, S Karger, Basel. — Kissane J. M. (1985): Vascular renal disease. In: Anderson's Pathology, 8th ed., vol. 1, 750–756, VC Mosby, St. Louis. — Klein E. C., Giddens W. E., Combs C. A., Smith O. A., Wagner R. (1984): The pathology of hypertension in woolly monkeys (*Lagothrix lagothericha*). Proc. Ann. Meet. Am. Assoc. of Zoo Vet., Louisville KY. — Mack D., Kafka H. (1978): Breeding and rearing of woolly monkeys (*Lagothrix lagothericha*) at the National Zoological Park, Washington. In: International Zoo Year Book, vol. 18, ed Olney, P. Y. S., 117–122, Zoological Society of London, London. — Martin D. P. (1978): Primates. In: Zoo and Wild Animal Medicine, ed Fowler, M. E., 525–552, B W Saunders, Philadelphia. — Meadows R. (1973): Renal Histopathology. Oxford University Press, London. — Milton K., Nessimian J. L. (1984): Evidence for insectivory in two primate species (*Callicebus torquatus lugens* and *Lagothrix lagothericha lagothericha*) from Northwestern Amazonia. Am. J. Primatol. 6, 367–371. — Mitchell D. S., Graham J. R., Castrane V. D. (1982): Operant elevation of blood pressure in unrestrained olive baboons (*Papio cynocephalus anubius*). Am. J. Primatol. 3, 229–238. — Napier P. H. (1967): A Handbook of Living Primates, 412, Academic Press, London, New York. — Parker H. R., Dungworth D. L., Galligan S. J. (1966): Renal hypertension in sheep. Am. J. Vet. Res. 27, 430–443. — Portmann O. W. (1970): Nutritional requirements of squirrel and woolly monkeys. In: Feeding and Nutrition of Non-human Primates, ed Harries, R. S., 159–173, Academic Press, New York, London. — Sambhi M. P. (1980): Essentielle Hypertonie. In: Arterielle Hypertonie, ed Rosenthal, J., 272–288, Springer-Verlag, Berlin. — Seewer M. (1973): Koronarsklerose und Myokardveränderungen bei Ratten mit experimenteller renaler Hypertonie, Vet.-med. Diss., Bern. — Slauson D. O., Hobbs C. H., Crain C. (1978): Arteriolar nephrosclerosis in the Syrian hamster. Vet. Pathol. 15, 1–11. — Somova L., Kiprov D., Orbetzova V. (1975): Vaso-depressor activity of renal medulla of spontaneously hypertensive rats. Cor. Vasa. 17 (2), 119–124. — Stout C., Lemmon W. B. (1971): Hypertensive-like vascular lesions in a chimpanzee. Exp. Mol. Pathol. 14, 151–157. — Stuart R., Salyer

W. R., Salyer D. C., Heptinstall R. H. (1976): Renomedullary interstitial cell lesions and hypertension. Hum. Pathol. 7, 327–332. — Takeda T., Grollman A. (1970): Spontaneously occurring renal disease in the guinea pig. Am. J. Pathol. 60, 103–117. — Walker E. P. (1964): Mammals of the World, vol. 1, 437, Johns Hopkins Press, Baltimore. — Williams, L. (1967): Breeding Humboldt's woolly monkey (*Lagothrix lagothericha*) at Murrayton Woolly Monkey Sanctuary. In: International Zoo Year Book, vol. 7, ed Jarvis, C., 86–89, Zoological Society of London, London.

### Le singe de laine (*Lagothrix lagothericha*): Un éventuel modèle pour la recherche de l'hypertension humaine

Les lésions anatomo-pathologique chez 15 singes laineux étaient comparables aux formes bénigne et maligne de l'hypertension essentielle chez l'homme. Des lésions rénales telles qu'une artério- et artériolosclérose, ainsi qu'une endartérite proliférative «onion peel-like», parfois nécrotisante, étaient caractéristiques. Une obésité, due à une activité physique limitée, une nutrition non physiologique ainsi qu'un stress physique et psychique étaient des facteurs prédisposants. L'hypothèse d'une vulnérabilité accrue de l'espèce des singes laineux est avancée. L'hypertension essentielle chez le singe laineux semble donc être d'origine multifactorielle.

### La scimmia di lana (*Lagothrix lagothericha*): Un possibile modello animale nel campo di ricerca dell'ipertonia

Reperti anatomo patologici su 15 scimmie di lana risultano esser paragonabili alle forme benigne e maligne dell'ipertonia essenziale dell'uomo. Arterio e arteriolosclerosi accompagnate da un'arterite terminale proliferativa caratteristica («onion peel-like»), risultano essere lesioni renali tipiche. Obesità in seguito ad attività fisica insufficiente, alimentazione errata e stress psichico e fisico sono fattori predisponenti. Viene inoltre anche postulata una predisposizione genetica della specie. L'ipertonia delle scimmie di lana sembra esser dovuta all'azione di un intero complesso di fattori.

Adresse: Dr. M. Müller  
Institut für Tierpathologie  
Postfach 2735  
CH-3001 Bern

Manuskripteingang: 13. Februar 1989