

Zeitschrift: Schweizer Archiv für Tierheilkunde SAT : die Fachzeitschrift für Tierärztinnen und Tierärzte = Archives Suisses de Médecine Vétérinaire
ASMV : la revue professionnelle des vétérinaires

Herausgeber: Gesellschaft Schweizer Tierärztinnen und Tierärzte

Band: 130 (1988)

Artikel: Observations on the pathology of experimental salmonellosis (*S. typhimurium*) in calves, with special consideration of the haematopoietic organs (thymus, mesenteric lymph nodes, spleen and bone marrow)

Autor: Teuscher, E. / Couture, Y. / Matovelo, J.A.

DOI: <https://doi.org/10.5169/seals-590664>

Nutzungsbedingungen

Die ETH-Bibliothek ist die Anbieterin der digitalisierten Zeitschriften auf E-Periodica. Sie besitzt keine Urheberrechte an den Zeitschriften und ist nicht verantwortlich für deren Inhalte. Die Rechte liegen in der Regel bei den Herausgebern beziehungsweise den externen Rechteinhabern. Das Veröffentlichen von Bildern in Print- und Online-Publikationen sowie auf Social Media-Kanälen oder Webseiten ist nur mit vorheriger Genehmigung der Rechteinhaber erlaubt. [Mehr erfahren](#)

Conditions d'utilisation

L'ETH Library est le fournisseur des revues numérisées. Elle ne détient aucun droit d'auteur sur les revues et n'est pas responsable de leur contenu. En règle générale, les droits sont détenus par les éditeurs ou les détenteurs de droits externes. La reproduction d'images dans des publications imprimées ou en ligne ainsi que sur des canaux de médias sociaux ou des sites web n'est autorisée qu'avec l'accord préalable des détenteurs des droits. [En savoir plus](#)

Terms of use

The ETH Library is the provider of the digitised journals. It does not own any copyrights to the journals and is not responsible for their content. The rights usually lie with the publishers or the external rights holders. Publishing images in print and online publications, as well as on social media channels or websites, is only permitted with the prior consent of the rights holders. [Find out more](#)

Download PDF: 16.02.2026

ETH-Bibliothek Zürich, E-Periodica, <https://www.e-periodica.ch>

Schweiz. Arch. Tierheilk. 130, 195–210, 1988

Faculty of Veterinary Medicine, University of Montreal (Canada)
and Faculty of Veterinary Medicine, Sokoine University of Agriculture, Morogoro (Tanzania)

Observations on the pathology of experimental salmonellosis (*S. typhimurium*) in calves, with special consideration of the haematopoietic organs (thymus, mesenteric lymph nodes, spleen and bone marrow)

by *E. Teuscher¹, Y. Couture and J. A. Matovelo*

Introduction

During a clinical trial at the University of Montreal, 45 calves were infected experimentally with *Salmonella typhimurium*.²

In this trial, the calves were treated with different substances (nitrofurazone, electrolytes, polymyxine E) and some were untreated. The results of these clinical trials will be published (Brahim).

Independently from the treatment, it is possible to divide the animals in several groups. Some died very quickly after experimental infection, some died after a few days, some were killed at different stages, up to 10 days after experimental infection.

In this paper we shall limit ourselves to the description of the lesions in the different groups with special consideration of the haematopoietic organs (thymus, mesenteric lymph nodes, spleen and bone marrow).

The lesions of salmonellosis in calves have already been described (Jubb, Kennedy and Palmer, 1985; Johnston and Jones, 1975; Wray and Sojka, 1978). In our trial, however, we were able to study the changes in the haematopoietic system in several stages of the disease, with interesting results. Our purpose is to contribute to the understanding of the pathology of some organs during a known infectious disease in conventional calves of mixed origin.

Some of the changes may be common to several diseases and some are more specific for salmonellosis.

Materials and Methods

Male Holstein calves were purchased from the market at the age of between 7 and 10 days. After one week of observation including clinical checking and bacteriological examination they were

¹ Address: Prof. Dr. Ernest Teuscher, Danida Support Project, P. O. Box 1387, Morogoro (Tanzania)

² Our material includes not only the 36 calves used for the clinical trial but also some animals used in preliminary studies, which died too quickly to be treated.

infected following a 24 hour long fasting period with a suspension of *Salmonella typhimurium* (10^{10} particles, stem 3860 C, mixed with 50 ml milk). The calves were fed 5 hours after infection and treatment was given as soon as fever or diarrhoea appeared. Necropsy was performed as soon as possible after natural death or immediately after barbiturate euthanasia.

Specimens for histopathological examination were taken from the retropharyngeal and mesenteric lymph nodes, abomasum, duodenum, jejunum, ileum, ileo-caecal valves, spiral colon and terminal colon, thymus, femoral bone marrow, lung, liver, gall bladder, spleen, myocardium, brain and kidney. After inclusion in paraffin, the sections were stained with HPS (haematoxylin-phloxine, safran). In some cases Gram stains have also been made.

Results

The results will be given collectively for the different groups formed according to the following criteria:

- Group 1: a) calves dead or killed in extremis 24 to 36 hours after infection;
b) calves dead 2 to 3 days after infection.
- Group 2: calves dead between 4 and 5 days after infection.
- Group 3: calves dead 6 days or more after infection.
- Group 4: calves killed in extremis 10 days after infection.
- Group 5: calves killed in good condition
 - a) 6 days after infection;
 - b) 8–10 days after infection.

The only criteria used to form these groups were the duration and the severity of the disease. In all groups animals with different treatments or no treatment at all were present. The proportion however was different from one group to the other. In group 1 a (peracute cases) no treatment was given.

Group 1

a) Three calves died and one was killed in extremis between 24 and 36 hours after infection (No 1, 2, 3 and 4).

Two of them presented a typical severe acute fibrinous enteritis, especially located in distal jejunum and ileum. In the two other calves a sero-fibrinous enteritis was found, an abundant flaky material being present in the watery exudate. In one animal blood was seen, mixed with fibrin, in the small intestine.

In the large intestine, only watery contents were noted. Except for hyperaemia, no typical gross lesions were found in this group in the ileo-caecal valves. In two animals the Peyer's patches were swollen and covered with fibrin.

The mesenteric lymph nodes were irregularly swollen. Small haemorrhages have been found in the adrenals (2 cases), in the intestine (one) and in the brain (one).

Microscopically the intestinal changes were mild to moderate, but widespread. Superficial necrosis with disappearance of the villi, infiltration of the propria mucosae with macrophages, and in some cases, small necrotic foci were seen in the distal jejunum and ileum. In the Peyer's patches the follicles showed central necrosis. The histo-

pathological changes in the ileo-caecal valves were mild to moderate. The propria mucosae was infiltrated with macrophages, sometimes showing superficial necrosis and covered with exudate (fibrin and neutrophils).

The mesenteric lymph nodes were always affected. Neutrophils and macrophages were present in dilated sinuses, rarely accompanied by fibrinous exudate. Lymphocytes were still numerous, both in cortex and medulla. Sometimes there was a depletion of lymphocytes with necrosis in the centre of the follicles (fig. 7).

In the lung, a thickening of the alveolar walls with accumulation of macrophages have been noted (Fig. 18).

In these peracute cases, the thymus showed only moderate changes. The cortex was relatively thick, well separated from the medulla and contained densely packed small lymphocytes. The width of the cortex was slightly less than normal and irregular. Many swollen macrophages dispersed in the cortex between the lymphocytes (fig. 1) showed the beginning of cell destruction.

In the spleen the white pulp was not hyperplastic. The follicles were relatively small but sometimes contained middle sized lymphocytes, at some places there was necrosis in the centre of the lymphatic nodules, with karyorrhexis (fig. 11). Swollen macrophages containing cellular debris were also seen in the follicles. The red pulp was hyperaemic and contained often more reactive cells (macrophages) than normally.

In the bone marrow the number of haematopoietic cells was less than normal and they were generally far apart. Small haemorrhages were present. In two animals small foci of macrophages were seen (fig. 15).

b) In calves from this group, dead 2–3 days after infection (No 25, 26, 30, 43) the gross changes were similar to those of group 1a.

The ileo-caecal valve was however more affected, necrotic areas being covered with fibrinous exudate. Blood was seen in the small intestine in one animal. One calf had a severe acute fibrinous pneumonia.

Microscopically fibrinous exudate was almost constantly present in sinuses of the mesenteric lymphnodes, together with macrophages and neutrophils. Degenerative changes were also present in the follicles.

In the thymus there was a severe depletion of lymphocytes. Cortex and medulla were no more clearly distinguishable. There were also severe hyperaemia and oedema. The lobules were much smaller than normal (fig. 2) and the cortex thinner with fewer lymphocytes, which lay far apart.

In the spleen the follicles were small, often with depletion of the lymphocytes. In the red pulp, the blood content was variable as was the number of reactive cells.

In the bone marrow the number and the density of the haematopoietic cells were variable, sometimes very low. Hyperaemia and oedema were present.

Group 2

In this group 9 calves were included, which died 4 or 5 days after experimental infection (No 11, 19, 31, 32, 33, 36, 37, 44, 45).

In the intestine the changes were acute and severe. Fibrinous or fibrino-haemorrhagic exudate was generally present in the second half of the small intestine and often in the large intestine.

The changes in the mucous membrane were generally necrotic (multifocal or diffuse) in the posterior jejunum, ileum and ileo-caecal valve. Venous thrombi were seen in the intestinal wall in some animals. In two calves an acute fibrinous pneumonia was present.

Petechiae were often found in the epicardium, in the adrenals or in the bone marrow.

The mesenteric lymph nodes were generally markedly swollen and showed microscopically a severe hyperaemia, oedema and more or less typical inflammatory changes, often with fibrinous exudate or fibrino-necrotic foci in the sinuses. The lymphoid nodules were generally absent or difficult to see in the cortex (fig. 9). In the medulla the cords contained mainly small lymphocytes, while in the medullary sinuses mostly macrophages were present. Immunological reactions were absent or very mild and the lymphoid nodules in different parts of the intestine appeared often depleted or partly necrotic.

The thymus showed a severe depletion of lymphocytes. The cortex was generally inapparent. There was always a severe diffuse hyperaemia.

The spleen showed a variable state of hyperaemia. The lymph follicles were generally swollen, often inactive, rarely containing a small proportion of middle sized lymphocytes. In the red pulp, macrophages were relatively numerous (fig. 12).

In the bone marrow the number of haematopoietic cells was variable from one case to the other. Sometimes myeloid cells were relatively abundant and sometimes sparse, but hyperaemia and oedema were generally noted.

Group 3

Five calves died 6 days or more after infection (No 12, 27, 38, 39, 46). All animals presented an acute, sero-fibrinous, fibrinous, fibrino-necrotic or haemorrhagic enteritis. The lesions of the mucous membrane were variable in severity. The ileo-caecal valve was affected grossly (4 of 5 calves) or microscopically (5 of 5 calves).

Two calves showed gross lesions of the gall bladder (fibrin in lumen or thick bile), which were correlated histologically with a diffuse infiltration of the mucosa with lymphocytes, neutrophils and macrophages. Necrotic foci were also present. Another animal showed only microscopical changes (focal nodular lymphocyte infiltration). The mesenteric lymph nodes were mostly swollen. In two calves haemorrhages were found in the adrenals. On the whole, the main lesions were similar to those of group 2, but the intestine was always typically affected with variable severity.

In the microscopic examination the lymph nodes showed oedema, hyperaemia and dilated sinuses, containing chiefly macrophages and sometimes fibrin. Necrotic foci were present in some cases. The follicles were generally difficult to see and contained, if present, almost only small lymphocytes, less dense than normal and well separated as a consequence of oedema.

In the spleen, the follicles were small, without any immune reaction. The red pulp was variable in appearance (blood content and cellular reaction). Small necrotic foci were seen in some cases.

The thymus showed a severe depletion of lymphocytes with no evident separation between cortex and medulla. The lobules were smaller than normal. Small lymphocytes were uniformly distributed and sparse.

The bone marrow contained generally less cells than normal (fig. 16) and sometimes, there was a proliferation of immature myeloid cells. The number of erythroid cells was variable from one case to the other.

Group 4

Three calves were killed in bad condition 10 days after infection (No 7, 15, 35).

All animals in this group showed typical gross lesions in the intestine. Multiple necrotic foci were present in the mucous membrane of jejunum and ileum. Fibrinous enteritis was observed in the two others. In calf No 7 the Peyer's patches were swollen and covered with fibrin. Fibrino-necrotic changes were found in the ileo-caecal valve macroscopically in 2 cases and microscopically in all 3 cases.

The gall bladder contained fibrinous flakes (No 15) or coagulated bile (No 7). Mononuclear cell infiltration (fig. 19) or necrosis were observed microscopically. Mild inflammatory changes were also present in the third animal.

The mesenteric lymph nodes showed at this stage an evident immunological reaction, both in cortex and medulla (fig. 9 b). At the same time an inflammatory reaction was still present and accompanied by necrotic foci (fig. 9 a) or fibrinous exudate in the sinuses.

In the spleen an immunological reaction was also evident. The follicles were variable in size and larger lymphocytes appeared irregularly. In the red pulp, reticulo-endothelial cells were numerous, especially in calf No 15 (fig. 13).

In the thymus the lobules were small and atrophic. There was however an irregular proliferation of lymphocytes and reticulum cells, indicating the beginning of regeneration and remodeling (fig. 3).

In the bone marrow immature myeloid cells without differentiation (No 7 and 35) or with partial differentiation into eosinophils (No 15) were present, indicating some regeneration.

One calf showed a subacute focal pneumonia with atelectasis, thickening of the alveolar walls and purulent exudation. A small amount of sero-fibrinous exudate was present in the abdominal cavity.

Group 5

a) Two calves were killed in good condition 6 days after infection.

In both animals a typical fibrinous enteritis was present with macroscopic changes in the ileo-caecal valve.

The mesenteric lymph nodes showed some immunological reaction. Follicles were present and large lymphocytes were seen in small number in the medulla. An inflammatory reaction was also evident, with fibrinous foci or some necrotic areas.

Small necrotic foci were seen in the liver in both cases. In the thymus only a thin cortex (No 6) or remnants of cortex with small lymphocytes (No 5) were seen.

In the bone marrow myeloid cells were densely packed (with many eosinophils) indicating a hyperplastic reaction (no atrophy or oedema as opposed to acute cases).

In the spleen some reaction was observed in the white pulp, but the cells were not very active.

b) 18 calves were killed in good clinical condition 8–10 days after infection (No 8, 9, 10, 13, 14, 16, 17, 18, 20, 21, 22, 23, 24, 28, 29, 34, 40, 41).

The macroscopic changes were generally very slight. Sero-fibrinous exudate was seen in 4 animals in the small intestine. Serous enteritis was present in two and no significant intestinal changes were present grossly in 12 calves. However, swelling of the mesenteric lymph nodes was a frequent finding.

Microscopically, the intestinal changes were mild to moderate. In the duodenum and first half of jejunum, the only changes seen in some animals were an infiltration of the mucous membrane by macrophages and lymphocytes (6 cases). Very occasionally some crypts were dilated and contained exudate with neutrophils. In the caudal jejunum and ileum, dilated crypts with cellular exudate were seen in 10 animals. Macrophages and lymphocytes were often present in the mucous membrane or submucosa. Small necrotic foci were seen only in one calf. In the Peyer's patches, the follicles were sometimes hyperplastic, sometimes atrophic, but on the whole, the changes were not characteristic.

In the ileo-caecal valve typical lesions were seen in some animals. Superficial necrosis was observed in 5 calves, sometimes with exudate in the lumen. Necrotic foci in the mucosa were only seen in 2 calves. Dilated crypts with cellular exudate and infiltration of the mucous membrane with mononuclear cells were more common findings.

In the large intestine watery contents were present in 4 calves. Mononuclear infiltration in the mucous membrane was a frequent finding and in 3 animals, dilated crypts filled with exudate were observed.

In the mesenteric lymph nodes small necrotic foci, typical of *Salmonella* infection, were present in 7 calves, sometimes with fibrinous exudate in the sinuses. The sinuses contained generally macrophages, lymphocytes and a small number of neutrophils. The follicles in the cortex were mostly hyperplastic (fig. 10). In the medulla, the cords were broad containing chiefly lymphocytes (10 calves) or large lymphocytes and plasma cells (8 cases).

In this group the thymus was variable in appearance. Generally the cortex was thinner than normal and irregular. Often there was a tendency to lymphocytic proliferation in the medulla. The proliferating lymphocytes were middle sized, their nuclei being lighter than those of normal cortical lymphocytes (fig. 4 and 5). In two animals (No 10 and 14) the thymus was almost normal (fig. 6).

In the spleen the follicles were slightly increased in size and contained middle sized and sometimes large lymphocytes. Neutrophils were present in large numbers in the

marginal zone in 7 cases (fig. 14). This change is apparently characteristic of bacteraemia. We have seen similar lesions in *Haemophilus somnus* septicaemia in cows and in other bacterial diseases. It is also noted in the new edition of Jubb, Kennedy and Palmer vol. 3 p. 196 (1985). In the red pulp, congestion was frequent but probably related to the

Fig. 1

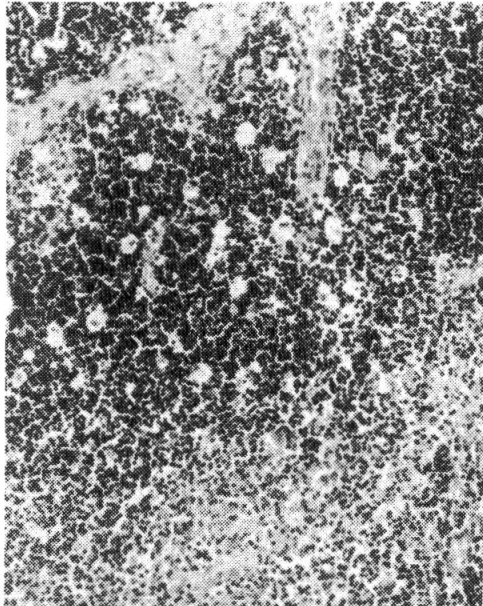


Fig. 2

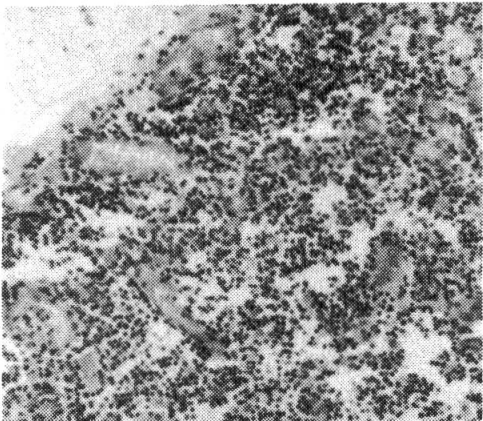


Fig. 3

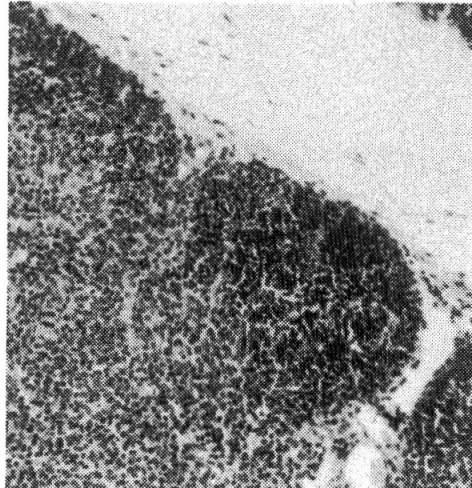
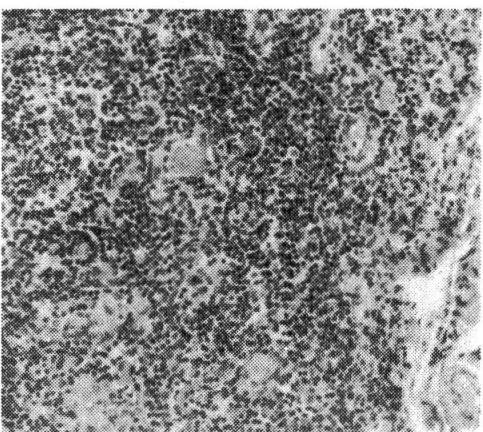


Fig. 4

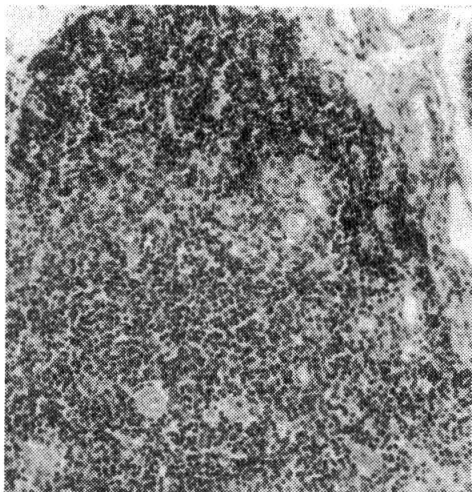


Fig. 5

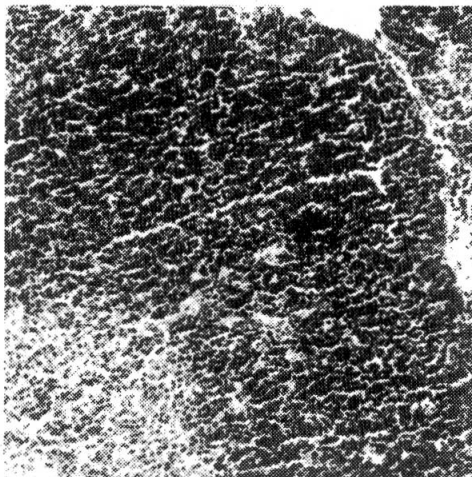


Fig. 6

killing of the animals with barbiturates. An irregular or diffuse proliferation of reticulo-endothelial cells was seen in 15 animals.

The bone marrow showed an increase of haematopoietic cells in relation with the more severe or more acute cases (fig. 17). The number of mature cells with many eosino-

Fig. 7

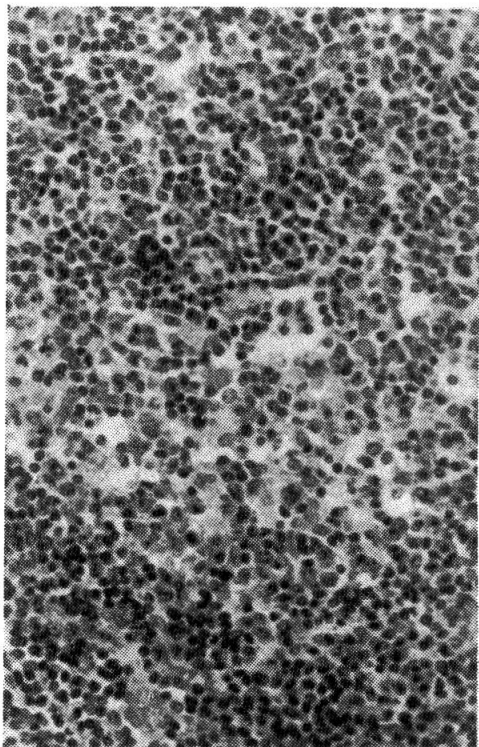


Fig. 8

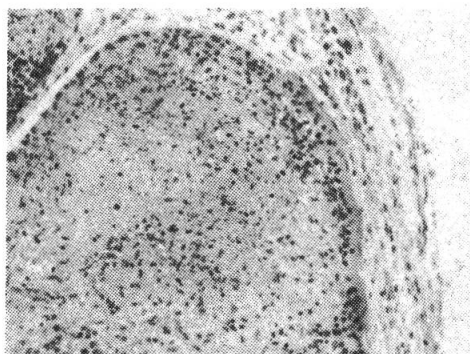
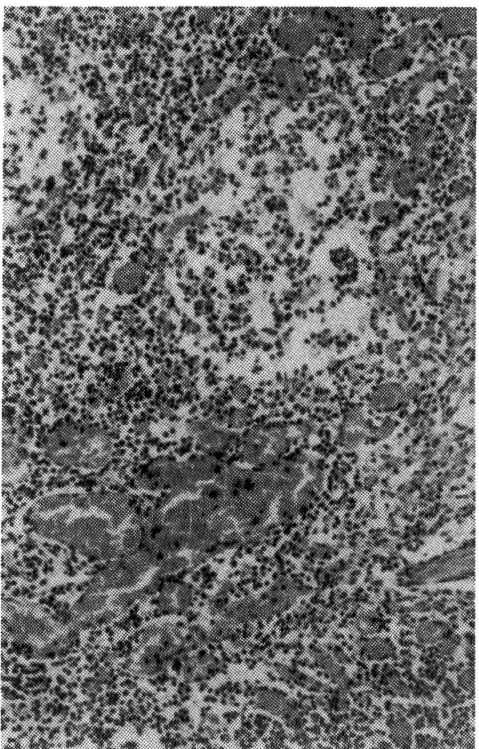


Fig. 9a

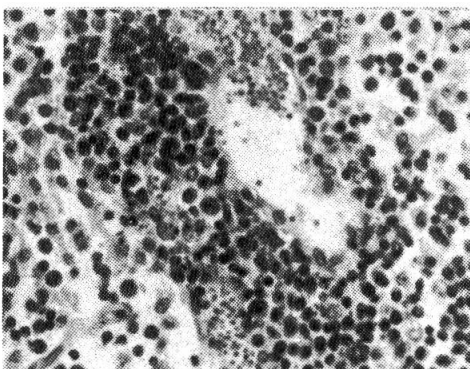


Fig. 9b

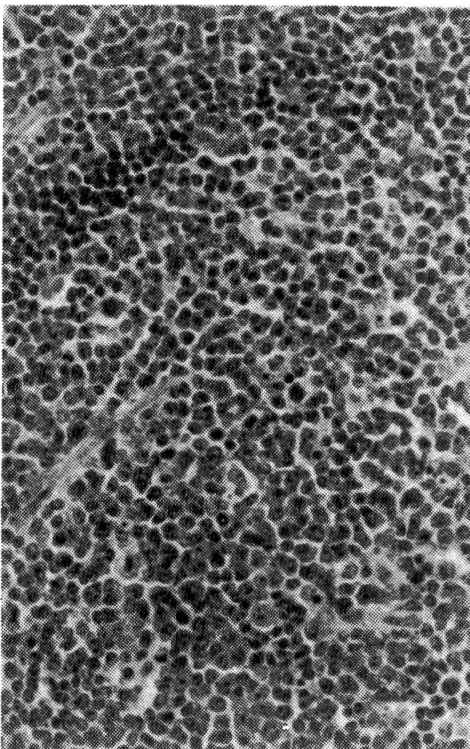


Fig. 10

phils was also increased. In a few animals the number of haematopoietic cells was low. We do not know whether this was due to a sampling error or if these animals, if kept alive longer, would have shown some damage in blood cell production.

Fig. 11

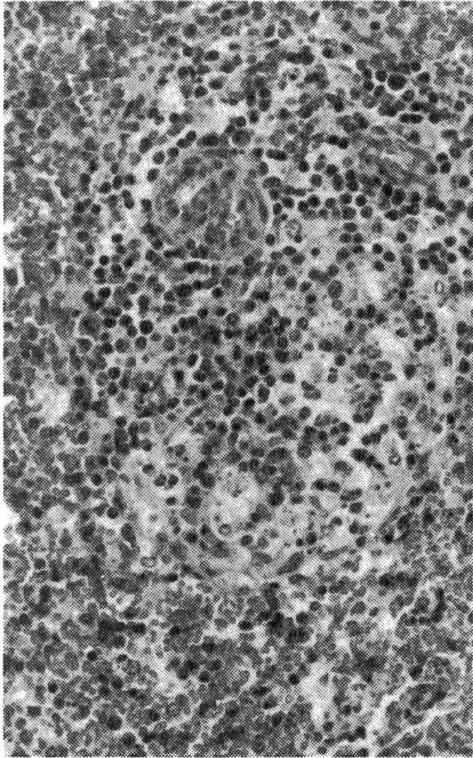


Fig. 13

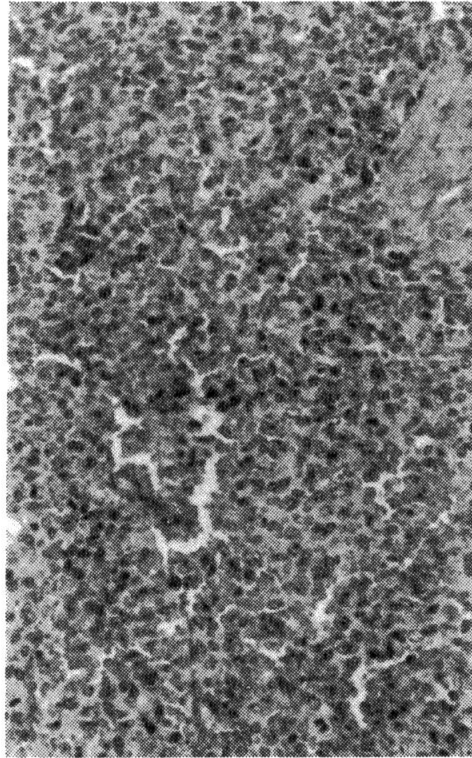


Fig. 12

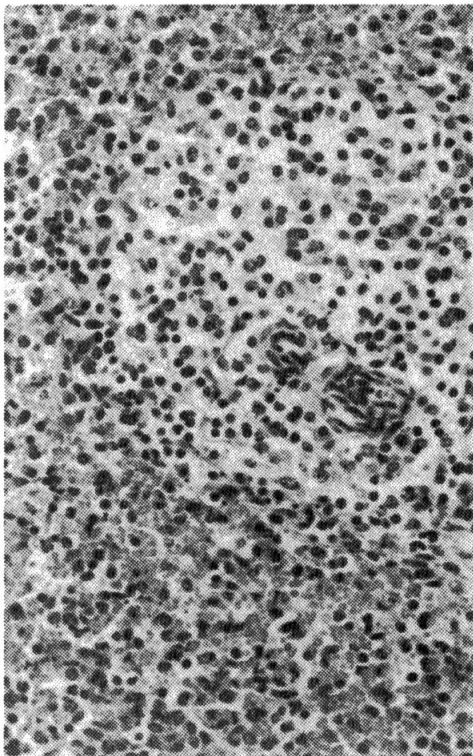
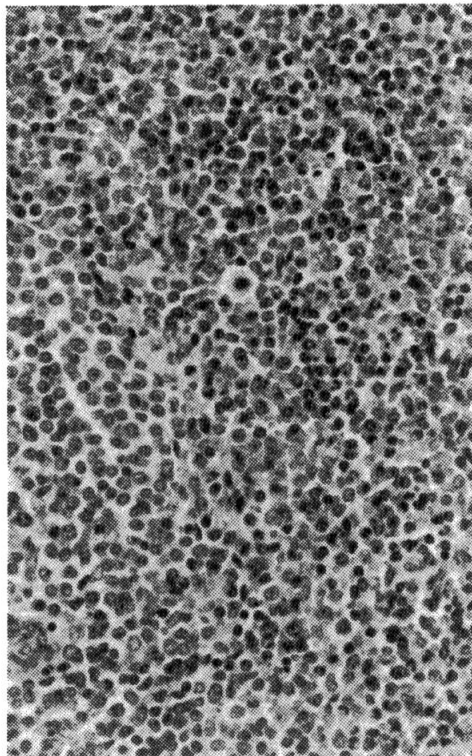


Fig. 14



In two animals a mild encephalitis was observed. In the liver small accumulations of lymphocytes were often found in the portal areas, sometimes with swelling of Kupfer's cells. Typical necrotic foci were only seen in small number in one case.

Fig. 15

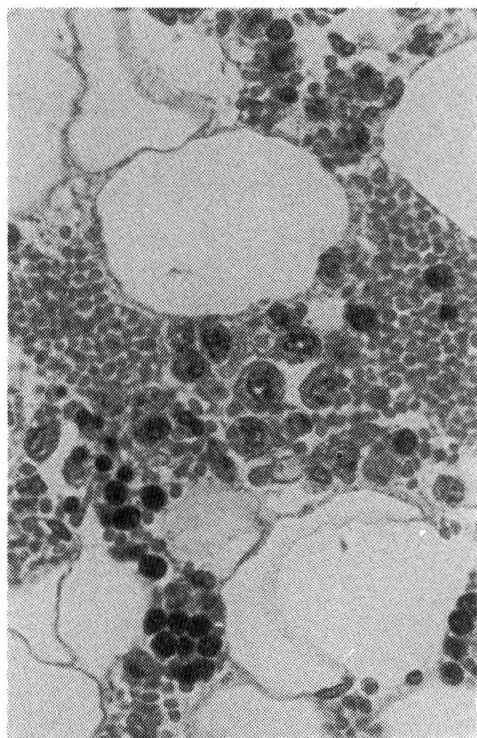


Fig. 17

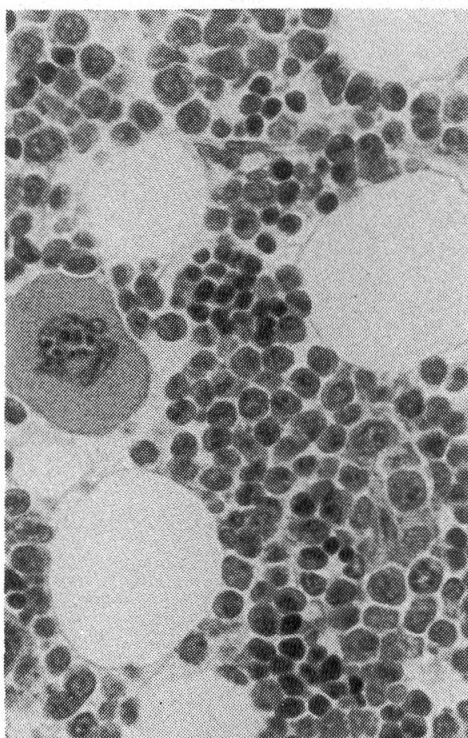


Fig. 16

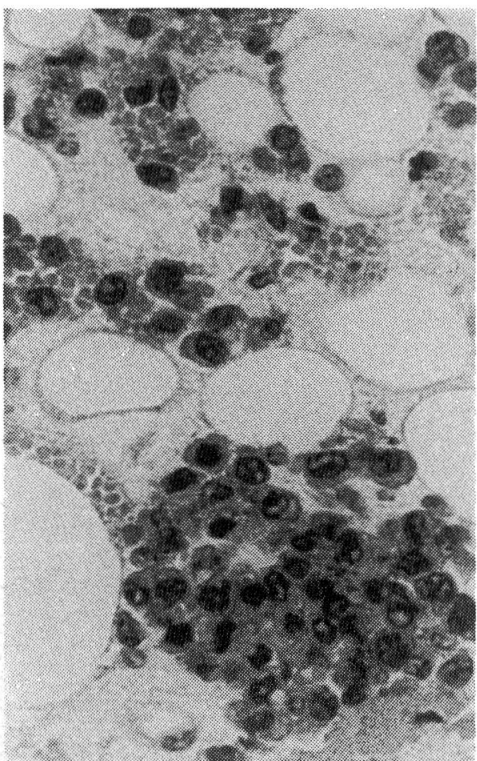


Fig. 18

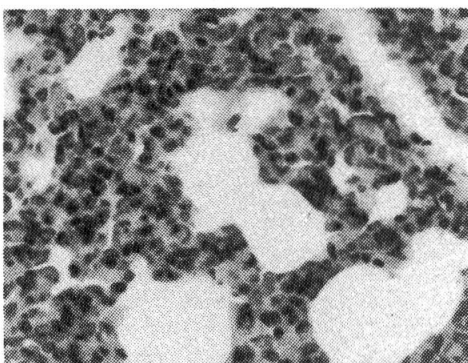
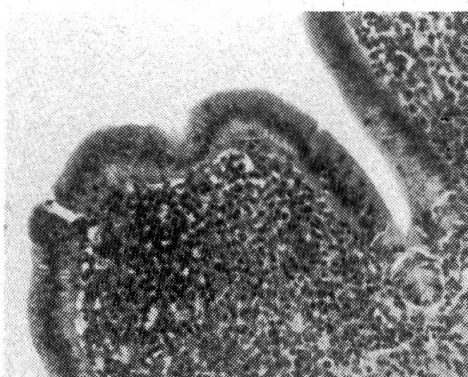

Fig. 19



In the gall bladder multiple inflammatory foci (lymphocytes and macrophages) were present in 8 cases. No significant changes have been noted in the synovial membranes and in the kidneys.

In the lung 3 animals showed lesions of pneumonia during the gross examination (14, 34, 41). Microscopically atelectasis, thickening of the interstitial spaces and neutrophil exudation into the alveoli were present in all 3 cases. Thickening of the alveolar

Legend of figures (all are stained haematoxylin-phloxine-safran)

Fig. 1 Thymus, calf No 1, peracute case, dead 36 hours after infection: many clear, swollen macrophages are present in the cortical area, obj. 10

Fig. 2 Thymus, calf No 30, dead 3 days after infection: severe depletion of lymphocytes, hyperaemia, obj. 10

Fig. 3 Thymus, calf No 35, killed in extremis 10 days after infection: the thymus shows depletion of lymphocytes and some irregular cell proliferation, obj. 10

Fig. 4 Thymus, calf No 41, killed in good condition 10 days after infection: the cortex is irregular and thin; lymphocytic proliferation in the central part of the lobules, obj. 10

Fig. 5 Thymus, calf No 22, killed in good condition 10 days after infection: the cortex is sparse and contains small lymphocytes, while lymphocytic proliferation is clearly visible in the centre, obj. 10

Fig. 6 Thymus, calf No 23, killed in good condition 10 days after infection: the cortex is almost normal, obj. 10

Fig. 7 Mesenteric lymph node, calf No 3, peracute case, killed in extremis 30 hours after infection: partial depletion of lymphocytes in follicles, macrophages and reticulum cells present in central part, obj. 20

Fig. 8 Mesenteric lymph node, calf No 45, dead 5 days after infection: hyperaemia, oedema; the follicles show a severe depletion of lymphocytes, obj. 10

Fig. 9 Mesenteric lymph node, calf No 7, killed in extremis 10 days after infection: a) fibrin exudation and necrosis in sinus, HPS, obj. 10 b) immunological reaction in medulla, obj. 20

Fig. 10 Mesenteric lymph node, calf No 29, killed in good condition 10 days after infection: immunological reaction in follicles (proliferation of middle and large lymphocytes), obj. 20

Fig. 11 Spleen, calf No 3, peracute case, killed in extremis 30 hours after infection: partial necrosis of follicles, presence of macrophages and reticulum cells in centre, congestion of red pulp, obj. 20

Fig. 12 Spleen, calf No 32, dead 5 days after infection: the lymphocytes are wide apart in follicles, increased cell density in red pulp, obj. 20

Fig. 13 Spleen, calf No 15, killed in extremis 10 days after infection: very dense red pulp with proliferation of reticulum cells, obj. 20

Fig. 14 Spleen, calf No 17, killed in good condition 10 days after infection: immunological reaction in follicles (middle and large lymphocytes) and neutrophils in marginal zone, obj. 20

Fig. 15 Bone marrow, calf No 3, peracute case, killed in extremis 30 hours after infection: depletion of haematopoietic cells, foci of large monocyte-like cells, obj. 40

Fig. 16 Bone marrow, calf No 39, dead 6 days after infection: few typical haematopoietic cells, foci of monocyte-like cells, obj. 40

Fig. 17 Bone marrow, calf No 22, killed in good condition 10 days after infection: repopulation with immature haematopoietic cells, obj. 40

Fig. 18 Lung, calf No 1, peracute death 36 hours after infection: thickening of alveolar walls, obj. 20

Fig. 19 Gall bladder, calf No 15, killed in bad condition 10 days after infection: severe infiltration of the mucous membrane with lymphocytes and other mononuclear cells, obj. 10

walls was seen at least in 12 animals. Inflammatory reactions were also observed microscopically in the lung of some other calves.

Discussion

Several patterns can be recognized in calf salmonellosis caused by *Salmonella typhimurium*. The clinical disease is variable, depending essentially on the amount of toxins produced, the severity of the diarrhoea and dehydration. Fever is always present, at least initially. The diarrhoea may be watery, mucoid, fibrinous or haemorrhagic, often changing in appearance during the clinical course.

At necropsy in the most acute cases fibrinous or sero-fibrinous exudate, often mixed with blood, may be present without obvious lesions of the mucous membrane. Sometimes the lesions are more evident on Peyer's patches. In subacute or more chronic cases, the mucosal changes become necrotic, the fibrinous exudate is more firmly attached to the mucous membrane and the lesions are located especially in the caudal jejunum, ileum and ileo-caecal valves. Mucosal changes may be present in caecum and colon. Often however the contents are watery or fibrinous with only mild inflammatory reaction.

The swelling of the mesenteric lymph nodes is an important finding in calf salmonellosis. If present, necrosis of the gall bladder mucous membrane and coagulated bile are quite characteristic.

Microscopically typical lesions can be seen mostly in intestine and mesenteric lymph nodes. Fibrin exudation in lymph nodes, thrombosis, necrotic foci or paratyphoid nodules in different organs are characteristic. In the lung fibrinous pneumonia can occur. Thickening of the alveolar walls with accumulation of macrophages belongs to the general picture but cannot be considered as pathognomonic.

In this experiment, interesting results were obtained concerning changes in the haematopoietic system. There was a certain parallelism in the lesions in thymus, lymph nodes and spleen. In peracute cases (group 1a) the depletion of lymphocytes was not yet marked. In the thymus only the presence of many swollen macrophages in the cortex indicated a beginning of lymphocytic necrosis (fig. 1). In the lymph nodes, acute inflammatory reactions were dominant and degenerative changes could only be seen in the centre of the follicles.

In acute cases (groups 1b, 2 and 3) the depletion of the lymphocytes was evident in thymus (fig. 2), lymph node (fig. 8) and spleen (fig. 11). There was an increase of reticulo-endothelial cells in the red pulp. More characteristic inflammatory changes (fibrinous exudation in sinuses, necrotic foci) were often seen in this stage in lymph nodes.

In animals surviving the infection for 6 to 10 days (groups 5a and 5b) without severe clinical signs, the thymus started to regenerate (fig. 4 and 5) and could even be almost normal (fig. 6). The lymph nodes and spleen showed again immunological reactions (fig. 10 and 14). The follicles became larger and contained middle sized or large lymphocytes. Large lymphocytes and plasma cells appeared in the medulla of the lymph nodes (fig. 9b).

In the bone marrow, the changes were also different in the different groups. Oedema, hyperaemia and haemorrhages dominated in the peracute cases and in acute cases the number of cells decreased sharply, probably in relation with leukopenia. Sometimes focal accumulations of monocyte-like cells were found (fig. 15 and 16). Later myeloid cells started again to proliferate in almost all animals (fig. 17). Eosinophils seemed to dominate in most cases. In a few animals the bone marrow was hypoplastic or even cachectic in appearance. Correlations with blood examination and long term study would have been interesting.

The thymus has not been taken systematically in the past in routine post mortem examinations. Even if it is not always necessary for the diagnosis of diseases, it may be helpful in several ways. Attention was first drawn to the thymus in viral diseases, e. g. parvovirus infections in dogs and cats, feline leukaemia virus in kittens, and canine distemper.

It is also known that thymus «atrophy» can be unspecific and due essentially to stress. Papers have been published recently concerning the histopathology of the thymus in gram-negative bacterial diseases in poultry (Nakamura et al., 1986). The mechanisms involved remain subject to discussion, which, given the complexity of modern lymphocyte biology, is beyond the scope of the present paper.

It is however interesting to note that the time at which depletion occurs is almost the same in colibacillosis in poultry (2 days) as in calf salmonellosis. The starry sky appearance in the cortex occurs also very soon in calves as in chickens and the repopulation starts also 8 to 10 days after infection. A completely normal thymus was not observed in our cases, probably because all were killed 10 days after infection, and complete recovery may take two weeks.

In chickens the lymphocytic depletion varies with the agent. It is much more rapid (one hour) with mycotoxins (T₂ or diacetoxyscirpenol), than in Marek's disease. The reason may be that mycotoxins act directly on lymphocytes, while viruses or bacterial toxins must first activate physiological defense mechanisms.

According to Nakamura, Ymada and Maeda (1986) lymphocytic depletion may represent a combination of direct effects of *E. coli* toxic components and non specific stress factors. New concepts may perhaps give more accurate explanations. It is known for example, that endotoxins may induce macrophages to produce cytokines e.g. «Tumor Necrosing Factor- α » (Franchimont et al. 1987). As in the trial with *E. coli* in chickens, depletion of both B- and T-lymphocytes occurred in the present experiment.

In lymph nodes, inflammatory reactions and immunological events should always be considered separately in the interpretation of changes. If in peracute cases some immunological changes were still evident, it is because of the normal physiological activity in lymph nodes exposed to unavoidable antigens. In severe acute cases however, the humoral and cell mediated immunity were not apparent, the only active defense cells being neutrophils and macrophages. If the calves survive long enough, proliferation of middle sized and large lymphocytes in lymphatic follicles and accumulation of plasma cells in the medulla were again observed.

The retropharyngeal lymph nodes did not always show exactly the same picture as the mesenteric lymph nodes, even if, generally speaking, the same pattern of develop-

ment was observed (first inflammatory reaction, than depletion of lymphocytes and finally extensive immunological reaction in more chronic cases). Differences were sometimes correlated with the presence or absence of acute pneumonia. The inflammatory reaction was more severe when an acute fibrinous pneumonia was present. The immunological reaction observed in more chronic cases indicates a general reaction due to probable bacteraemia.

The pathogenesis of salmonellosis in calves is complex (Murray, 1986). In peracute cases toxins, metabolic disturbances and dehydration produce a shock syndrome before the most severe intestinal morphological changes can develop. Septicaemia may be an important feature in all acute cases. Even in animals surviving 10 days in good clinical condition, localized lesions may be present and signs of bacteraemia can be seen (proliferation of macrophages in splenic red pulp, presence of neutrophils in marginal zones). The changes in the gall bladder, more frequent microscopically than grossly, are an indication of the affinity of *Salmonella* for the bile (fig. 19).

The observations in this trial are not only interesting theoretically. They may help the pathologist to evaluate the duration of the clinical disease in calf salmonellosis or to suspect it when certain patterns of lesions are found at post mortem examination.

Summary

During a therapeutic trial at the University of Montreal, 45 calves were infected with a suspension of *Salmonella typhimurium*. For the description of the lesions found at necropsy, the animals were divided in different groups according to the severity of the disease, including peracute, acute, subacute cases, and animals killed in good condition 10 days after infection.

Interesting findings have been obtained concerning the haematopoietic organs. In thymus, lymph nodes and spleen a depletion of lymphocytes occurred in the acute cases after about two days. An active immunological reaction was again present 8 to 10 days after infection. In the lymph nodes inflammatory changes were seen in all groups.

In acute cases the bone marrow showed haemorrhages, oedema and diminution of the haematopoietic cells. Proliferation of myeloid cells occurred when the animals survived long enough.

The gross and microscopic changes in other organs (intestine, lung, liver, gall bladder) were generally characteristic and similar to the lesions described in natural cases.

Zusammenfassung

Im Verlauf von therapeutischen Untersuchungen wurden an der Universität Montreal (Kanada) 45 Kälber mit einer Suspension von *Salmonella typhimurium* infiziert. Zur Beschreibung der anlässlich der Sektion gefundenen Veränderungen wurden die Tiere entsprechend der Schwere der klinischen Erkrankung in verschiedene Gruppen eingeteilt, nämlich perakute, akute, subakute Fälle sowie Tiere, die in guter Verfassung 10 Tage post infectionem getötet worden waren.

Interessante Befunde wurden an den hämatopoetischen Organen erhoben. Im Thymus, Lymphknoten und Milz erfolgte eine Lymphozyten-Depletion in den akuten Fällen nach etwa 2 Tagen. Eine aktive immunozytäre Reaktion trat wieder auf am 8. bis 10. Tag post infectionem. In allen Gruppen wurde eine entzündliche Reaktion in den Lymphknoten beobachtet.

In akuten Fällen zeigte das Knochenmark Blutungen, Oedem und Abnahme der hämatopoetischen Zellen. Proliferation myeloider Zellen erfolgte bei genügend langem Überleben der Tiere.

Die makroskopischen und mikroskopischen Veränderungen in den anderen Organen (Darm, Lunge, Leber, Gallenblase) waren im allgemeinen charakteristisch und glichen den für die Spon-tankrankheit beschriebenen.

Résumé

Au cours d'un essai thérapeutique à l'Université de Montréal, 45 veaux ont été infectés au moyen d'une suspension de *Salmonella typhimurium*. Selon la gravité de la maladie, les animaux ont été répartis en plusieurs groupes: cas suraigus, aigus, subaigus et animaux sacrifiés en bonne condition 10 jours après l'infection. Les lésions sont décrites pour chaque groupe.

Des résultats intéressants ont été obtenus en ce qui concerne les organes hématopoïétiques. Dans le thymus, les ganglions lymphatiques et la rate, un épuisement des lymphocytes a été observé dans les cas aigus dès le deuxième jour. Une réaction immunitaire active était déjà apparente 8 à 10 jours après l'infection. Dans les ganglions lymphatiques des lésions inflammatoires aiguës ont été observées dans presque tous les groupes.

La moelle osseuse présentait, dans les cas aigus, des hémorragies et de l'oedème, ainsi qu'une diminution de la densité des cellules hémapoïétiques. Chez les animaux ayant survécu assez longtemps, on observa une régénération des cellules myéloïdes.

Les lésions inflammatoires macroscopiques et microscopiques dans les autres organes (intestin, poumon, foie, vésicule biliaire) étaient généralement caractéristiques et similaires aux lésions décrites dans les cas naturels.

Riassunto

Nel corso di un esperimento terapeutico all'Università di Montréal, 45 vitelli sono stati infettati con una sospensione di *Salmonella typhimurium*. Secondo la gravità della malattia contratta, gli animali sono stati divisi in gruppi diversi: casi peracuti, acuti, subacuti, ed animali sacrificati in buone condizioni 10 giorni dopo l'infezione. Per ogni gruppo sono descritte le lesioni.

Sono stati ottenuti risultati interessanti per quanto concerne gli organi ematopoietici. Nel timo, nei linfonodi e nella milza è stato osservato un degrado dei linfociti nei casi acuti a partire dal secondo giorno. Una reazione immunitaria attiva era già apparente 8–10 giorni dopo l'infezione. In quasi tutti i gruppi sono state osservate lesioni infiammatorie nei linfonodi.

Il midollo osseo presentava, nei casi acuti, emorragie ed edemi, come pure una diminuzione della densità delle cellule ematopoietiche. Negli animali che hanno sopravvissuto abbastanza a lungo si osservò una rigenerazione delle cellule mieloidi.

Le lesioni infiammatorie macroscopiche e microscopiche negli altri organi (intestino, polmone, fegato, vescica biliare) erano generalmente caratteristiche e simili alle lesioni descritte nei casi naturali.

References

- [1] *Brahim A.*, Thesis For Master degree, University of Montreal. Evaluation d'un mode de traitement par voie orale de la salmonellose expérimentale chez le veau.
- [2] *Franchimont P., Reuter A., Gysen Ph., Bernier J., Vrindts-Gevaert Y.*: Tumor Necrosing Factor α : Un médiateur de la fonction macrophagique. Actions biologiques et dosage radio-immuno-

logique. Méd. et Hyg. 45, 2160–2168 (1987). — [3] *Johnston K. G., Jones R. T.*: Salmonellosis in calves due to lactose fermenting *Salmonella typhimurium*. Vet. Rec. 98, 276–278 (1975). — [4] *Jubb K. V. F., Kennedy P. C., Palmer N.*: Pathology of domestic animals, 3rd Edition, Vol. 2 p. 135–138. Academic Press Inc. London, 1985. — [5] *Murray M. J.*: Salmonella. Virulence factors and enteric salmonellosis. JAVMA, 189, 145–147 (1986). — [6] *Nakamura K., Imada Y., Maeda M.*: Lymphocytic depletion of bursa of Fabricius and thymus in chickens inoculated with *Escherichia coli*. Vet. Pathol. 23, 712–717 (1986). — [7] *Wray C. Sojka W. J.*: Experimental *Salmonella typhimurium* infection in calves. Res. Vet. Sci. 25, 139–143 (1978).

Registration of manuscript: November 11th 1987