

Zeitschrift: Schweizer Archiv für Tierheilkunde SAT : die Fachzeitschrift für Tierärztinnen und Tierärzte = Archives Suisses de Médecine Vétérinaire
ASMV : la revue professionnelle des vétérinaires

Herausgeber: Gesellschaft Schweizer Tierärztinnen und Tierärzte

Band: 129 (1987)

Artikel: Ram testicular hypoplasia : anatomical and histopathological observations

Autor: Gimbo, A. / Zanghi, A. / Giannetto, S.

DOI: <https://doi.org/10.5169/seals-592975>

Nutzungsbedingungen

Die ETH-Bibliothek ist die Anbieterin der digitalisierten Zeitschriften auf E-Periodica. Sie besitzt keine Urheberrechte an den Zeitschriften und ist nicht verantwortlich für deren Inhalte. Die Rechte liegen in der Regel bei den Herausgebern beziehungsweise den externen Rechteinhabern. Das Veröffentlichen von Bildern in Print- und Online-Publikationen sowie auf Social Media-Kanälen oder Webseiten ist nur mit vorheriger Genehmigung der Rechteinhaber erlaubt. [Mehr erfahren](#)

Conditions d'utilisation

L'ETH Library est le fournisseur des revues numérisées. Elle ne détient aucun droit d'auteur sur les revues et n'est pas responsable de leur contenu. En règle générale, les droits sont détenus par les éditeurs ou les détenteurs de droits externes. La reproduction d'images dans des publications imprimées ou en ligne ainsi que sur des canaux de médias sociaux ou des sites web n'est autorisée qu'avec l'accord préalable des détenteurs des droits. [En savoir plus](#)

Terms of use

The ETH Library is the provider of the digitised journals. It does not own any copyrights to the journals and is not responsible for their content. The rights usually lie with the publishers or the external rights holders. Publishing images in print and online publications, as well as on social media channels or websites, is only permitted with the prior consent of the rights holders. [Find out more](#)

Download PDF: 22.02.2026

ETH-Bibliothek Zürich, E-Periodica, <https://www.e-periodica.ch>

Schweiz. Arch. Tierheilk. 129, 481–491, 1987

Institute of Obstetrics and Gynecology, Faculty of Veterinary Medicine, University of Messina

Ram testicular hypoplasia Anatomical and histopathological observations

A. Gimbo¹, A. Zanghì and S. Giannetto

Introduction

Testicular hypoplasia is still confused today with other lesions (atrophy) from which it should be distinguished because of different etiopathogenic conditions and related pathology.

We understand by «testicular hypoplasia» an insufficient testicular development; uni- or bilateral, either prenatal or postnatal but always prepuberal with or without lesions of other genital organs. Otherwise we use the term «atrophy» to describe the reduction of morphological as well as functional features of a mature testis.

Testicular hypoplasia has been investigated extensively and in detail in many animal species including humans. The most important observations have been carried out by *Lagerlöf* in the bull. In his first paper (1934) he reported a form of usually bilateral testicular hypoplasia, relatively frequent in Swedish cattle.

Afterwards the same Author in 1957 identified in the «Swedish Highland breed» a particular form of hypoplasia which affects more frequently one testis, generally the left.

Eriksson (1943; 1950) then showed that in the Swedish Highland breed, hypoplasia is caused by an autosomal recessive gene with incomplete penetrance, which is inherited with Mendelian characteristics.

The situation of testicular hypoplasia in the ram is more confusing than in the bull, because the distinction between hypoplasia and atrophy is not always clear.

Gunn et al. (1942), in Australia, found 3,5% of hypoplasia in 9000 rams.

These authors suggested a prenatal (probably hereditary) lesion as the cause of unilateral hypoplasia. The above mentioned paper, however, lacks both a microscopic description of the lesion and a differential diagnosis with regard to other lesions. *Miller and Moule* (1954) reported an incidence of about 1,3%; *Watt* (1971) found 1,3% of testicular hypoplasia, which he later on (1972) considered as being congenital. Later *Watt* (1978) reported that the incidence of «atrophy-hypoplasia» was about 14%; he grouped the two lesions together, because of the difficulty in distinguishing between them, as previously pointed out by *McEntee* (1970). Recently, *Burgess* (1983) reported an incidence of «atrophy-hypoplasia» of about 2,9% in a total of 553 rams.

¹ Indirizzo: Prof. A. Gimbo, Via S. Cecilia 30, I-98100 Messina

Bruere et al. (1969) found a chromosome complement XXY in the ram as a possible cause of testicular hypoplasia, comparable to Klinefelter's syndrome. Later, *Hare* (1980) confirmed these findings.

Finally, *Underwood* (1966) put forward the hypothesis that testicular hypoplasia can be induced in West Australian Merino rams by lack of zinc in pastures, and subsequently (1969) reproduced the lesion under experimental conditions.

It therefore appears that the etiopathogenesis and diagnosis of testicular hypoplasia are probably correlated, but are still subject to debate. Therefore we considered it useful to carry out a study of testicular hypoplasia in the ram for the following reasons:

- 1) according to our experience, the disease is frequent in the ram and leads to decreased fertility;
- 2) descriptive knowledge of the disease is insufficient.

Materials and Methods

In the considered geographic area young rams are assigned to reproduction when 8 months old, since at this age they are regarded as sexually mature.

Reproduction is carried out in two different periods of the year i.e., September to November and February to April.

In November 58 rams, cross breed «Bergamasco-Pinzirita», 8–12 months old, were bilaterally orchiectomized. The animals chosen at random, were born and had been brought up in a farm in the Plain of Catania, where no reproductive animals had been brought in for ten years.

As orchiectomy was carried out in the field, we could only collect metric dimensions (length, width, thickness), and not weight. As the three dimensions of the testicle decrease proportionally, we have reported in the table length only.

An anatomo-pathological examination was carried out on each testicle, and parenchymal fragments were taken and fixed in Bouin-Hollande's solution.

Sections (5–6 μ m) were stained with haematoxylin-eosin-orange.

The variability of dimensional, anatomical and histological data induced us to subdivide samples into normal and non-normal ones.

For a better evaluation of the pathological phenomena, the latter have been subdivided into three classes from the nearest to normality (class I) to the farthest (class III). For the evaluation of the tubular diameter, only tubules cut in cross section were measured. The mean diameter of 100 seminiferous tubules, the number of tubules per mm^2 as well as the nature of intratubular cells have been determined.

Results

Anatomo-pathological findings

Apart from the variability of dimensions, no remarkable gross pathological features have been found except for a decrease of the consistency and an increase in the colour of the testicular parenchyma, progressive from class I to class III.

Other lesions (epididymal cysts, inflammation of the tunica vaginalis) were very sporadic.

The table shows clearly the close relationship between testicular length and the other parameters considered. It should be pointed out that mean tubular diameter is inversely proportional to the number of tubules per mm^2 and directly proportional to the decrease of the mean length of testes.

Table 1

Testis	Classes	No. of animals	Testis length (cm)	%	Tubules diameter (μm)	No. of tubules (mm^2)	Types of cells in tubules
Normal	–	22	10,5–8,5	37,92	158	18	Sertoli-Spermatogonia-Spermatocytes-Spermatids-Spermatozoa
Hypo-plastic	1	22	8,4–7	37,92	140	16	Rare foetal Sertoli-Sertoli-Spermatogonia-Spermatocytes-Spermatids-Few spermatozoa
	2	10	6,9–5,5	17,25	120	37	Foetal Sertoli-Sertoli-Spermatogonia-Spermatocytes
	3	4	5,4–3,5	6,90	90	47	Foetal Sertoli-Rare gonocytes-Spermatogonia

This table clearly shows the correlation existing between testis length and other considered parameters. It should be emphasized that the mean tubular diameter is inversely related to the number of tubules/ mm^2 and directly related to the decrease of testis mean length.

Histo-pathological findings

The histological study has been carried out on various (2 to 7) numbers of rams for each class.

Normal class – The seminiferous tubules (mean diameter: $158 \mu\text{m}$) are normally developed and occupied by a seminiferous epithelium including spermatozoa. The interstitial connective tissue often consists of loose fibrils among which one can find Leydig cells (LC). These cells are not numerous and are often widely dispersed.

Class I – The spermatogenesis stops at the spermatid stage in most of the seminiferous tubules (mean diameter: $140 \mu\text{m}$); in some tubules, however, it stops at spermatocyte stage; sperm maturation seldom progresses to spermatozoa. In the first type, spermatids can occupy the whole tubular lumen, and sometimes show some altered morphological features which can be summarized as follows: well defined but not homogeneous cytoplasm containing thick, dark granules; round nuclei circumscribed by a thickened nuclear membrane.

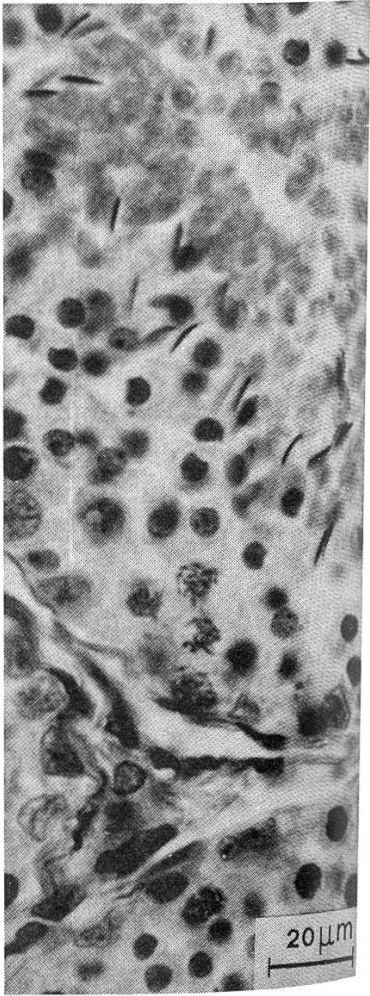
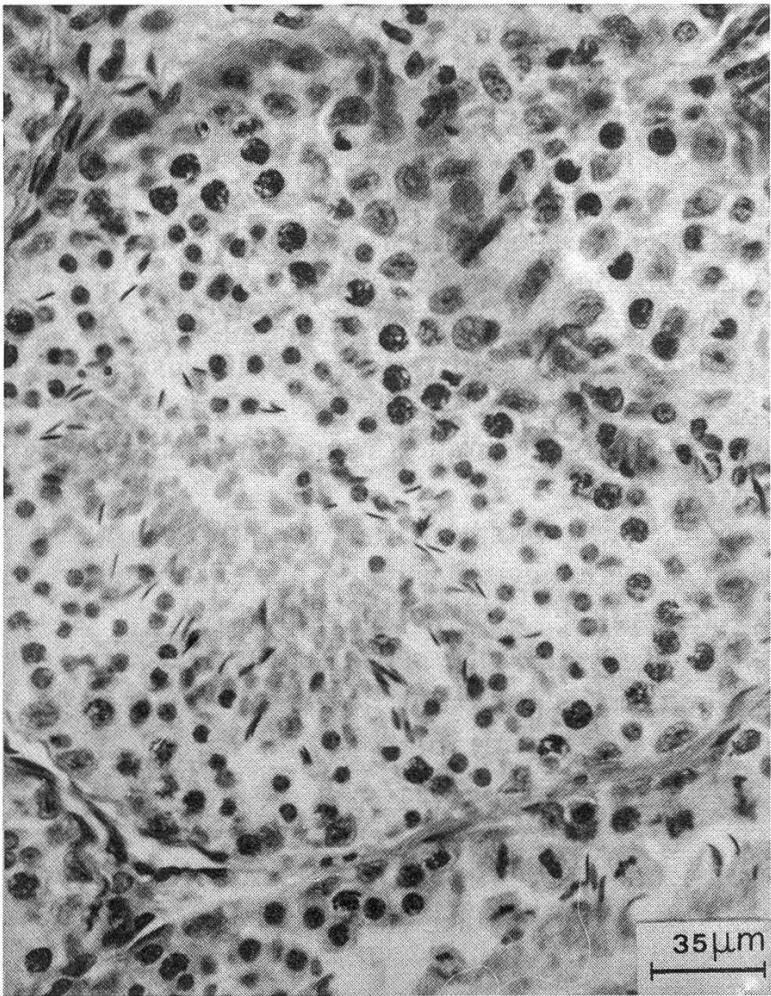
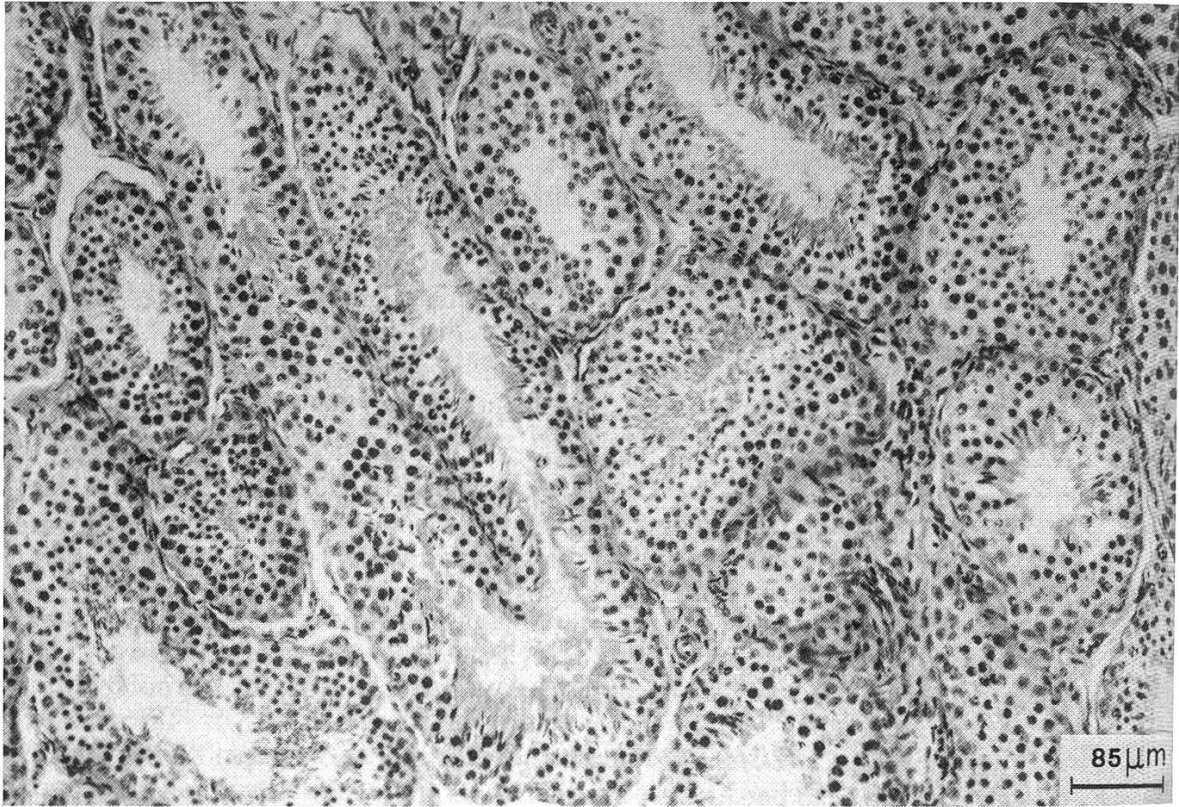
When spermatogenesis stops at the stage of spermatocytes, both spermatogonia and spermatocytes often present a vacuolated cytoplasm and nuclear pycnosis. Peritubular membranes show an irregular outline.

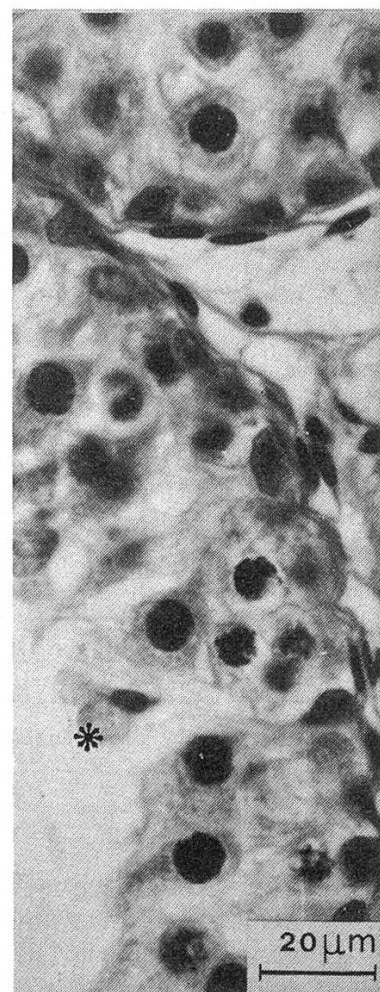
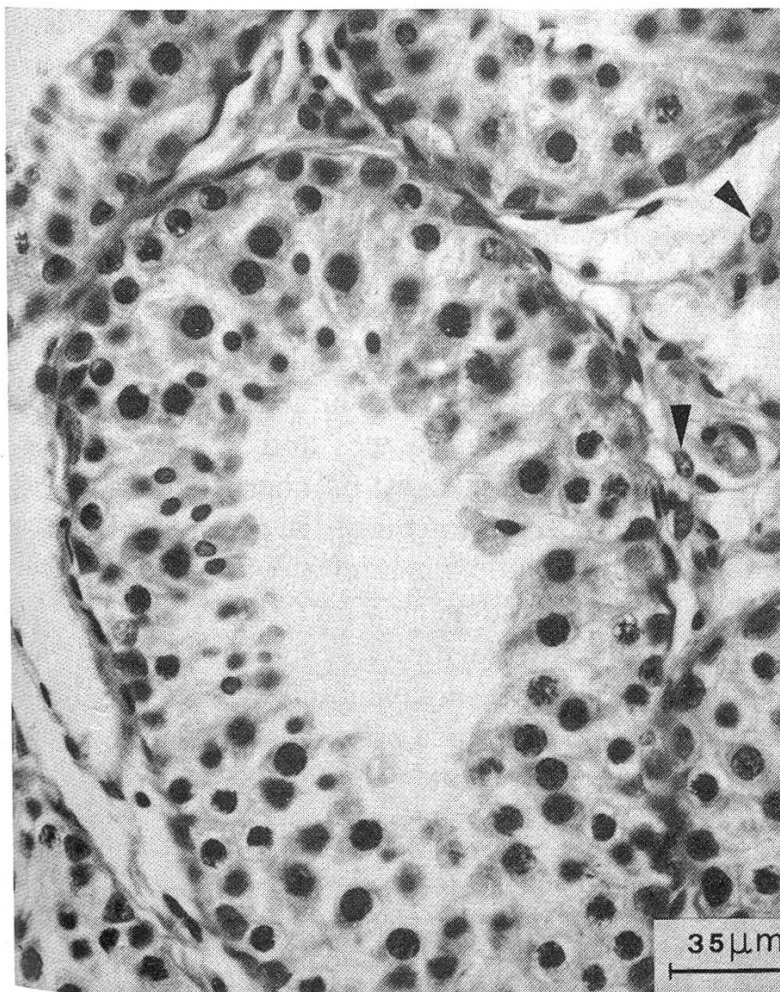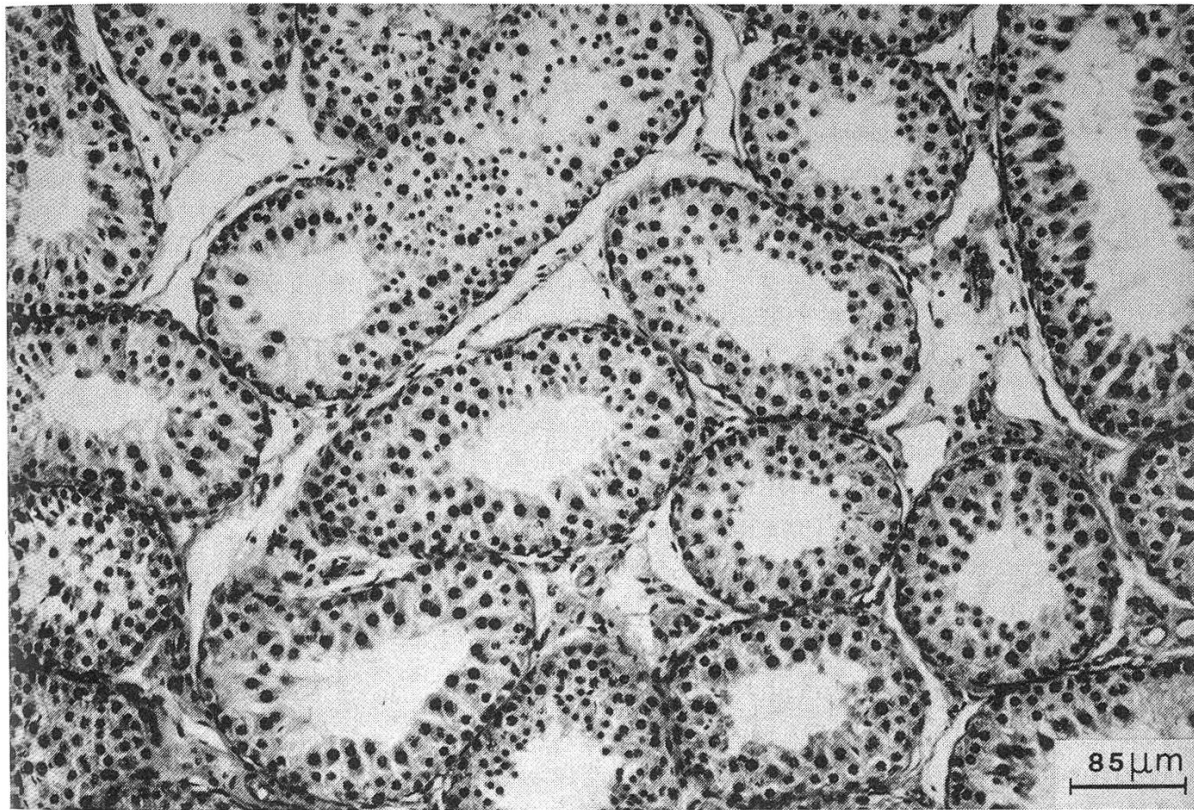
Besides mature Sertoli cells, a lot of foetal Sertoli cells are present, for which the former can be mistaken; they will be described together with class III.

Plate 1: Testis of a normal ram (8 months old). Haematoxylin-eosin-orange.

Plate 2: Ram, testis: 1st class hypoplasia. The lumen of seminiferous tubules is empty; the spermatogenesis stops at the spermatid stage (*). In the interstitial tissue, Leydig cells and fibroblast-like elements (arrows) are present. Haematoxylin-eosin-orange.

1





The interstitial connective tissue often appears loose, consisting of variously oriented, fragmented or oedematous fibrils; Leydig interstitial cells and fibroblast-like elements are present. In some interstitial areas, some cells, probably of Leydig type, have a pycnotic nucleus.

Class II – The seminiferous tubules (mean diameter: 120 μm) have an endotubular content usually reduced when compared with class I and can be populated by one of the following elements:

- a) Foetal Sertoli cells, a few mature Sertoli cells, type A and B spermatogonia arranged in 1–2 layers.
- b) Sertoli cells, type A and B spermatogonia, spermatocytes. The latter are often located at the center of the tubules; their cytoplasm is often vacuolated. In some case, in fact, it appears optically empty though clear, limited by the cell membrane; it appears reduced to a tiny paranuclear rim.

Type A and B spermatogonia are often vacuolated.

- c) The above mentioned elements together with spermatids in only a few cases. The latter often present altered morphological features because of a marked nuclear membrane and a slightly hyperchromatic nucleus. Multinucleate spermatids have been seen as well.

Peritubular membranes present an uneven, undulating outline.

The interstitial areas often show oedema and fragmentation of connective fibers. In some cases, hyalinosis of connective tissue prevails, so that homogeneous areas develop which often enclose Leydig cells with indistinct cytoplasm and pycnotic nucleus.

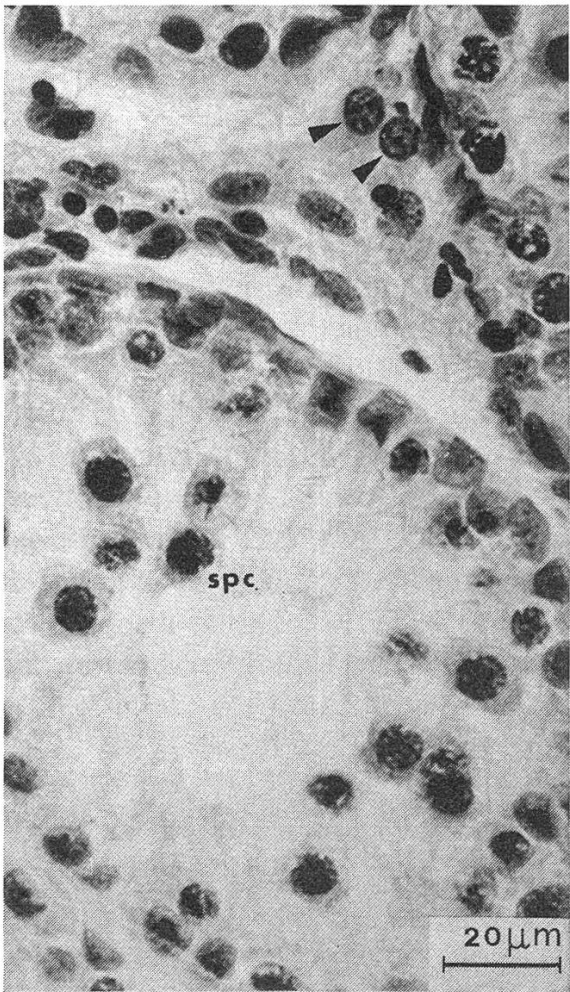
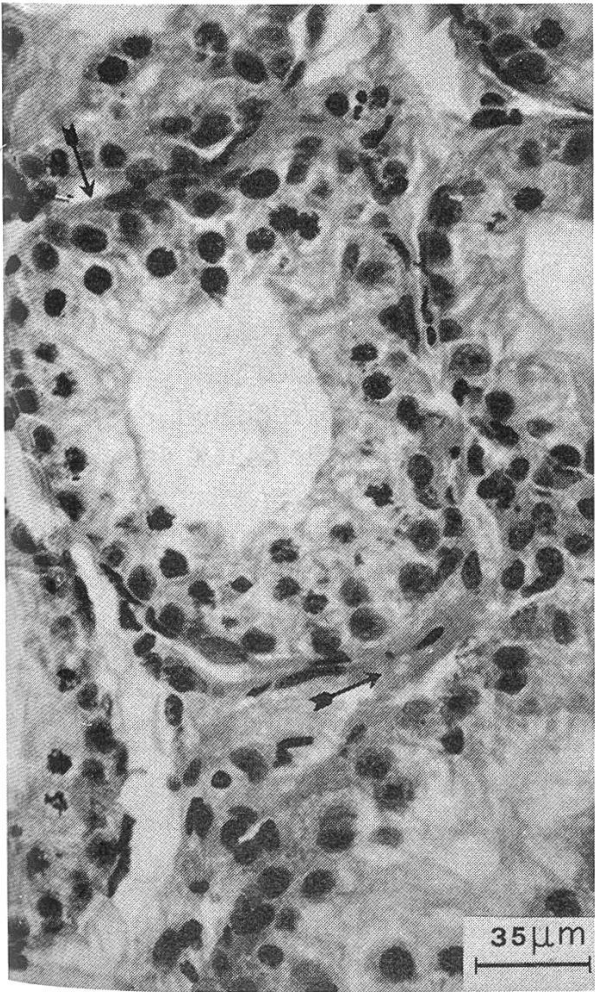
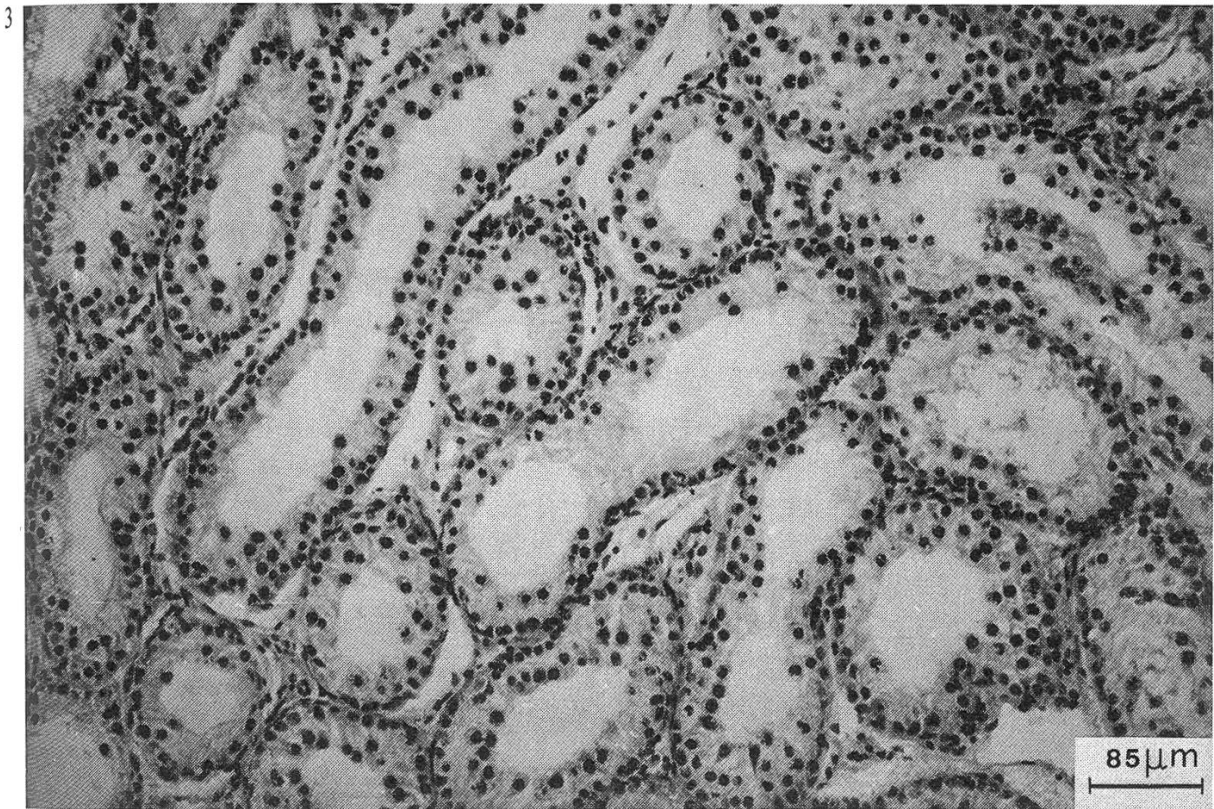
In these areas peritubular membranes may look noticeably oedematous with their thickness increased as much as two or three times or even more; their fibrillar structure is completely replaced by a homogeneous hyaline substance.

Class III – The tubules are appreciably smaller (mean diameter: 90 μm) corresponding to little more than half the normal size (mean diameter: 158 μm).

The tubular content generally consists of a single layer of densely packed cells leaning against the peritubular membrane: in some cases individual cells are visible, either arranged in a second layer or positioned towards the tubular lumen. The parietal layer is made up of numerous foetal Sertoli cells, rare gonocytes and few type A and B spermatogonia. The Sertoli foetal cells are in the greatest number; they have a dense cytoplasm with alignment of the free borders and are arranged in palisade-like fashion. The basally placed nucleus confers them the appearance of a cylindric epithelium.

In other cases, particularly when the tubular lumen is wider, the cytoplasm is moderately expanded with small pseudo-fibrillar interdigitations projecting towards the lumen. The nucleus is small, regular in shape and does not exhibit indentations. The chromatin is generally distributed as fine granulations and a prominent nucleolus is usually present. The morphology is quite different from that of mature Sertoli cells.

Plate 3: Ram, testis: 2nd class hypoplasia. Sertoli cells, spermatogonia and spermatocytes are present generally in most of the seminiferous tubules. The peritubular membranes are oedematous and increased in thickness (arrows). Leydig cells (arrowheads) with indistinct cytoplasm and pre-pycnotic nucleus are present. Spermatocyte (spc). Haematoxylin-eosin-orange.



The peritubular membrane shows an irregular and undulating outline.

The interstitial areas are sometimes occupied by partially fragmented, hyalinised connective fibers.

The interstitial cells are very often fibroblast-like: cytoplasm with indistinct borders; oval, stretched nucleus; very thin, clear and pale chromatine granules. Sometimes, on the contrary, these cells show morphological features close to those of adult Leydig cells; round, oval or polygonal cytoplasm: round nucleus with thickened membrane and peripheral arrangement of chromatine granules.

Discussion

The lesions in the ram are similar to those described by *Lagerlöf* (1957) in the bull, but there are some special features. The frequency of hypoplasia in our samples is high but this could be a result of the small number of animals. It is more probable that it is concerned with the origin of rams, coming all from the same farm, into which no animals had been introduced for reproduction for about ten years. This would confirm the genetical origin of hypoplasia in the ram put forward by *Gunn et al.* (1942), analogous to that of the bovine Swedish breed demonstrated by *Eriksson* (1943; 1950).

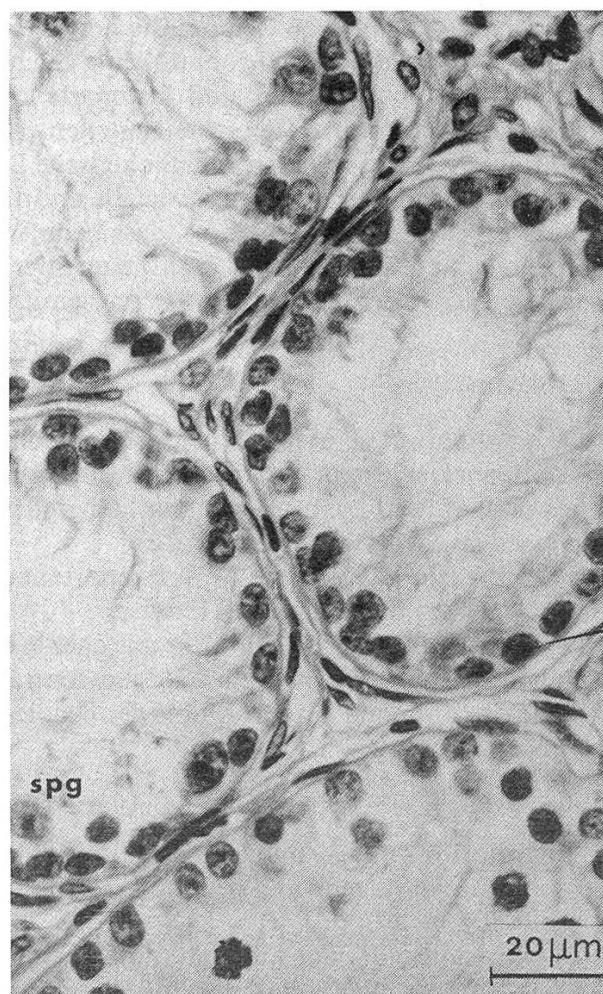
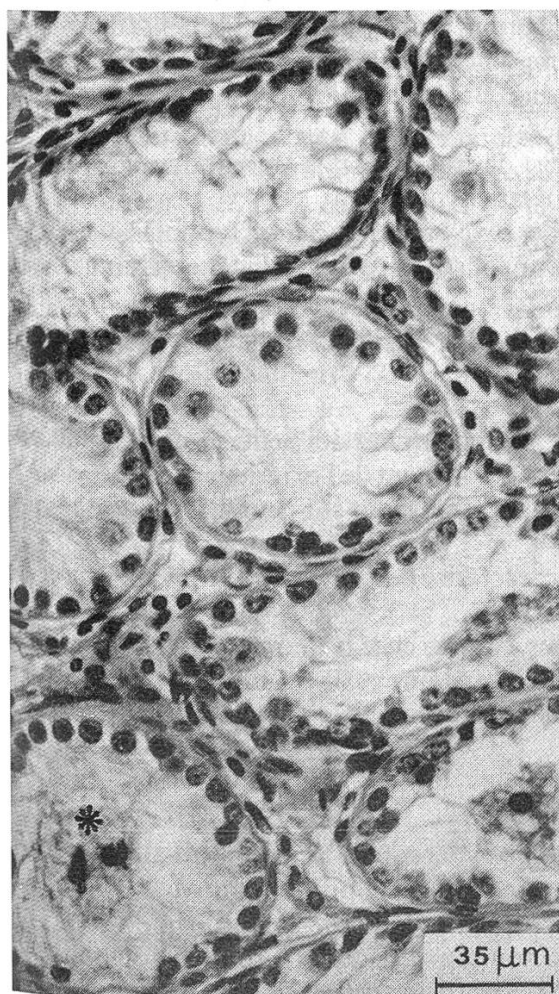
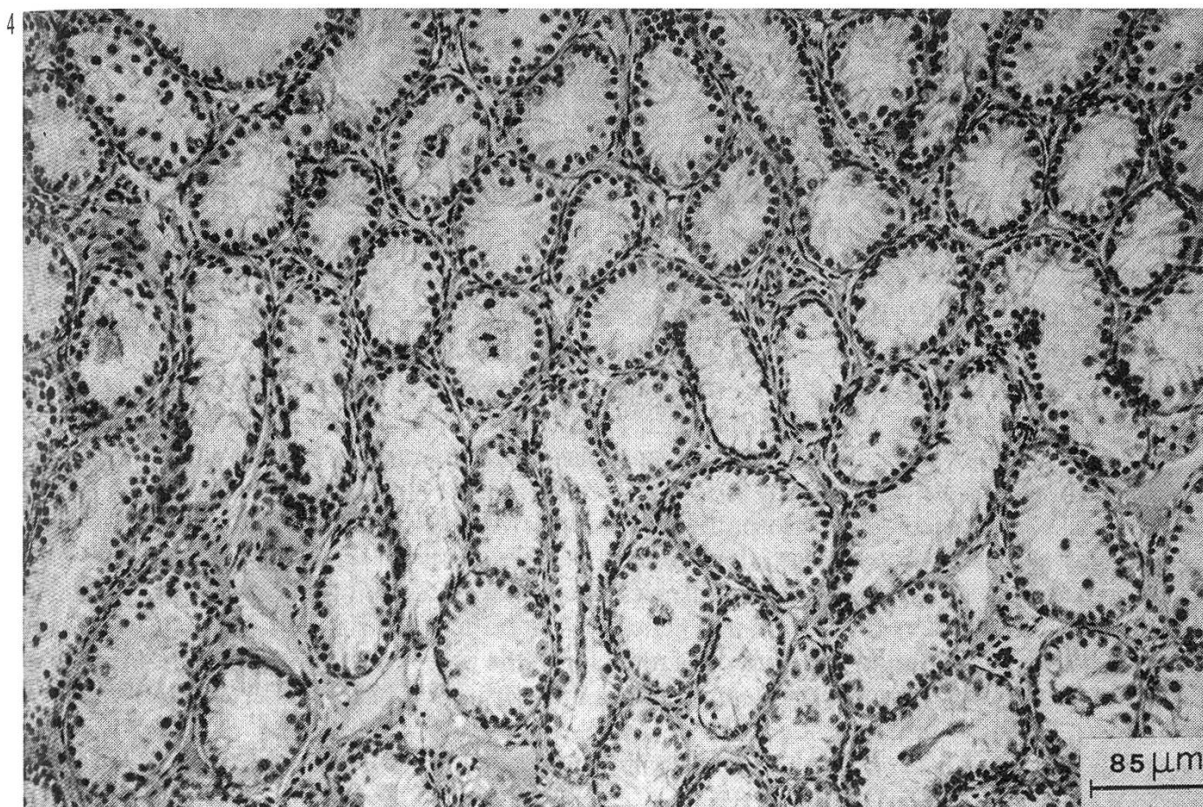
Clinical diagnosis of hypoplasia is actually difficult, because little knowledge is available, and due to the difficulty in gathering individual complete anamneses. Therefore, it is probable that the hypoplasia may be confused with atrophy. Moreover, informations about semen quality are lacking. However, histopathological examination can solve the problem.

Anatomo-pathologically, we observed bilateral hypoplasia in the ram, unlike what happens in the Swedish Highland breed, in which usually only the left testis is affected (*Lagerlöf*, 1934). We have not observed the decreased consistency of the testis pointed out by *Watt* (1978) in the ram.

The histological pattern, as already said, does not differ significantly from what was described by *Lagerlöf* (1957) in the bull. It should be emphasized that there is vacuolation of germ cells (spermatogonia, primary spermatocytes), reported also by *Krishnalingam et al.* (1982) in the zebu and by *Rollinson* (1950) in the goat. In classes II and III, besides germ cells, we have identified «Sertoli foetal cells», previously reported by means of the electron microscope (*Giannetto et al.*, 1984). The occurrence of such cells clearly indicates an abnormal testicular development and leads to new considerations.

Hypoplasia, in fact, has usually been attributed to insufficient or abnormal evolution of the germ cells. One should wonder, from now on, whether it is related to a defective development of the foetal Sertoli cells, which fail to evolve totally or partially towards mature Sertoli cells.

Plate 4: Ram, testis: 3rd class hypoplasia. A single layer of cells leaning against the peritubular membrane is present. The tubular lumen is filled with the cytoplasmic projections of foetal Sertoli cells and with occasional degenerating cells (*). In the interstitial tissue, hyalinised connective fibers are present. Spermatogonium (spg). Haematoxylin-eosin-orange.



If so, the failure of evolution of germ cells would be the result and not the cause of hypoplasia, at least in the ram. Moreover, there are some epiphenomena which also point to the same conclusion: fibrillar fragmentation and local hyalinosis of interstitial tissue; mishappen evolution of some fibroblasts into Leydig cells; occasional degeneration of mature Leydig cells. All these epiphenomena seem to point out the faulty evolution of mesenchyme derived tissue.

We wonder, therefore, if the Sertoli cells also derive from embryonal mesenchyme. Unfortunately the information at present available does not clarify this point.

Summary

Numerous cases of testicular hypoplasia have been found in rams reared on a farm where no reproductive animals had been brought in for ten years.

Anatomo-pathological and histo-pathological observations are described; on this basis a division of the lesions into three classes is proposed.

The most notable feature was frequent presence of foetal Sertoli cells in various numbers.

Finally, a hypothesis is forwarded of a genetic origin of hypoplasia, in the ram as well as in the bull. On the other hand, unlike what happens in the bull, the defective evolution of the spermatogenesis appears to be only secondary to the mishappen differentiation of foetal Sertoli cells into mature Sertoli cells.

Zusammenfassung

Verschiedene Fälle von Hypoplasie der Hoden wurden bei Widdern festgestellt, die aus einer Zucht stammen, in die seit 10 Jahren keine Zuchttiere von ausserhalb eingeführt wurden.

Auf Grund anatomischer und histopathologischer Beobachtungen wird vorgeschlagen, den Grad des Defektes in drei Klassen einzuteilen.

Charakteristisch für das histopathologische Bild ist das regelmässige Vorhandensein von undifferenzierten, fetalen Sertolizellen in der II. und III. Klasse.

Die Verfasser schliessen daraus, dass beim Widder, wie beim Stier, die Hypoplasie der Hoden erblich sein kann und dass im Gegensatz zum Stier die unvollständige Spermiogenese durch eine Entgleisung der Sertolizell-Entwicklung hervorgerufen wird.

Résumé

De nombreux cas d'hypoplasie testiculaire ont été constatés chez des béliers provenant d'un élevage dans lequel on n'avait pas introduit de reproducteurs provenant de l'extérieur depuis 10 ans.

Les observations anatomo-histopathologiques sont présentées et sur cette base, une division en trois classes de ces lésions est proposée.

L'aspect histopathologique le plus important est caractérisé par la présence constante de cellules de Sertoli foetales dans la II et III classe.

Les Auteurs émettent l'hypothèse que chez le bélier, comme chez le taureau, l'hypoplasie testiculaire peut avoir une base génétique mais que, contrairement au taureau, le défaut de la spermatogénèse est secondaire au manque d'évolution des cellules de Sertoli foetales.

Riassunto

Gli Autori osservano numerosi casi di ipoplasia testicolare dello ariete in un allevamento nel quale da 10 anni non venivano introdotti riproduttori dall'esterno e propongono una divisione in 3 classi della lesione.

Tale divisione è basata sui risultati dell'esame anatomo-patologico (dimensione del testicolo) e dell'esame istopatologico (diametro medio tubulare; popolazione cellulare endotubulare).

Dopo aver fornito una estesa descrizione delle cellule contenute all'interno dei tubuli nelle varie classi della lesione, gli AA. si soffermano in particolare sulla variabile ma costante presenza delle cellule di Sertoli fetali che sostituiscono parzialmente o totalmente le cellule di Sertoli mature.

Viene infine emessa l'ipotesi che nell'ariete, come nel toro, la ipoplasia testicolare possa avere una base genetica; ed altresì che diversamente dal toro, il difetto evolutivo delle cellule della linea germinale sia soltanto secondario alla mancata evoluzione delle cellule di Sertoli fetali in cellule di Sertoli mature.

References

- Bruere A. N., Marshall R. B., and Ward D. P. J.*: Testicular hypoplasia and XXY sex chromosome complement in two rams: the ovine counterpart of Klinefelter's syndrome in man. *J. Reprod. Fert.* 19, 103–108 (1969). – *Burgess G. W.*: An abattoir survey of lesions in the scrotal contents of rams. *Austr. Vet. J.* 60, 85–86 (1983). – *Eriksson K.*: Hereditary forms of sterility in cattle. Lund, Hakan Ohlssons (1943). – *Eriksson K.*: Heritability of reproductive disturbances in bulls of Swedish red and white cattle. *Nord. Vet. Med.* 2, 943–966 (1950). – *Giannetto S., Gimbo A. and Zanghi A.*: Prime osservazioni ultrastrutturali sulla ipoplasia testicolare dell'ariete. *Atti Soc. It. Sci. Vet.* 38, 334–336 (1984). – *Gimbo A., Zanghi A., Giannetto S. and Berardino D.*: Indagini strutturali, ultrastrutturali, citogenetiche e ormonali su un caso di ipoplasia testicolare del bovino. *Atti Soc. It. Buiatria* 17, 473–490 (1985). – *Gunn R. M. C., Sanders R. N. and Granger W.*: Studies in fertility in sheep. *Bull. Counc. Scient. Ind. Res. Melb.*, N° 148 (1942). – *Hare W. C. D.*: Cytogenetics. In *Current Therapy in Theriogenology*, pp. 117–154, Ed Morrow, D. A. Saunders Company, Philadelphia (1980). – *Krishnalingam V., Ladds P. W. and Entwistle K. W.*: Quantitative macroscopic and histological study of testicular hypoplasia in *Bos indicus* strain bulls. *Res. Vet. Sci.* 32, 131–139 (1982). – *Lagerlöf N.*: Morphologische Untersuchungen über Veränderungen im Sperma und in den Hoden bei Bullen mit Verminderter oder aufgehobener Fertilität. *Acta Path. Microbiol. Scand.*, suppl. 19, 1–254 (1934). – *Lagerlöf N.*: Biological aspects of infertility in male domestic animals. *Int. J. Fertil.* 2, 99–129 (1957). – *McEntee K.*: The male genital system. In *Pathology of domestic animals*, Vol. I, pp. 443–454, Eds Jubb. K. V. & Kennedy, P. C. Academic Press, N. Y., London (1970). – *Miller S. J. and Moule G. R.*: Clinical observations on the reproductive organs of merino rams in pastoral queensland. *Aust. vet. J.* 30, 353–363 (1954). – *Rollinson D. H. L.*: A case of bilateral testicular hypoplasia in the goat. *Vet. Rec.* 62, 303–304 (1950). – *Underwood E. J.*: The mineral nutrition of livestock. Commonwealth Agricultural Bureaux, Roma, FAO (1966). – *Underwood E. J. and Somers M.*: Studies of zinc nutrition in sheep. I. The relation of zinc to growth, testicular development and spermatogenesis in young rams. *Aust. J. Agric. Res.* 20, 889–897 (1969). – *Watt D. A.*: Testicular abnormalities and spermatogenesis in the Merino ram. M.V.Sc. Thesis, Univ. Sydney (1971). – *Watt D. A.*: Testicular abnormalities and spermatogenesis of the ovine and other species. *Vet. Bull.* 42, 181–190 (1972). – *Watt D. A.*: Testicular pathology of Merino rams. *Aust. vet. J.* 54, 473–478 (1978).

Registrazione del manoscritto: 13 aprile 1987