

Zeitschrift: Bulletin der Schweizerischen Akademie der Medizinischen Wissenschaften = Bulletin de l'Académie suisse des sciences médicales = Bollettino dell' Accademia svizzera delle scienze mediche

Herausgeber: Schweizerische Akademie der Medizinischen Wissenschaften

Band: 2 (1946-1947)

Heft: 4

Artikel: Lare improvement of a case of congenital athyroid dwarfism with intrasellar alteration

Autor: Franceschetti, A. / Bamatter, F. / Klein, D.

DOI: <https://doi.org/10.5169/seals-306841>

Nutzungsbedingungen

Die ETH-Bibliothek ist die Anbieterin der digitalisierten Zeitschriften auf E-Periodica. Sie besitzt keine Urheberrechte an den Zeitschriften und ist nicht verantwortlich für deren Inhalte. Die Rechte liegen in der Regel bei den Herausgebern beziehungsweise den externen Rechteinhabern. Das Veröffentlichen von Bildern in Print- und Online-Publikationen sowie auf Social Media-Kanälen oder Webseiten ist nur mit vorheriger Genehmigung der Rechteinhaber erlaubt. [Mehr erfahren](#)

Conditions d'utilisation

L'ETH Library est le fournisseur des revues numérisées. Elle ne détient aucun droit d'auteur sur les revues et n'est pas responsable de leur contenu. En règle générale, les droits sont détenus par les éditeurs ou les détenteurs de droits externes. La reproduction d'images dans des publications imprimées ou en ligne ainsi que sur des canaux de médias sociaux ou des sites web n'est autorisée qu'avec l'accord préalable des détenteurs des droits. [En savoir plus](#)

Terms of use

The ETH Library is the provider of the digitised journals. It does not own any copyrights to the journals and is not responsible for their content. The rights usually lie with the publishers or the external rights holders. Publishing images in print and online publications, as well as on social media channels or websites, is only permitted with the prior consent of the rights holders. [Find out more](#)

Download PDF: 16.09.2025

ETH-Bibliothek Zürich, E-Periodica, <https://www.e-periodica.ch>

Late Improvement of a Case of Congenital Athyroid Dwarfism with Intracellular Alteration

By A. Franceschetti, F. Bamatter and D. Klein (Geneva)

In the course of our research on the relation between the dysostocias and ocular affections we became acquainted with a case of dwarfism of which the facies strangely resembled that which one finds in dysostocias of the Hurler-Morquio type, known in England as *Gargoylism*. On her admission to the clinic we verified the fact that the child did not present the corneal affection typical of the Hurler type and that it was not a question of gargoylism, but of myxœdematous dwarfism.

In view of the extreme rarity of complete athyroids, untreated up to an advanced age, it seemed opportune that we should present here such a case, not only because of the hereditary question which it suggests, but also because of the effect of therapeutics, which we were able to study, thanks to the financial aid of the Swiss Academy of Medical Sciences and the Hoffmann-La Roche company.

Case History: Thérèse Ge. (born March 14, 1932).

Condition on Admission (June 21, 1945): Girl of 13½ years, weighing 15 kg and with a height of 81 cm. A disproportionate dwarf with a brachycephalic type of head relatively large in proportion to her body. A face of surprising ugliness, puffy like that of an old woman. The heavy appearance of the facies is due especially to œdema of the cheeks, nose, eyelids and chin. The base of her nose is retracted, the nose itself is large and flattened, the lips thickened, dry and chapped. Her large mouth is half open with a voluminous tongue protruding. There are only rotten stumps of teeth in irregular position.

It is difficult to detect a neck; her head seems to rest directly on her shoulders. The thyroid is not palpable. In both supra-clavicular spaces as well as in the region anterior to the axillae are flabby cutaneous bags.

The abdomen is prominent and flabby with diastasis recti and umbilical hernia, and the level of the navel is lowered. There are no signs of secondary sexual development.

The child remains prone like a baby, without many reactions; her legs are folded towards her abdomen and her knees pulled up to her chin. Her back seems to have no muscular strength. One has to lift the child up and hold her under the shoulders to make her stand (fig. 1).

Nervous System. The tendon reflexes are active; there are exaggerated and symmetrical patellars with widening of the reflex zone, and accentuated achilles reflexes. Very pronounced Babinski on the right with fan-like phenomenon. Dorsi-flexion of the big toe is also spontaneous on the right. On the left the Babinski is negative. No other pathological reflexes.

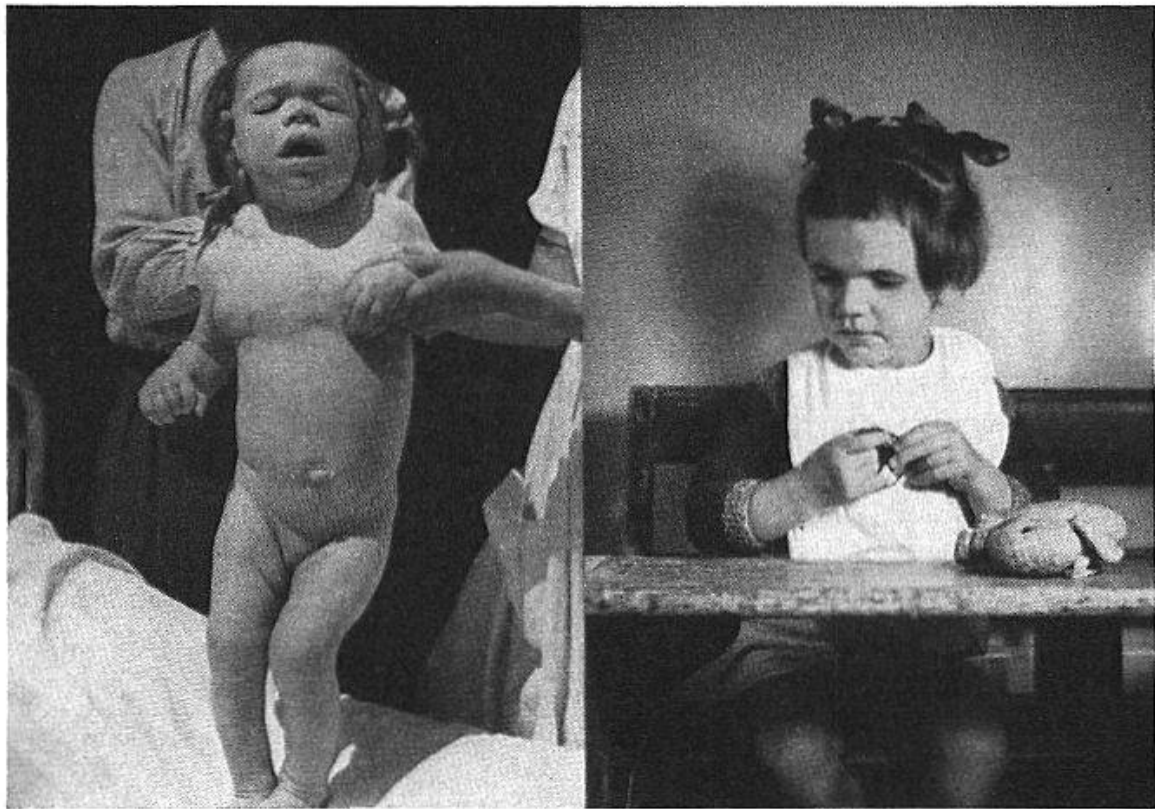


Fig. 1. Thérèse Ge., 13½ years, height of 81 cms. Congenital athyroid dwarfism.

Fig. 2. The same child after one year of treatment.

Mental Attitude. We have here a being extremely deficient in all psychic functions. She takes no interest in what goes on around her, nor can her attention be stimulated. Her look, already impeded by the swelling of her eyelids, is inexpressive. At meal time when one is obliged to feed her like a suckling, she comes out of her usual apathy and swallows her soft food ravenously. She is not clean at all and even plasters her face and hair with her excreta.

Radiological Examination:

Skull. Lack of fusion of the sutures unusual at this age. Agenesis of the frontal and sphenoidal sinuses; likewise the petro-mastoid masses are not filled with air spaces.

Sella turcica. Of normal dimensions, rounded, containing calcifications in the inferior part, visible in both profiles.

Spinal Column. Development is considerably retarded. There is Spina Bifida in L₅-S₁, and platyspondyly.

Arms. Shortening of the long bones. Considerable delay in the centers of ossification, especially at the level of the carpals where only the capitate and the hamate are seen.

Legs. The same changes are seen as in the arms. Only the astragalus, calcaneus and cuboid are ossified.

Thorax. The lungs are clear. The total volume of the heart is increased (myxœdematous heart).

Laboratory Findings:

Blood Examination (June 30, 1945). Erythrocytes 2700 000. Hæmoglobin 58%. Colour index 1.07. Leukocytes 5700. Erythropoiesis and myelopoiesis are practically absent in the specimen obtained by puncture of the tibia. Wassermann and Kahn are negative.

Blood Chemistry. Total cholesterol 311 mg%; therefore obviously elevated (the

normal value is 150 to 200). Serum iron (which is also elevated) 140 mg%. The other serological examinations are all normal.

Basal Metabolism (July 9, 1945). Lowered to -30.9% .

Family History. The child comes from a family of wandering cauldron- and basket-makers who are widely scattered in the Grisons and in central Switzerland, and among whom *J. Jörger* has already described a collection of hereditary defective qualities as well as bad social adaptation. In the same family one of us (*Klein*) has just published a case of phenylpyruvic dwarfism.

Our patient, suffering from congenital athyroidism, has been proven to be on both sides a second cousin of this case of phenylpyruvic idiocy. In the genealogical tree one finds also deaf-mutes, psychopaths and an increased infant mortality rate. A similar polymorphism of hereditary deficiencies speaks in favour of a constitutional element and against an exogenous factor. This is so much the more important because idiopathic athyroidism is too often put in the class of endemic cretinism. One of us (*Bamatter*) has also treated two cases of congenital hypothyroidism coming from a consanguinous marriage, which proves that in certain forms of hypo- and athyroidism the hereditary factor may play an important role. Finally, let us note that *Gordon*, who has collected 340 cases of infantile myxœdema from the American and Canadian literature, including 60 cases of *Osler's*, found no relation between the geographic distribution of childhood myxœdema on the one hand and the regions of endemic goitre on the other. That is why this author, like many others elsewhere, has suggested abolishing the inexact expression "sporadic cretinism" in favour of "idiopathic infantile myxœdema".

Considering now the history of congenital myxœdema, we find that it was essentially English and Swiss authors who contributed to this problem (*Curling, Fagge, Beach, Gull, Ord, Reverdin, Kocher*).

Based on these physio-pathological and surgical experiences, which established the connection between myxœdema and thyroid insufficiency, *Bourneville* and *Bricon*, in their masterful work in 1886, collected all cases of "cretinoid idiocy". One of their own cases, named "Pacha de Bicêtre", who died at the age of 24 years, has become famous as the prototype of complete athyroidism. Autopsy proved the complete absence of his thyroid gland and further the existence of "*an appreciably thickened and hypertrophied pituitary body*".

Let us note also that several other authors (*Rogowitsch, Ponfick, Boyce* and *Beadles*, etc.) have reported accessory changes in the pituitary gland, sometimes hypertrophic, sometimes atrophic, in certain cases of hypo- and athyroidism. In our case this pituitary alteration shows itself

in the X-Ray as *calcification at the level of the lower portion of the sella turcica*.

Among the authors who have also been able to follow such extreme forms of myxœdematous idiocy, untreated up to puberty, of which "Pacha de Bicêtre" has become the prototype, we mention *Jeandelize, W. Scholz, Nobel, Wieland*. All these cases, incidently very rare in the literature, have an almost "familial" resemblance.

Progress of the case. The child received at first a quarter of a tablet of "Thyreoglandol-Roche" four times a day (0,3 gm. of fresh gland daily). The first symptom noted was a rapid loss of weight accompanying a marked diuresis. The child had no more appetite, began to vomit and became visibly weaker. Signs of thyrotoxicosis appeared also in psychomotor and emotional form. She was shaken by violent fits of laughter, lasting up to five consecutive hours, sometimes alternating with fits of crying.

After stopping the thyroid medication, the signs of thyrotoxicosis promptly ceased. Somewhat later we began again very cautiously the specific therapy, giving up to five drops of "Thyroxine-Roche" (0,0003 gm.) or up to a half tablet of "Thyreoglandol-Roche" (0,15 gm. of thyroid gland) daily, which was then well tolerated.

In considering the result of treatment after one year we want to distinguish between the psychic and the somatic improvement.

If the child formerly resembled a purely vegetative being, now she shows a certain degree of interest in her environment, although still very primitive. She reacts to noise and to people approaching her. She grasps extended objects and plays with them like a little baby. Instead of the former apathy, she shows today a great need for movement; she tries to get up from her bed and several times has even climbed over the side of the bed. She is learning to walk and, finally, we only have to hold her hand for her to succeed in doing it. Her face formerly repulsive in its ugliness, has become more attractive (fig. 2); her expression scarcely differs from that of a four-year old girl. There is no more trace of myxœdema. Her growth has increased from 81 to 93.5 cm. In the X-Rays one can see that the development of the centers of ossification has reached the stage of five years. In place of the initial anæmia we now have 4,070,000 Erythrocytes and a Hæmoglobin of 83%.

Besides the important hereditary question, interest in this case rests in the fact that more than 50 years after the introduction of the therapy of substitution, inaugurated by *Murray* in 1891, we have still been able to find a classic example of the type of "Pacha de Bicêtre", and this in a country where both doctors and pharmaceutical products are abundant.

If in general one is lucky enough to be able to present the first case of a rare malady, we would be happy here to be able to affirm, with the eminent thyriopathologist *Wegelin*, that this case may be a relic of an era that has passed away.

(The examination will be published *in extenso* in the *Helvetica paediatrica acta*.)

Summary

A description of a myxœdematous female idiot of 13½ years and a height of 81 cm, coming from a family of wandering cauldron- and basket-makers, in which there has already been described a case of phenylpyruvic dwarfism. The bone-age of the patient corresponded to the fifth month of extrauterine life. There was calcification of the hypophyseal region, anæmia, relative lymphocytosis, and medullary hypoplasia. The child was treated with "Thyreoglandol" and "Thyroxine-Roche" for one year. The results were remarkable: growth to 93,5 cm, development of the centers of ossification to the stage of 5 years, normalisation of the face, appreciable improvement of her comportment and somewhat also of her intellectual functions. Discussion of the heredity of this case, based also on another personal observation of two hypothyroid children coming from a consanguinous marriage.

Zusammenfassung

Beschreibung eines 13½jährigen, 81 cm großen, myxœdematösen, idiotischen Mädchens, aus einer schwer neuropathisch belasteten Korber- und Kesselflickerfamilie der Innerschweiz stammend, aus der bereits ein Fall von phenylpyruvischem Zwergwuchs hervorgegangen ist. Das Knochenalter der Kranken entsprach demjenigen der ersten extrauterinen Lebensmonate. Besonders erwähnenswert sind Verkalkungen im Bereich der Hypophyse, Anämie mit relativer Lymphozytose sowie Knochenmarkshypoplasie. Einjährige Behandlung mit «Thyreoglandol»- und «Thyroxin»-Roche. Der therapeutische Erfolg bestand in einer Größenzunahme bis zu 93,5 cm, einer Entwicklung der Knochenkerne bis zum Stadium eines 5jährigen Kindes, einer Verbesserung des Gesichtsausdruckes, einer ausgesprochenen Hebung des affektiven Befindens, sowie einer etwas weniger deutlichen Verbesserung der intellektuellen Funktionen. Diskussion der Erblichkeitsverhältnisse dieses Falles, unter Mitherrücksichtigung einer weiteren persönlichen Beobachtung zweier hypothyreotischer Kinder aus einer Vetternehe ersten Grades.

Résumé

Description d'une fillette idiote, myxœdémateuse, de 13½ ans, mesurant 81 cm, descendant d'une famille de chaudronniers-vanniers tarée,

dans laquelle il y a déjà eu un cas de nanisme phenylpyruvique. L'âge osseux de la malade correspondait aux premiers mois de la vie extra-utérine. Calcification de la région hypophysaire. Anémie, lymphocytose relative, hypoplasie médullaire. Traitement au «Thyréoglandol» et à la «Thyroxine»-Roche pendant une année. Effet remarquable: croissance jusqu'à 93,5 cm, centres d'ossification développés au stade de 5 ans, normalisation de la physionomie, amélioration sensible du comportement affectif et légère des fonctions intellectuelles. Discussion de l'hérédité, en s'appuyant aussi sur une autre observation personnelle de deux enfants hypothyroïdiens issus d'un mariage consanguin.

Riassunto

Descrizione di un caso di idiotismo mixedematoso in una bambina di anni 13½, alta 81 cm, proveniente da una famiglia di calderai ambulanti tarata, nella quale già si è registrato un caso di nanismo fenilpiruvico. Lo sviluppo osseo della malata corrispondeva a quello dei primi mesi di vita estra-uterina. Calcificazione della regione ipofisaria. Anemia con limfocitosi relativa, ipoplasia del midollo osseo. Terapia al Tiroglandol e alla Tiroxina-Roche per un anno. Risultato notevole: aumento di statura, fino a 93½ cm, centri di ossificazione arrivati allo stadio dello sviluppo di 5 anni, normalizzazione della fisionomia, miglioramento sensibile del comportamento affettivo e leggero delle funzioni intellettuali. Discussione del fattore ereditario, basandosi anche su un'altra osservazione personale di 2 ipotiroidici, figli di genitori consanguinei.

Beach, F.: J. ment. Sci. **22**, 261 (1876). – *Bourneville and Bricon, P.*: Arch. Neur. **12**, 137, 292 (1886). – *Boyce, R., and Beadles, C. F.*: J. Path. a. Bacter. **1**, 223 (1892). – *Curling, T. B.*: Med. Chir. Trans. **33**, 303 (1850). – *Fagge, C. H.*: Med. Chir. Trans. **54**, 155 (1871). – *Gordon, M. B.*: Endocrinology (Am.) **6**, 235 (1922). – *Gull, W.*: Trans. Clin. Soc. London **7**, 180 (1874). – *Jeandelize*: Insuffisance thyroïdienne et parathyroïdienne. Baillière et fils, Paris 1903. – *Jörger, J.*: Psychiatrische Familiengeschichten. Jul. Springer, Berlin 1919. – *Klein, D.*: Mschr. Psychiatr. **111**, 273 (1946). – *Kocher, Th.*: Arch. klin. Chir. **29**, 254 (1883). – *Murray, G. R.*: Brit. med. J. 1891 II, 796). – *Nobel, E., Kornfeld, W., and Ronald, A.*: Schilddrüsenerkrankungen im Kindesalter. W. Maudrich, Wien 1935. – *Ord, W. M.*: Med. Chir. Trans. **61**, 57 (1878). – *Osler, W.*: Quoted by *Gordon, M. B.*, in: Endocrinology (Am.) **6**, 235 (1922). – *Ponfick, E.*: Z. klin. Med. **38**, 1 (1899). – *Reverdin, J. L., and Reverdin, A.*: Rev. méd. Suisse rom. **3**, 169, 233, 309 (1883). – *Rogowitsch, N.*: Beitr. path. Anat. (Zieglers) **4**, 453 (1888/89). – *Scholz, W.*: Myxödem. In: Spezielle Pathologie und Therapie innerer Krankheiten, edited by Kraus and Brugsch, Vol. 1. Berlin and Wien 1919. – *Wegelin, C.*: Praxis **35**, 601 (1946). – *Wieland, E.*: Die Athyreosis und Hypothyreosis im Kindesalter. Vol. 7 of: Zwanglose Abhandlungen aus dem Gebiete der inneren Sekretion. Edited by W. Berblinger. A. Barth, Leipzig 1940.