

Zeitschrift: Acta Tropica
Herausgeber: Schweizerisches Tropeninstitut (Basel)
Band: 41 (1984)
Heft: 3

Artikel: The influence of lymphatic drainage in experimental "Trypanosoma cruzi" infection
Autor: Bijovsky, A. Tania / Milder, Regina V. / Abrahamsohn, Ises A.
DOI: <https://doi.org/10.5169/seals-313294>

Nutzungsbedingungen

Die ETH-Bibliothek ist die Anbieterin der digitalisierten Zeitschriften auf E-Periodica. Sie besitzt keine Urheberrechte an den Zeitschriften und ist nicht verantwortlich für deren Inhalte. Die Rechte liegen in der Regel bei den Herausgebern beziehungsweise den externen Rechteinhabern. Das Veröffentlichen von Bildern in Print- und Online-Publikationen sowie auf Social Media-Kanälen oder Webseiten ist nur mit vorheriger Genehmigung der Rechteinhaber erlaubt. [Mehr erfahren](#)

Conditions d'utilisation

L'ETH Library est le fournisseur des revues numérisées. Elle ne détient aucun droit d'auteur sur les revues et n'est pas responsable de leur contenu. En règle générale, les droits sont détenus par les éditeurs ou les détenteurs de droits externes. La reproduction d'images dans des publications imprimées ou en ligne ainsi que sur des canaux de médias sociaux ou des sites web n'est autorisée qu'avec l'accord préalable des détenteurs des droits. [En savoir plus](#)

Terms of use

The ETH Library is the provider of the digitised journals. It does not own any copyrights to the journals and is not responsible for their content. The rights usually lie with the publishers or the external rights holders. Publishing images in print and online publications, as well as on social media channels or websites, is only permitted with the prior consent of the rights holders. [Find out more](#)

Download PDF: 04.08.2025

ETH-Bibliothek Zürich, E-Periodica, <https://www.e-periodica.ch>

¹ Inst. Med. Trop. S. Paulo – Fac. Medicina;

² Depto Parasitologia, Inst. C. Biomédicas;

³ Depto Imunologia, Inst. C. Biomédicas;

⁴ Depto Patologia, Fac. Med. Vet. Zootec., USP, São Paulo, Brasil

The influence of lymphatic drainage in experimental *Trypanosoma cruzi* infection

A. TANIA BIJOVSKY¹, REGINA V. MILDER², ISES A. ABRAHAMSOHN³,
I. L. SINHORINI⁴, M. MARIANO⁴

Summary

The rapid disappearance of infective forms of *Trypanosoma cruzi* from the site of inoculation as well as the initial phase of infection produced by the parasite are not yet fully understood. To investigate this problem we used the hamster as an animal model considering the existence of the cheek pouch – a peculiar region devoid of lymphatic vessels. *T. cruzi* trypomastigotes were inoculated into the cheek pouch or into the footpad of animals previously infected or not with the same parasite. The results were followed from 3 up to 21 days post-inoculation, by histological examination. In the cheek pouch of normal animals a large number of parasites could be seen up to 15 days post-inoculation and the inflammatory infiltrate had a focal distribution. Conversely, in the footpad the infiltrate was diffuse and no parasites could be detected. These observations indicate that the lymphatic system is the main route of *T. cruzi* dissemination from the site of inoculation. When hamsters were first inoculated in the footpad and 7 days later in the pouch, the inflammatory infiltrate at this point was less aggressive and no parasites could be detected.

Key words: *Trypanosoma cruzi*; lymphatic drainage; Chagas' disease; hamster's cheek pouch.

Introduction

The first contact of the infective forms of *Trypanosoma cruzi* with the vertebrate host occurs at the inoculation site. The type of inflammatory response elicited at the initial phase of infection and the route of escape of the parasite

Correspondence: Dra. Regina V. Milder, Instituto de Ciências Biomédicas, USP,
P.O. Box 4365, 0100 São Paulo, SP, Brasil

from this site, whether by lymphatics or through blood vessels, are aspects of the disease not yet fully investigated (Taliaferro and Pizzi, 1955; Rubio, 1959; Deutschlander et al., 1978).

Attempting to answer these questions we undertook some experiments using the hamster animal model because of the peculiar characteristics of the connective tissue which underlays the epithelium of the cheek pouch of these animals, i.e. the absence of lymphatic drainage (Barker and Billingham, 1977). Similarly to previous experiments in which BCG was used as the infective particle (Mariano and Sinhorini, 1980) we inoculated the parasite into the subcutaneous tissue of the pouch or into the footpad of animals previously infected or not with the protozoa. The inflammatory response induced by the parasite at these sites of inoculation was investigated and the results demonstrated that the lymphatic vessel was the main route by which the parasite dissemination occurs in the mammalian host. Moreover, we have shown that the parasite was not found in the connective tissue of the pouch when the animal was previously infected with the protozoa.

Material and Methods

Animals: Male and female hamsters (*Mesocricetus auratus*) weighing about 120 g were used throughout this study.

Parasites: Bloodstream forms of *T. cruzi* of the Y strain maintained in mice by weekly passage were used as inoculum. Trypomastigotes were isolated from heparinized blood by centrifugation. The parasites were suspended in NaCl 0.15 M and 20 μ l containing either 5×10^3 forms (low dose) or 2×10^5 (high dose) were used as inoculum.

Sites of inoculation: Two sites of inoculation were used: the plantar site of the hind paw and the connective tissue of the distal portion of the cheek pouch. For the inoculation of parasites into the pouch, the animals were previously anesthetized with sodium pentobarbital. This procedure was necessary in order to be sure that the inoculation was done at the distal portion of the pouch, the only place devoid of lymphatic drainage (Barker and Billingham, 1977).

Experimental design: Three groups of experiments were performed: a group of animals was inoculated in the footpad; another in the connective tissue of the pouch and a third group was injected with parasites into the footpad followed by a second inoculation with *T. cruzi* into the pouch seven days later. Three animals of each group were killed 3, 7, 14 and 21 days following the last inoculation. The cheek pouches, the footpads and their vicinal lymph nodes, salivary glands, heart, skeletal muscle, liver and spleen, were collected for histological examination. The tissues were

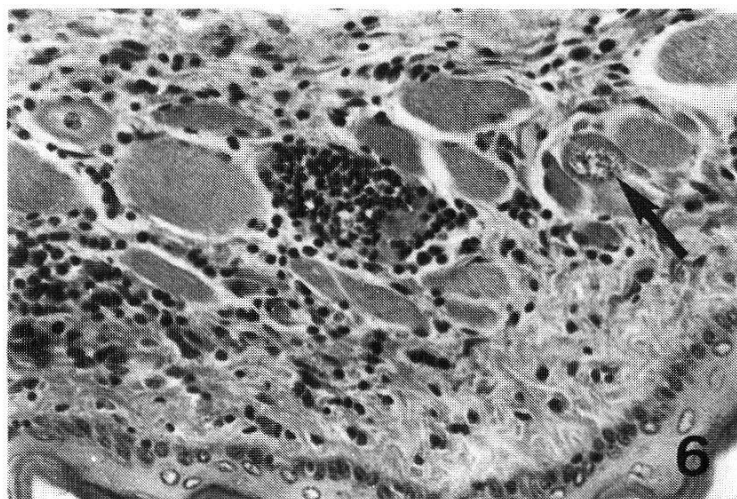
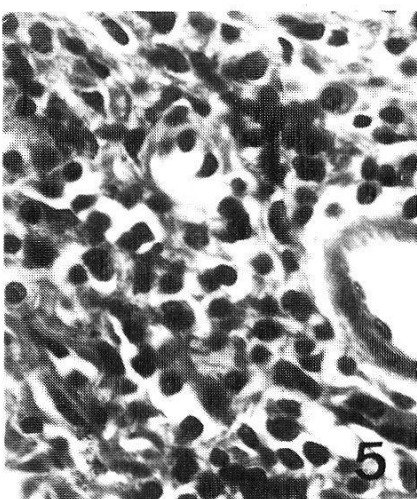
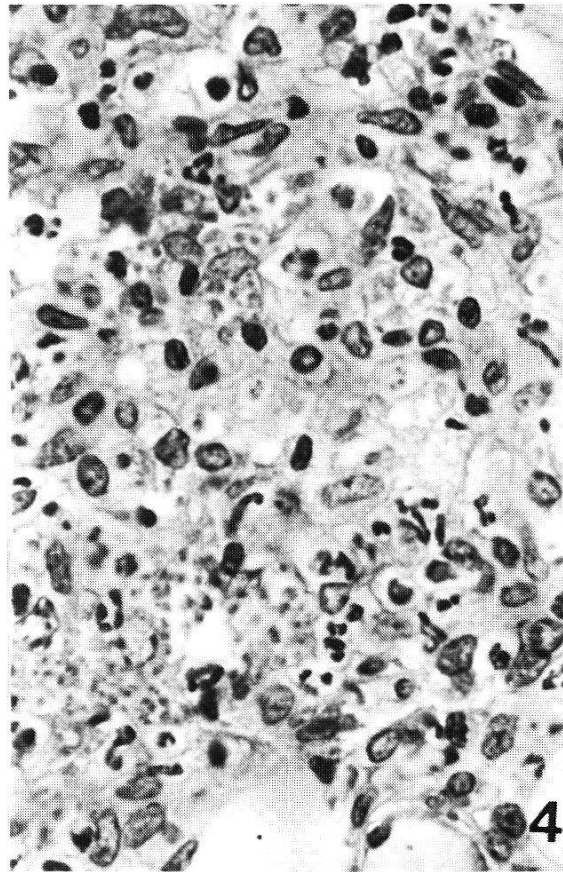
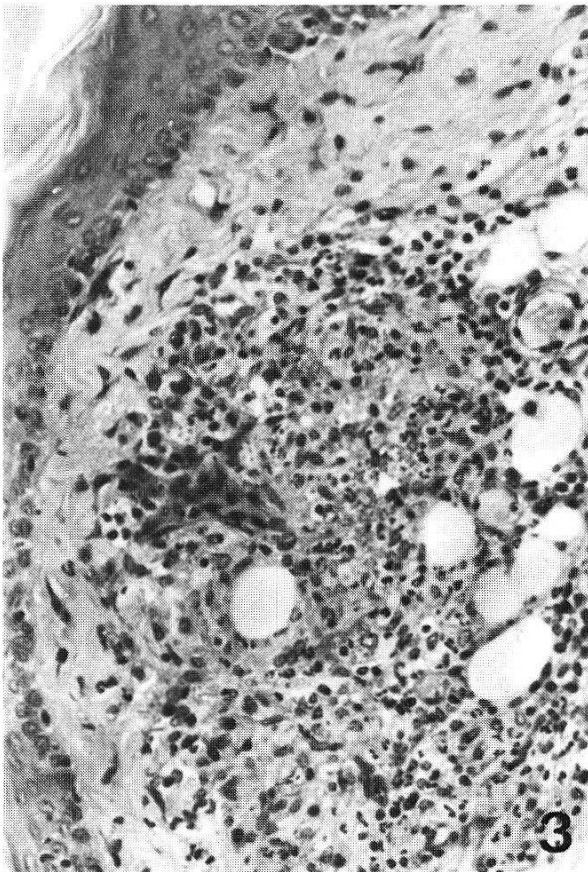
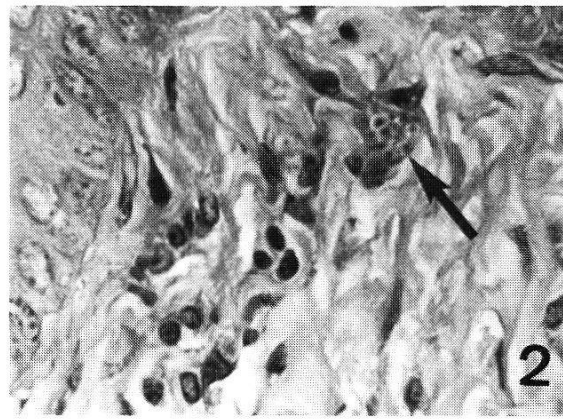
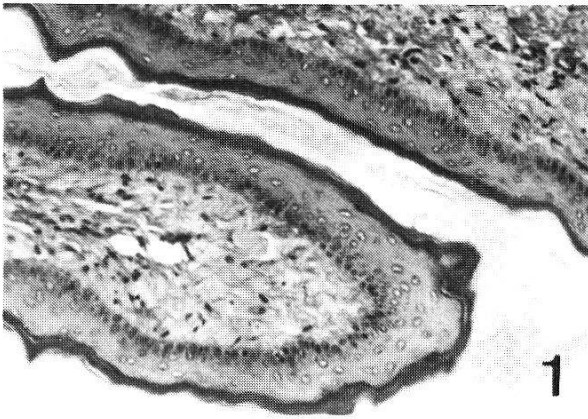
Fig. 1. Normal hamster cheek pouch. Loose connective tissue delimited by a stratified keratinized epithelium. $\times 100$.

Fig. 2. Cheek pouch – 7 days post-inoculation with low dose. Amastigote's nidus (arrow) is already seen. $\times 500$.

Figs. 3 and 4. Cheek pouch – 14 days post-inoculation with low dose. Larger inflammatory reaction with abundant mono- and polymorphonuclear cells and numerous parasites. $\times 200$ and $\times 500$.

Fig. 5. Cheek pouch – 21 days post-inoculation with low dose. Predominance of mononuclear cells. Parasites were not observed. $\times 500$.

Fig. 6. Cheek pouch – 21 days post-inoculation with low dose. Presence of amastigotes (arrow) in muscular region. Focal inflammatory infiltrate probably replacing a previous parasite's nidus. $\times 200$.



fixed for 24 h in Bouin's fixative, embedded in paraffin and stained with hematoxylin and eosin (H.E.).

The same protocol was performed using either low or high doses of parasites and each experiment was repeated two times.

Results

Sequential histology of the tissue reaction

The hamster cheek pouch is limited by a stratified and keratinized epithelium supported by highly vascularized loose connective tissue. Small blood vessels are distributed beneath the epithelium and few fibroblasts, mononuclear and mast cells are observed in between a loose net of collagen fibers (Fig. 1).

When 5×10^3 trypomastigote forms of *T. cruzi* were inoculated into this tissue, a focal inflammatory reaction was observed. As shown in Table 1 this inflammatory cell infiltrate was composed of both mono- and polymorphonuclear leucocytes which persisted throughout the observation period (Fig. 3).

When this small dose of trypomastigotes was inoculated, nidi of parasites were detected at 7 and 14 days post-inoculation. These nidi, more prominent at 14 days post-infection, were sometimes seen clearly within the cytoplasm of cells (Fig. 2) but, less frequently the amastigotes seemed to be free between inflammatory cells and connective tissue fibers (Fig. 4). In 21 days' lesions,

Table 1. Presence of parasites, polymorphonuclear (PMN), and mononuclear (MN) cells at the site of inoculation of *T. cruzi* (low dose)

Day*	Parasites		PMN cells		MN cells	
	pouch	foot	pouch	foot	pouch	foot
3	—	—	+	+	++	++
7	+	—	++	+	++	+++
14	+++	—	+++	+	+++	+++
21	—	—	++	—	+++	+

* Days post-inoculation

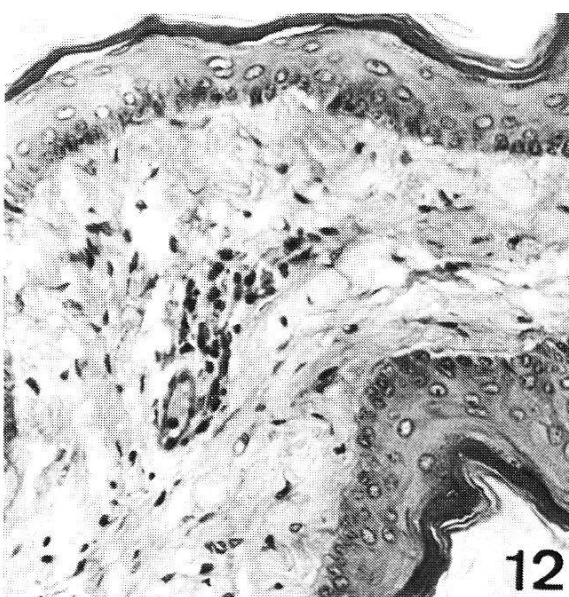
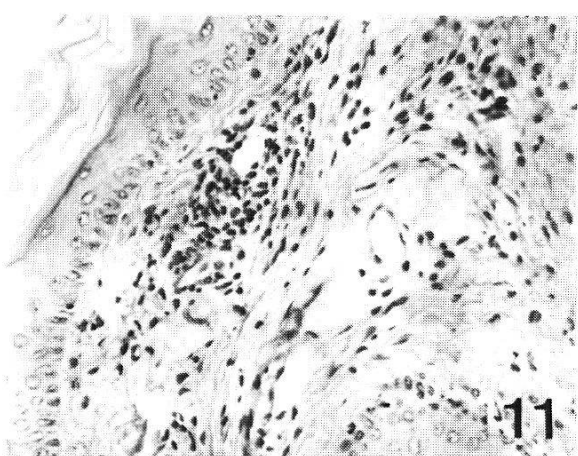
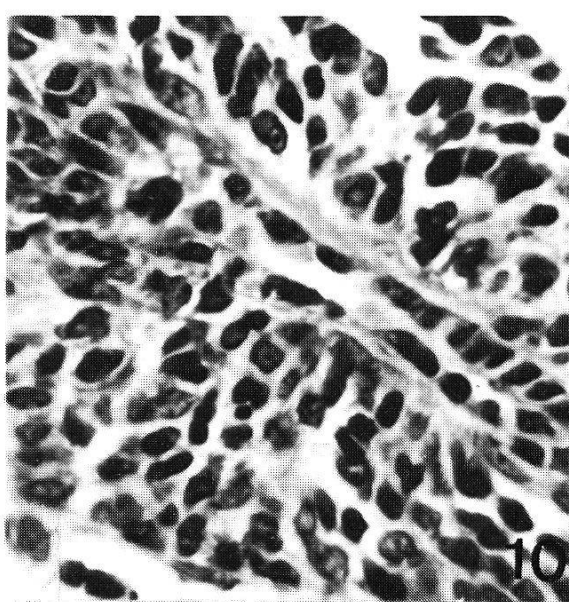
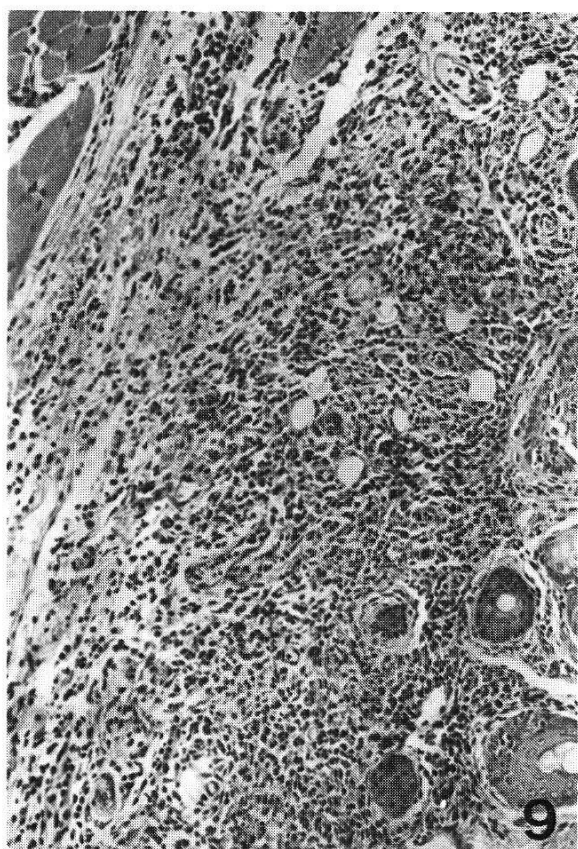
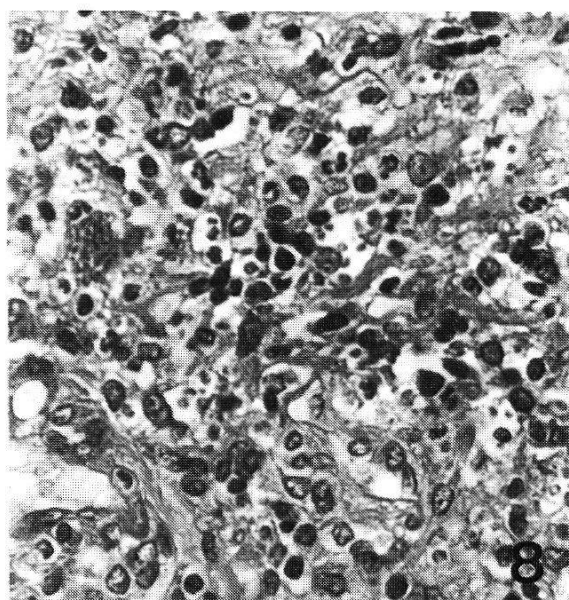
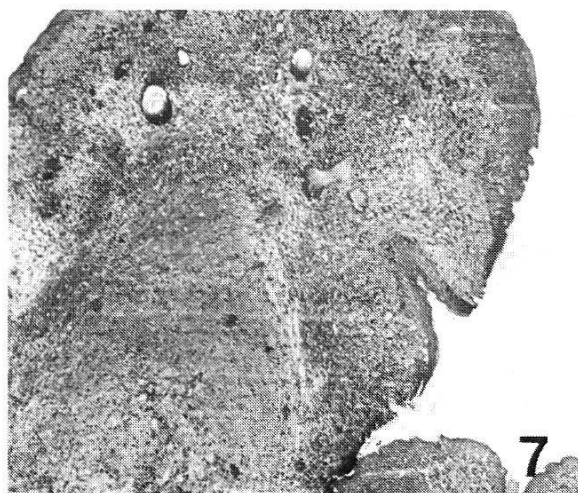— = absent; + = poor; ++ = moderate; +++ = intense

Figs. 7 and 8. Cheek pouch – 7 days post-inoculation with high dose. Prominent inflammatory reaction with higher number of parasites. $\times 25$ and $\times 400$.

Figs. 9 and 10. Footpad – 7 days post-inoculation with low dose. Footpad – 14 days post-inoculation with low dose. Intense and diffuse inflammatory reaction with predominance of mononuclear cells. No parasites can be detected. $\times 100$ and $\times 650$.

Fig. 11. Cheek pouch – 7 days post-inoculation with low dose in previously infected animals. Discrete mono and polymorphonuclear cell infiltrate. $\times 160$.

Fig. 12. Cheek pouch – 14 days post-inoculation with low dose in previously infected animals. Scarce mononuclear cell infiltrate. $\times 650$.



although the inflammatory infiltrate persisted, the nidi of parasites were no longer observed (Fig. 5). Moreover, at this period of infection, i.e. 21 days, nidi of parasites were detected in muscle cells of the pouch (Fig. 6).

When 2×10^5 parasites were inoculated, the same pattern of inflammatory response, although more severe, was observed (Fig. 7) and a greater number of parasites could be found (Fig. 8).

The inoculation of trypomastigotes into the footpad of the animals induced a markedly different pattern of tissue response as compared to the reaction observed in the connective tissue of the pouch (Table 1). The inflammatory reaction as a whole was more intense, leukocytes had a diffuse rather than focal distribution and polymorphonuclear leukocytes were almost absent among an intense mononuclear infiltrate (Fig. 9). This infiltrate showed a marked decrease 21 days post-infection.

Although thoroughly searched, no parasites could be observed in the lesions obtained in the footpads during all the observation periods (Fig. 10).

Visceralization of the parasites

The findings of nidi in vicinal lymph nodes and in the other tissues studied, showed that parasites were able to disseminate from both sites of inoculation: the footpad and the connective tissue of the pouch. Nevertheless, the visceralization of *T. cruzi* was detected in a significant level, 7 days post-inoculation in the footpad and only 14 days after injection of trypomastigotes in the connective tissue of the pouch.

The effect of previous infection on the fate of lesions and parasites in the pouch

As shown in Table 2, when 5×10^3 infective forms of trypomastigotes were inoculated into the connective tissue of the pouch of hamsters which had been previously inoculated with the same dose of parasites 7 days before, the inflammatory reaction elicited by the presence of the protozoa was markedly less

Table 2. Presence of parasites, polymorphonuclear (PMN) and mononuclear (MN) cells in the pouch of hamsters inoculated with a high or a low dose of *T. cruzi* following previous infection in the footpad

Day*	Parasites		PMN cells		MN cells	
	low	high	low	high	low	high
3	—	+	+	+	+	+
7	—	+	+	+	++	+
14	—	—	—	—	++	+
21	—	—	—	—	+	+

* days post-inoculation in the pouch

— = absent; + = poor; ++ = moderate

severe when compared to the reaction in previously uninfected animals. Under these circumstances a discrete, mono- and polymorphonuclear cell infiltrate was observed (Fig. 11) and the lesions almost disappeared 21 days post-reinfection (Fig. 12). However, the striking difference observed in these experiments is related to the absence of parasite nidi which were not detected in the pouch during all the experimental periods (Table 2).

When a high dose of parasites (2×10^5) was used the same evolution of the lesions was observed. Although a small number of parasites could be detected 3 and 7 days post-reinfection none could be found at longer times (Table 2).

Discussion

The inoculation of trypomastigote forms of *T. cruzi* into the footpad or into the cheek pouch of hamsters determined different patterns of lesions. While no parasites could be seen locally following the inoculation of 5×10^3 or 2×10^5 infective forms in the footpad, the same number of parasites injected in the pouch resulted in lesions loaded with parasites within phagocytes up to 14 days post-inoculation. The lesion in the footpad was diffuse and usually composed of a mononuclear cell infiltrate while in the pouch the inflammatory reaction was focal and infiltrated by both mono- and polymorphonuclear leukocytes. Another important difference observed was that the dissemination of the protozoa to other tissues occurred 7 days later for animals inoculated in the pouch, when compared with those inoculated in the footpad. These data clearly demonstrated a retention of the parasite in the pouch indicating that the lymphatic vessel could be the main route of escape of *T. cruzi* from a site of inoculation. Nevertheless, the delayed presence of the parasites in other organs of normal hamster inoculated in the pouch demonstrated that the protozoa was able to reach the general circulation by other mechanisms. The observation of nidi of amastigotes in the musculature of the base of the pouch, a tissue where lymphatic vessels are found, suggested that the parasite could have reached the lymphatic drainage by its spreading through the connective tissue of the pouch. Alternatively, a less efficient mechanism of escape through blood vessels, could be invoked. There are strong evidences that lymph vessels are also the main route of *Leishmania* spreading from a local lesion although afterwards, parasites seem to be arrested and destroyed in lymph nodes (Labotao-Paraense, 1953).

It has been previously demonstrated that *T. cruzi* disappears from the inoculation site soon after injection and the lymphatic system has been ascribed as the route of dissemination of the protozoa (Köberle, 1961). African trypanosomes also appear to reach the systemic circulation via lymphatic vessels following inoculation into the skin (Akol and Murray, 1982).

The importance of this phenomenon to the pathogenesis of the disease remains to be determined although one could speculate that by quick leaving the site of inoculation the parasite escapes not only from the restraining activity

of phagocytic cells as well as from the enhancing of this activity by the cooperation of the immune system. The results obtained when the parasite was inoculated into the pouch of previously infected animals bring some information on the efficiency of the immune system in also restraining parasite spreading. In these experimental circumstances the parasites were no longer observed in the pouch, the lesions were drastically less severe and almost healed 14 days post-inoculation. Although we were not able to determine whether in these conditions the parasite escaped from the site of inoculation, the histological findings are suggestive that the concomitant immunity developed during parasite infection is highly effective in eliminating the protozoa in a reinfection condition. These results might also explain why the parasites are no longer observed in the pouch 21 days after inoculation. The presence of the protozoa in other organs 14 days post-inoculation in the pouch could have stimulated a concomitant immunity responsible for the parasite's elimination in the pocket at 21 days, since the efferent arm of immunity in the pouch is not blocked.

The efficiency of immunity in eliminating *T. cruzi* in an inflammatory focus in the connective tissue obviates the naturally selected properties of the parasite to efficiently escape through lymphatic vessels and protect itself from immune mechanisms within the cytoplasm of specialized cells, such as muscle fibers, to complete its life cycle.

Acknowledgments

This work was supported by CNPq/PIDE IV and V, FINEP, FAPESP and UNDP/World Bank/WHO Special Programme for research and training in Tropical Diseases. Dr. Bijovsky is fellow of FAPESP.

- Akol G. W. P., Murray M.: Early events following challenge of cattle with tsetse infected with *Trypanosoma congolense*. Development of the local skin reaction. Vet. Rec. 110, 295–302 (1982).
- Barker C. F., Billingham R. E.: Immunologically privileged sites. Advanc. Immunol. 25, 1–54 (1977).
- Deutschlander N., Vollerthun R., Hungerer K. D.: Histopathology of experimental Chagas' disease in NMRI mice. A long term study following paw infection. Tropenmed. Parasit. 29, 323–329 (1978).
- Köberle F.: Patología y anatomía patológica de la enfermedad de Chagas. Bol. Ofic. sanit. panamer. 51, 404–428 (1961).
- Lobato-Paraense W.: The spread of *Leishmania enrietti* through the body of the guinea pig. Trans. roy. Soc. trop. Med. Hyg. 47, 556–560 (1953).
- Mariano M., Senhorini I. L.: BCG induced granuloma and delayed hypersensitivity. In: 4th International Congress of Immunology of the International Union of Immunological Societies, Paris, 1980. Abstract n° 13.7.26.
- Rubio M.: Natural and acquired immunity against *Trypanosoma cruzi* in the hamster (*Cricetus auratus*). Biológica 27/8, 95–116 (1959).
- Taliaferro W. H., Pizzi T.: Connective tissue reactions in normal and immunized mice to a reticulo-tropic strain of *Trypanosoma cruzi*. J. infect. Dis. 96, 199–226 (1955).