

**Zeitschrift:** Acta Tropica  
**Herausgeber:** Schweizerisches Tropeninstitut (Basel)  
**Band:** 39 (1982)  
**Heft:** 3

**Artikel:** "Trypanosoma brucei gambiense" : cerebral immunopathology in mice  
**Autor:** Poltera, A.A. / Hochmann, A. / Lambert, P.H.  
**DOI:** <https://doi.org/10.5169/seals-312978>

### **Nutzungsbedingungen**

Die ETH-Bibliothek ist die Anbieterin der digitalisierten Zeitschriften auf E-Periodica. Sie besitzt keine Urheberrechte an den Zeitschriften und ist nicht verantwortlich für deren Inhalte. Die Rechte liegen in der Regel bei den Herausgebern beziehungsweise den externen Rechteinhabern. Das Veröffentlichen von Bildern in Print- und Online-Publikationen sowie auf Social Media-Kanälen oder Webseiten ist nur mit vorheriger Genehmigung der Rechteinhaber erlaubt. [Mehr erfahren](#)

### **Conditions d'utilisation**

L'ETH Library est le fournisseur des revues numérisées. Elle ne détient aucun droit d'auteur sur les revues et n'est pas responsable de leur contenu. En règle générale, les droits sont détenus par les éditeurs ou les détenteurs de droits externes. La reproduction d'images dans des publications imprimées ou en ligne ainsi que sur des canaux de médias sociaux ou des sites web n'est autorisée qu'avec l'accord préalable des détenteurs des droits. [En savoir plus](#)

### **Terms of use**

The ETH Library is the provider of the digitised journals. It does not own any copyrights to the journals and is not responsible for their content. The rights usually lie with the publishers or the external rights holders. Publishing images in print and online publications, as well as on social media channels or websites, is only permitted with the prior consent of the rights holders. [Find out more](#)

**Download PDF:** 05.08.2025

**ETH-Bibliothek Zürich, E-Periodica, <https://www.e-periodica.ch>**

WHO Immunology Research and Training Centre,  
Division of Haematology, Department of Internal Medicine, Hôpital cantonal,  
CH-1211 Geneva 4, Switzerland

## ***Trypanosoma brucei gambiense*: cerebral immunopathology in mice**

A. A. POLTERA, A. HOCHMANN, P. H. LAMBERT

### **Summary**

Ninety outbred white adult female mice were infected with *Trypanosoma brucei gambiense* (GUMS 2, alias LUMP 1237) originating from a Zairian patient and known to produce a low parasitaemia in rodents. The development of cerebral trypanosomiasis was independent upon the number of parasites inoculated per mouse. Trypanosomes appeared in the circulating blood about four months after infection, when some mice started to show the first signs of paresis which subsequently led to cachexia. A clinical test to stage such a development is described. 57 mice were sacrificed at various intervals after infection, starting from one to 22 months. The morphological changes in the brain consisted of a diffuse meningoencephalitis in 45 mice (78.9%) often associated with parasites, the latter being best visualised in 21 mice (36.8%) by immunofluorescence using a specific antitrypanosome antibody. The trypanosomes showed a predominantly extravascular distribution in the cerebral parenchyma, to a lesser extent in the meninges and only rarely in the choroid plexuses. Deposits of immunoglobulins in the choroid plexuses and cerebral infiltrations by plasma cellus were mild. The level of circulating immune complexes was found to be increased. Adequate intravenous Melarsoprol did not prevent the disease from progressing to advanced stages, and there is limited morphological evidence that it did not eradicate the parasite from the host. The immunofluorescent use of an antitrypanosome antibody to demonstrate the persistence of tissue parasites after chemotherapy is recommended. Murine models seem therefore to be suitable for drug screening in cerebral trypanosomiasis since all three trypanosomes of the brucei group can be adapted to mice.

**Key words:** *Trypanosoma b. gambiense*; mice; cerebral immunopathology; extravascular trypanosomes; choroid plexus; Melarsoprol; chemotherapy.

## Introduction

Mice for diagnostic purposes in opposition to rats (Wery et al., 1977) are usually not considered to be good laboratory animals for *Trypanosoma brucei gambiense* (TBG) inoculation. Since mice have been successfully used to study cerebral trypanosomiasis when infected with *Trypanosoma brucei brucei* (TBB) (Poltera et al., 1980) as well as with *Trypanosoma brucei rhodesiense* (TBR) (Fink and Schmidt, 1979) we tried to infect outbred white mice with a slow growing TBG. This strain of TBG producing a low parasitaemia was purposely chosen to induce hopefully a disease resembling sleeping sickness patients who are neurologically sick but where parasites are difficult to demonstrate, a known entity in some areas of human African trypanosomiasis (HAT). The evolution of the disease was therefore expected to be followed by clinical signs and morphological analysis of the central nervous system (CNS) at regular intervals.

## Material and Methods

### *Parasite*

TBG was obtained from Prof. W. R. Lumsden, Department of Medical Protozoology, London School of Hygiene and Tropical Medicine. It originated from a Zairian patient and it has been labelled LUMP 1237. This parasite was then passed twice through irradiated mice (500 rad). The obtained stablitate was kept in liquid nitrogen and labelled GUMS 2. For the three experiments (see below) the parasites were injected intraperitoneally (100, 10,000 and 1,000,000 per mouse, respectively) suspended in phosphate saline buffer with glucose at pH 7.2. Parasitaemia was determined by using the tail blood (5  $\mu$ l) and suspended in a fixative dye (45  $\mu$ l = 1:10) composed of formaldehyde, acetic acid, and carbol fuchsin diluted in distilled water. Parasites were then counted in an improved Neubauer chamber twice a week for the first 3 weeks after infection, subsequently they were spaced to weekly checks for two months, then for every two weeks for two months and then for monthly checks only. Trypanosomes were basically handled according to the methods described by Lumsden et al. (1973).

### *Mice*

Outbred white female mice, type OF1, about 6 weeks old and weighing roughly 25 g, were infected. They had been produced by IFFA CREDO (Centre de Recherche et d'Élevage des Oncins, St-Germain sur l'Arbresle, France). Three groups with 30 mice each were formed (Group A, B, C). A group of seven mice served as control (Group D).

*Groups A and B.* Mice were infected with 100 (A) respectively 1,000,000 (B) trypanosomes per mouse. They were checked for circulating parasites at weekly and later at monthly intervals. Some mice were sacrificed before the appearance of clinical signs in each group.

*Group C.* Each mouse was infected with 10,000 trypanosomes. When signs had appeared and when two mice had died, the whole group was subdivided into 4 subgroups with 7 mice each (subgroup CI, CII, CIII, CIV) out of which one received treatment (Group CII).

*Group D.* Seven uninfected mice of same age and sex were kept for one year and then sacrificed.

### *Drug*

Melarsoprol (Arsobal, Specia, Paris, France) was administered intravenously ( $3 \times 10$  mg/kg with 5 days interval) after dilution in distilled water, followed by immediate use.

### *Staging*

Mice were clinically assessed with two tests (a, b) and staged as follows:

a) *Stage 0*: The mouse was lifted by its tail, and the immediate spreading of hind legs was considered as normal.

*Stage I*: The hind legs remained contracted to the body and this was considered as abnormal.

b) *Stage II*: The mouse was put on a horizontal grill which was then turned by 180 degrees on its horizontal axis; normal: hanging on four feet, abnormal: hanging on front feet only for 15".

*Stage III*: Immediate dropping from the grill when turned by 180 degrees on its horizontal axis.

### *Serum*

Before sacrifice under anaesthesia the animals were bled from the orbital plexus. The non-heated serum was stocked at minus seventy degrees Celsius until use. Circulating immune complexes were determined using a modified radiolabelled C<sub>1q</sub> binding test (Zubler et al., 1976). For the immunodiffusion test (Mancini) of the third component of complement (C<sub>3</sub>) a commercially available antiserum was used (Nordic Laboratories, CH-1000 Lausanne, Switzerland).

### *Antitrypanosomal antibody*

Specific antibodies were raised in rabbits. The antigen was prepared from TBB (GUMS 1) (Poltera et al., 1980). The parasites were multiplied once in irradiated mice, passed on a DEAE column, sonicated and mixed with Freund's incomplete adjuvants. Rabbits were injected twice with this mixture (day 0 and day 21) and were bled on day 35. The obtained antiserum was used for indirect immunofluorescence with Fluorescein- or Rhodamin-labelled goat-antirabbit IgG (Nordic Laboratories, CH-1000 Lausanne, Switzerland). This anti-GUMS 1 antiserum reacted on smears of GUMS 1 and GUMS 2 at a dilution of 1/100.

### *Organs*

After sacrifice the brain was immediately removed and cut sagittally into halves; one was frozen in liquid nitrogen and kept in such until used, the other half was kept in buffered formalin. For histology sections were cut at 4  $\mu$  and stained with Haematoxylin and Eosin. For immunofluorescence commercially available labelled antisera were used and sections were cut in a cryo-stat at 5  $\mu$ . Microscopic analysis was carried out with a Leitz Microscope, but for immunofluorescence and photography a Leitz Photomicroscope (Orthoplan) was used.

### *Autoimmunity*

Selected sera of infected mice were tested on a normal brain section from a mouse using the indirect immunofluorescent technique.

## **Results**

### *Group A – Murine infection with one hundred trypanosomes*

From the original 30 infected mice, 19 were analysed. The other 10 had died during the long observation (eight months) and one had been improperly handled. The following fractions indicate the numbers of mice sacrificed per month after infection: 2/2, 4/5, 4/6, 7/13, 2/22. Clinically 13 of these 19 mice were sick (stages I/II/III = 1/7/5) and 6 appeared normal (stage 0) (Table 1). The earliest time at which stage III was observed, was 4 months after infection. Sick mice were then sacrificed at 6 and 13 months respectively after infection. The 2 mice killed 22 months after infection appeared clinically normal. Parasi-

Table 1. Relation of clinical staging (stages 0–III) to morphologic results in TBG infected mice

Group	Clinical stage				Total
	0	I	II	III	
A	6 3 – 2 – 1	1 0 – 0 – 1	7 4 – 3 – 0	5 3 – 2 – 0	19
B	9 1 – 2 – 6	0 0	4 1 – 3 – 0	3 3 – 0 – 0	16

e.g. Stage 0 Group A 3 – 2 – 1

1st position = 3 brains showed trypanosomes and inflammatory cells

2nd position = 2 brains showed only inflammatory cells

3rd position = 1 brain showed neither parasites nor inflammatory cells

taemia was positive in 8 mice at the 4th months after infection (around  $10^5$  parasites per ml blood) and once in the 9th month.

Table 1 indicates that 17 mice showed cellular infiltrates of the meninges (Fig. 1a) and/or the white matter (Fig. 1b), consisting mainly of mononuclear cells, namely of lymphocytes, macrophages, occasional plasma and rare morular cells and possibly lymphoblasts. The choroid plexuses (= CP) showed some cellular infiltration at the insertion (Fig. 1c), the interstitium of the villi was not grossly altered. Ten mice showed positive staining for trypanosomes in the brain. Their pattern of extravascular cerebral distribution was as follows: 6 times in the meninges and white matter, thrice in the white matter and once in the CP (Fig. 2b), meninges and white matter (Fig. 2a). The staining for total immunoglobulin and IgM showed a perivascular but diffuse presence (Fig. 2c) localised 5 times in the meninges, twice in the meninges and white matter and once in the white matter only. Plasma cells were not a marked feature with this staining method. The deposits of immunoglobulins in the CP were not conspicuous (Fig. 2d). The two remaining brains did not show pathological alterations.

The correlation between clinical staging and morphological results (Table 1) was not good since normal clinical staging was found to be associated with parasites and inflammatory cells in the CNS. Conversely, stage II and stage III mice were found to be negative for cerebral parasites although inflammatory cells were present in the CNS.

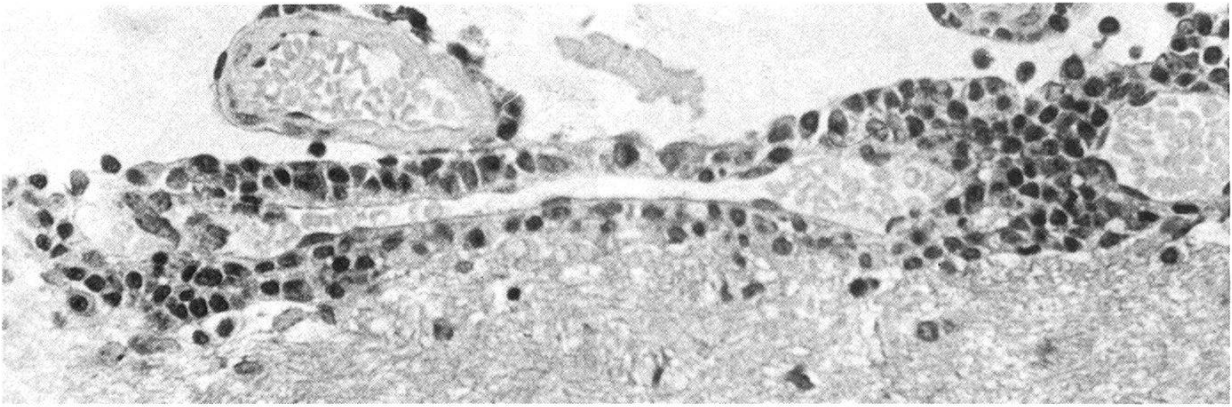
Serologically, the levels of circulating immune complexes were found to be increased (above 6%) in twelve mice representing a mean level of 8.43% (normal value  $2.58\% \pm 0.68$ ).

Fig. 1. Histological aspects of cerebral alterations in the same sick mouse (Group A).

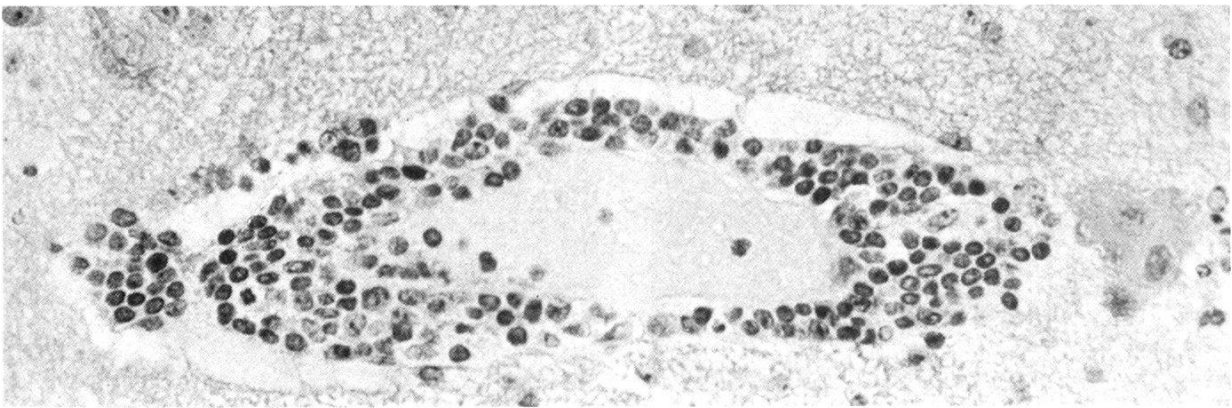
Figs. 1a and b. Perivascular cuffing of the meningeal (a) and cerebral vessels (b). HE,  $\times 80$ .

Fig. 1c. Infiltration of the insertion of the choroid plexus of the fourth ventricle by mononuclear cells. Note slender interstitium of the choroid villi. HE,  $\times 130$ .

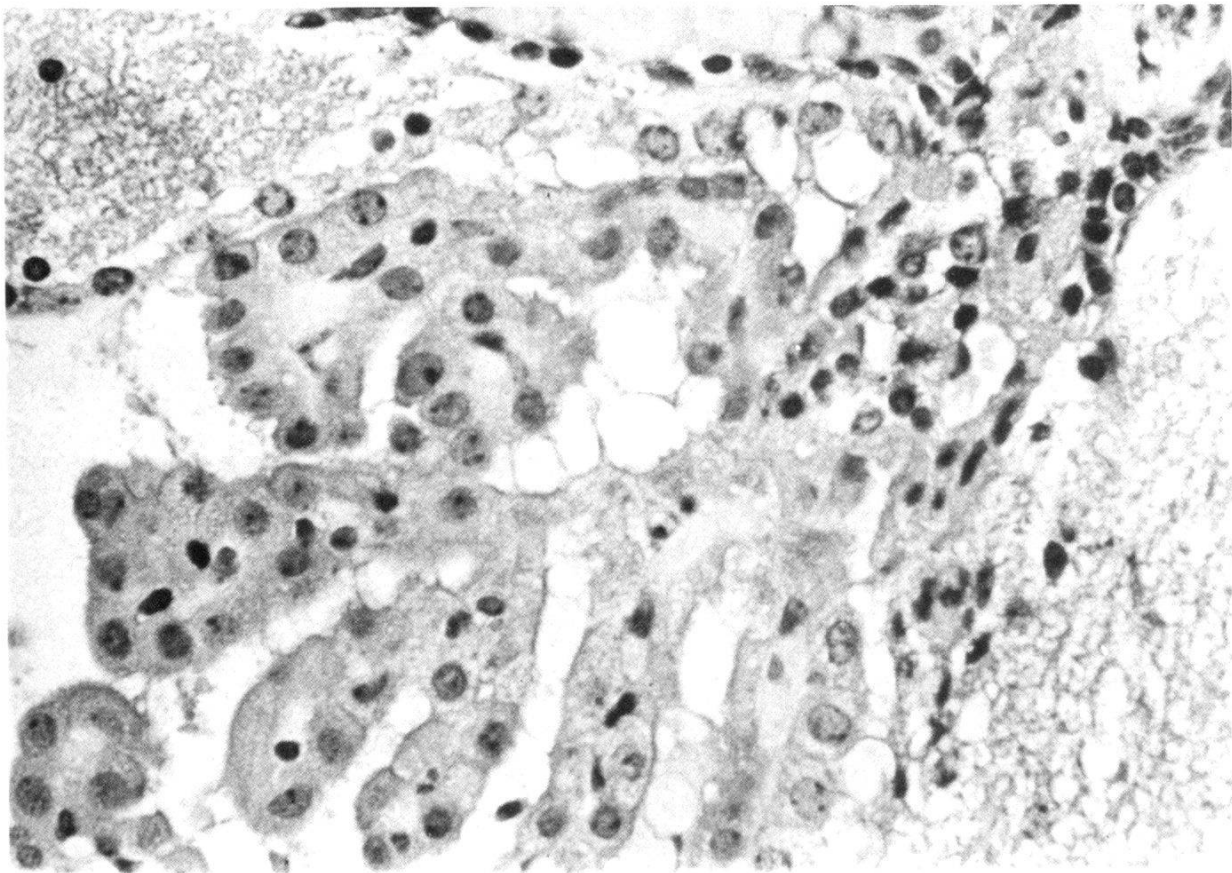




1a

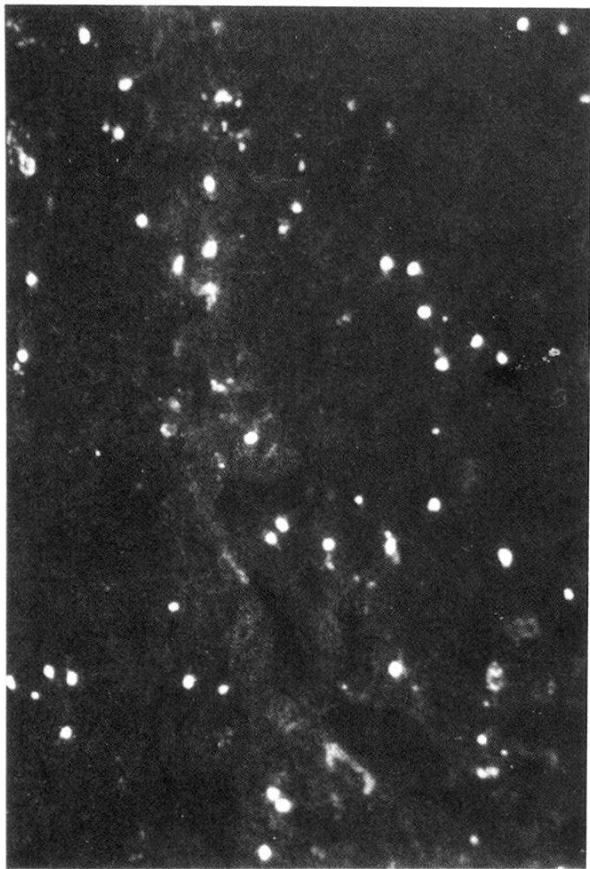

1b

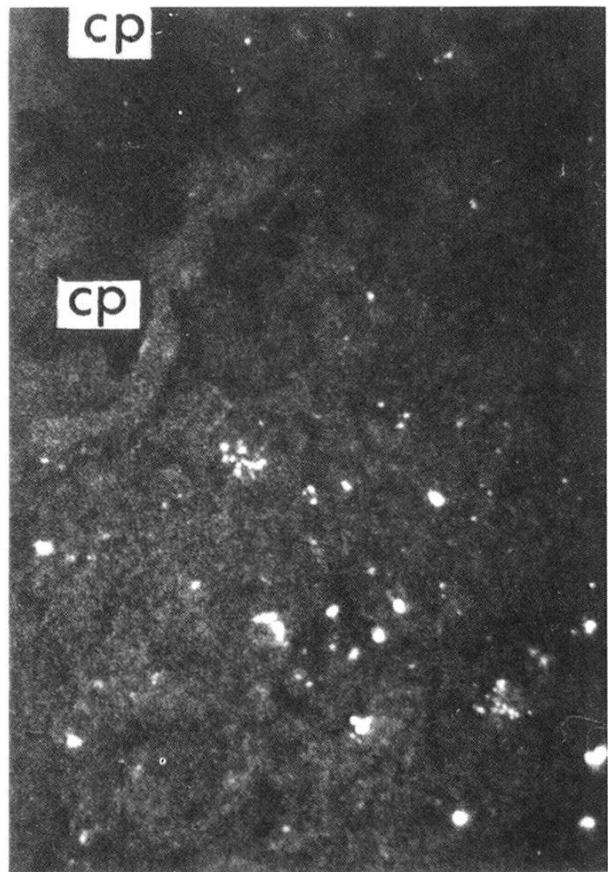


1c

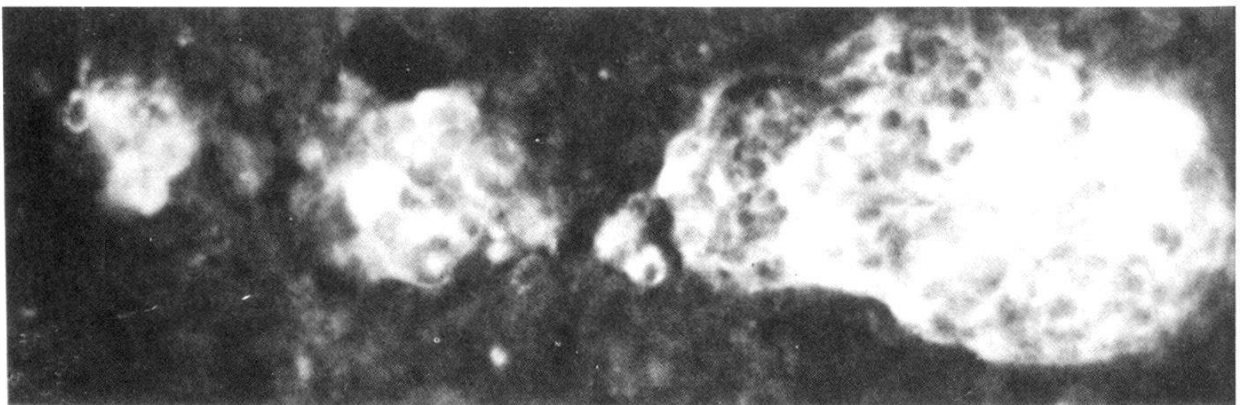
2a



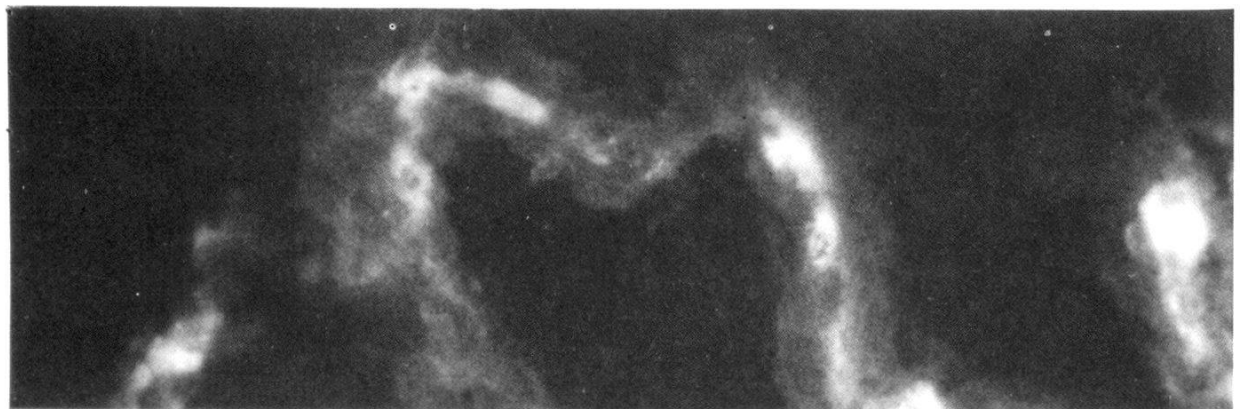2b



2c



2d



### *Group B – Murine infection with one million trypanosomes*

Of these 30 mice, 16 were analysed. Ten had died and 4 had been improperly handled. Clinically 9 appeared normal on the day of sacrifice and 7 were sick (Table 1). The following fractions indicate the numbers of mice sacrificed per month after infection: 1/1, 1/2, 1/4, 3/5, 4/6, 2/13, 4/22. The first sick mice were killed in the 5th month. In the 6th and 13th months only sick mice were sacrificed. Four mice appearing clinically normal reached 22 months. Parasitaemia was found to be positive 18 times in 9 mice during the 4th and 5th month ranging from  $10^5$  to  $10^7$  parasites per ml blood.

Table 1 indicates that trypanosomes were found in 5 brains. They were predominantly found in the cerebral interstitium and less often in the meninges. Once they were localised in the CP. A cellular inflammatory reaction of the meninges was observed in 5 mice. A mononuclear cell infiltration was evident, but plasma cells were not prominent, although some diffuse immunoglobulin staining was present in the perivascular spaces. Granular deposits of immunoglobulins in the CP were mild. In the remaining 6 mice no pathological alterations could be observed (4 from 22nd month, 1 from 1st and 4th month, respectively). The correlation between clinical staging and morphological results was fairly good. The levels for circulating immune complexes were increased (above 6%) in 15 cases with a mean level of 9.70%. Testing of selected sera for cerebral autoantibodies did not provide positive results.

### *Conclusions for Group A and Group B*

The two experiments have demonstrated that white laboratory mice could be infected with a slow growing strain of TBG and that cerebral trypanosomiasis could be induced independent upon the number of parasites at inoculation. 25 mice out of 35 showed inflammatory cell reactions of the CNS. The immunofluorescent technique using an antitrypanosome antibody permitted in 15 of these 35 to detect easily the trypanosomes in the cerebral structures. The diffuse extravascular localisation was a regular finding contrasting with almost total absence of the parasite in the CP. 6 mice did not show brain involvement for as long as 22 months after infection. The levels of circulating immune complexes were increased in 27 cases. Deposits of immunoglobulins and infiltration of the brain by plasma cells were not a very conspicuous finding.

---

Fig. 2. Immunofluorescent aspects in the same sick mouse used for Fig. 1 (Group A).

Figs. 2a and b. Trypanosomes diffusely scattered in the interstitium of the pontine structures (a) but not inside the choroid plexus (CP) of the fourth ventricle (b). Indirect IF for trypanosomal antigens using a Fluorescein-labelled goat-rabbit IgG,  $\times 80$ .

Figs. 2c and d. Perivascular cuffing in the pontine structures showing accumulation of immunoglobulin in these areas only (c). Deposits of total immunoglobulin in the interstitium of a choroid villus of the lateral ventricle (d). Indirect IF for total mouse immunoglobulin,  $\times 130$ .



Table 2. Clinical staging in relation to morphological results in TBG infected mice

Group	Clinical stage				Total
	0	I	II	III	
CI	0	4	2	1	7
	0	0 – 4 – 0	2 – 0 – 0	1 – 0 – 0	
CIIa	0	3	3	1	7
CIIb	0	2	1	1	4
		1 – 1 – 0	0 – 0 – 1	0 – 0 – 1	
CIIIa	0	3	4	0	7
CIIIb	0	3	1	1	5
		1 – 1 – 0	0	0 – 1 – 0	
CIVa	7	0	0	0	7
CIVb	0	4	2	0	6
		0 – 4 – 0	1 – 1 – 0	0	

e.g. CIVa = situation at selection (eight months after infection)

CIVb = situation at thirteen months after infection

e.g. stage II Group CIVb 1 – 1 – 0

1st position = 1 brain showed trypanosomes and inflammatory cells

2nd position = 1 brain showed only inflammatory cells

3rd position = 0 brain, position is for no cells nor parasites

### Group C – Murine infection with ten thousand trypanosomes

When clinical signs were apparent in most of the mice of this group and when two sick mice had died (stages II and III), the remainder were used for selection and subsequent subdivision (8th month after infection). Parasitaemia was seen in 5 mice during the 4th and 5th month after infection. The follow-up in the 3 groups by monthly parasitaemias did not provide positive results. Three of the four groups consisting each of seven mice included animals in different clinical stages (Table 2) and were used as follows:

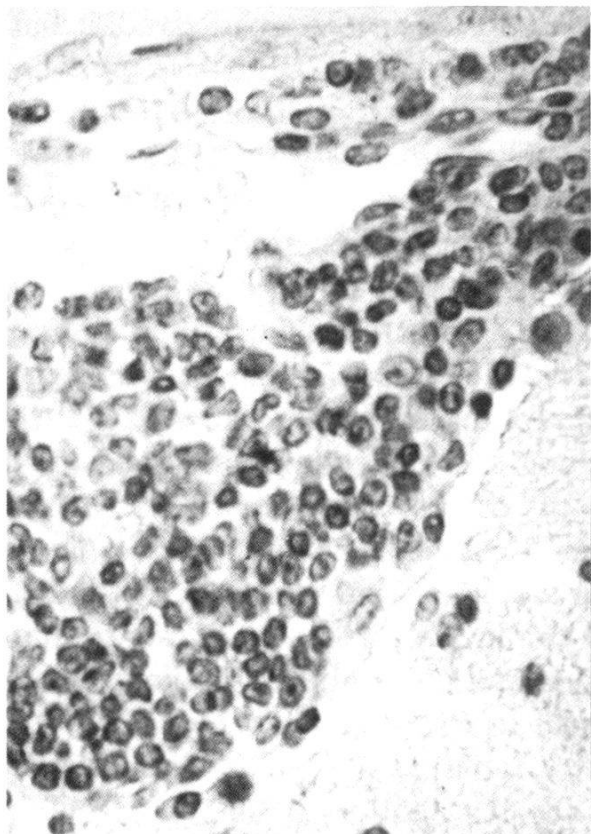
- CI was sacrificed at 8 months,
- CII was treated intravenously at 8 months and killed after 5 months,
- CIII was followed up and killed after 5 months
- CIV clinically normal at 8 months and killed after 5 months.

Fig. 3. Histological and immunofluorescent aspects in a sick mouse where trypanosomes resisted a course of Melarsoprol (Group CII). Control for the specificity of the used antitrypanosomal antibody.

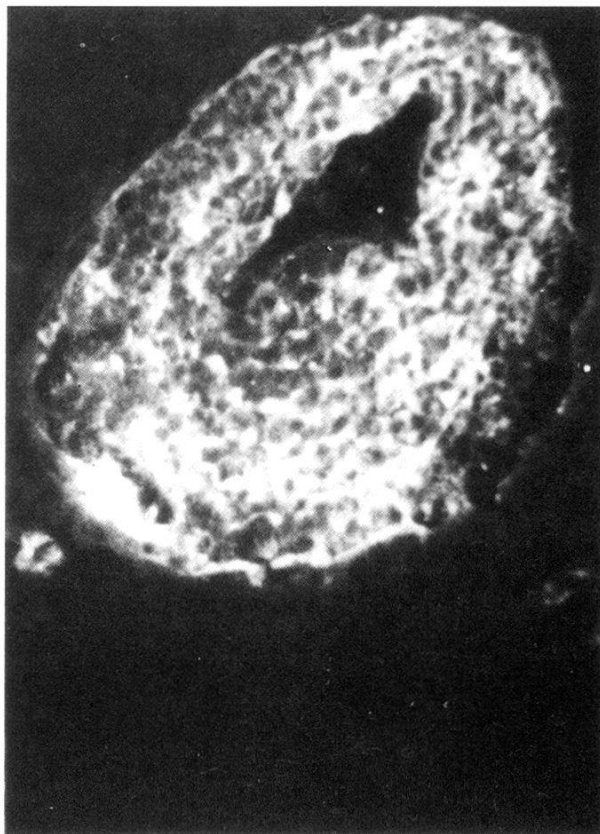Figs. 3a and b. Perivascular infiltration by mononuclear cells of a meningeal (a) and a cerebral vessel (b). HE,  $\times 80$ . Indirect IF for total mouse immunoglobulin,  $\times 80$ .

Fig. 3c. Diffuse interstitial distribution of trypanosomes in the cerebellar structures. Indirect IF for trypanosomal antigens,  $\times 80$ .

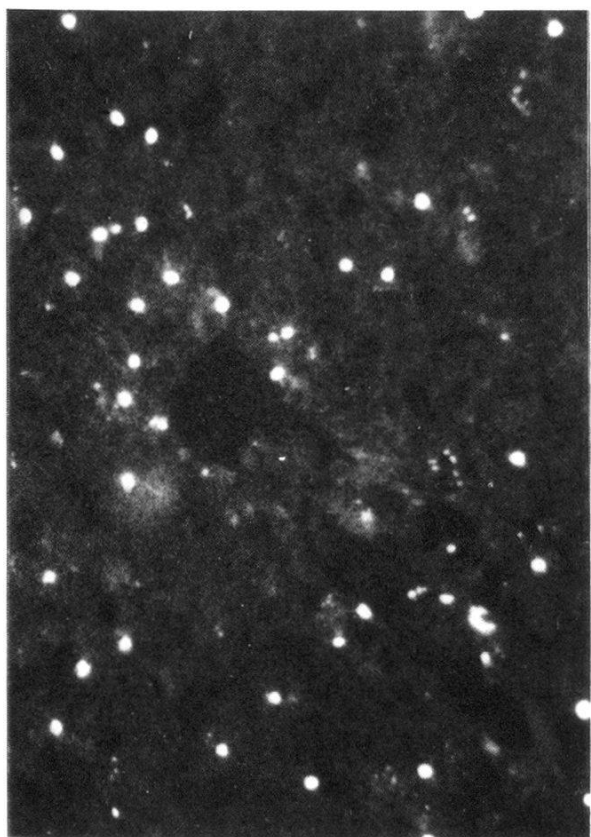
Fig. 3d. *Trypanosoma brucei gambiense* (GUMS 2) exposed to the antitrypanosomal antibody. Indirect IF for trypanosomal antigens using a Rhodamin-labelled goat-antirabbit IgG,  $\times 320$ .



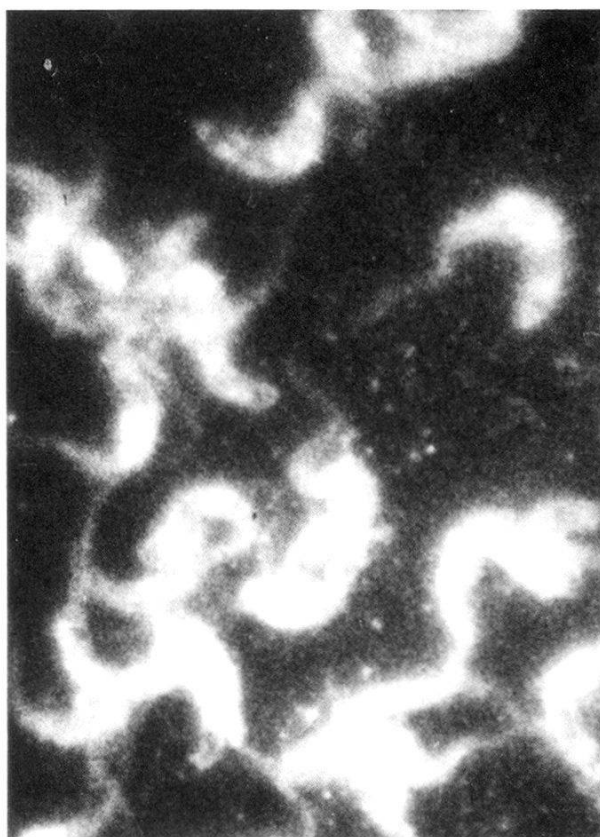
a



3b



c



3d

*Group CI* provided similar results as reported in Groups A and B but circulating immune complexes were within normal levels.

*Group CII* shows that despite of intravenous trypanocidal treatment (Melarsoprol) at a time when the mice were clinically sick three animals died. After an observation period of five months the remainder four mice were killed and one showed persistence of extravascular trypanosomes predominantly in the brain (Fig. 3a), deposits of immunoglobulins (Fig. 3b) as well as marked cellular infiltrates around blood vessels (Fig. 3c) of the white matter and meninges, but rarely of the choroid plexuses. The levels of circulating immune complexes were within normal range except for one case. Although in stage III, one mouse did not show morphological changes in the sections examined.

*Group CIII* and *Group CIV* show clearly the progressive evolution of the disease within five months, in the absence of detectable circulating trypanosomes. During this period three mice had died (2 stage II Group CIII, and 1 stage II Group CIV). The morphological changes were similar to the groups already reported and levels of increased circulating immune complexes were not found.

### *Conclusions for Group C*

This experiment showed the progressive nature of this infection, if followed by clinical testing and morphological analyses which were similar to Groups A and B. Intravenous Melarsoprol did not cure the mice in advanced stage nor did it stop the disease from progression. Circulating immune complexes did not show raised levels.

### *Group D – Control-mice*

Seven mice survived for one year and they were sacrificed in the 13th month. Their morphological and immunopathological analysis revealed no abnormalities. The mean level of the circulating immune complexes was  $2.58\% \pm 1.36$  ( $= 2SD$ ).

*Control for specific antibody.* The antitrypanosomal antibody (Fig. 3d) raised in rabbits from GUMS 1 showed good reactivity with GUMS 2, which had been passed once in irradiated mice. Fluorescein- and Rhodamin-labelled goat-antirabbit IgG reacted well with this antibody showing the parasites in the brain and on smears. Smears of trypanosomes from GUMS 2 and GUMS 1 reacted positively with sera from sleeping sickness patients from Zaire as evidenced by Fluorescein-labelled antihuman IgG, giving further evidence of such a cross-reactivity.

## **Discussion**

French workers had described a «neurotropism» by a strain of *Trypanosoma gambiense* isolated in Yaounde (Cameroon) in laboratory animals such as

mice (Roubaud and Provost, 1941; Stefanopoulo and Etévé, 1943), rats (Stefanopoulo et al., 1943; Roubaud et al., 1944) and a rabbit (Stefanopoulo et al., 1945). These authors had observed a chronic infection in these animals, but interestingly the same parasite behaved in an acute way (septicaemic) if inoculated subcutaneously into a monkey (Stefanopoulo et al., 1945) demonstrating the apparent importance of the host-parasite relationship. Some of these rodents showed paraplegia and sphincter disturbances; the histopathology resembled earlier descriptions of HAT (Mott, 1906) and experimental African trypanosomiasis in monkeys (Peruzzi, 1928). However, the changes in the CP have not been systematically studied, but the diffuse cerebral presence of the trypanosomes was noticed (Roubaud et al., 1944; Stefanopoulo et al., 1945).

In the present study cerebral trypanosomiasis could also be induced by a human pathogenic trypanosome (GUMS 2) in more than one third of the analysed mice. But the parasitaemia was irregular regardless of the used concentration for inoculation and the CNS of the here reported mice was less constantly involved if compared to the TBB-model (Poltera et al., 1980). The diffuse extravascular cerebral distribution in this model, however, contrasts with the predominant interstitial localisation of flagellated trypanosomes in the CP in rodents (Poltera et al., 1980; van Marck et al., 1981a), clarifying therefore earlier claims of an amastigote phase in the CP of rodents infected with African trypanosomes (Ormerod and Venkantesan, 1971; Mattern et al., 1972). In the present model, however, trypanosomes were not observed to localise in big numbers in the CP despite the use of whole-organ sections and despite the sequential killing. Van Marck et al. (1981b) observed that the mouse tended to show a more diffuse cerebral distribution of trypanosomes than the rat. The mechanism which eventually controls such a predominant localisation in the CP or the diffuse interstitial spread within the brain is as yet unknown. Interestingly such a change of intracranial parasite distribution could be reproduced in relapses of TBB-infected mice treated with Melarsoprol (Poltera, 1980; Poltera et al., 1981) and in relapses of TBR- or TBB-infected vervet monkeys after use of trypanocides (Poltera, 1982); such an interstitial cerebral presence of intact trypanosomes has been confirmed by selected electronmicroscopy in these models (Rudin et al., 1982).

Immune complexes have been shown to occur in the CP of TBB- and TBG-infected laboratory animals (Poltera et al., 1980; Rudin and Jenni, personal communication; van Marck et al., 1981a) and they were associated with membranes. Such membrane damage could eventually result in alteration of this barrier which seems to contain the parasites for some time. In the present experiment deposits of immunoglobulins were observed inside the CP but they appeared less prominent than in the model with TBB. They were not apparent in the cerebral interstitium at sites where parasites were seen. Can it mean that the trypanosomes can escape from trypanolytic immune complexes as reported from «in vitro» experiments (Balber et al., 1979)? Circulating immune com-



plexes showed increased levels in HAT (Fruit et al., 1977; Whittle et al., 1980; Lambert et al., 1981) as well as in the present and past murine models (Poltera et al., 1980); their significance in African trypanosomiasis, however, is not yet clearly established. In particular the occurrence of such complexes in the cerebrospinal fluid is controversial (Whittle et al., 1980; Lambert et al., 1981) and they were not found in experimental simian trypanosomiasis with cerebral involvement (Poltera, unpublished data). Experimentally serum levels of circulating immune complexes increased after single dose Melarsoprol in cerebral trypanosomiasis and they returned to normal levels within two weeks (Poltera et al., 1981). Whether an increase in such levels could contribute to the arsenical encephalopathy (Buyst, 1975; Sina et al., 1977) needs further investigation. The deaths in the therapeutic group of this study might be attributable to such a phenomenon. Morphologically no increase of inflammatory cell reactions could be seen in sequential studies after experimental Melarsoprol treatment (Poltera et al., 1981) and this leaves the question open how much sensitised lymphocytes (Askonas et al., 1979) may contribute to adverse drug reactions, although depletion of lymphocytes has been shown to reverse rapidly after trypanocidal treatment (Roelants et al., 1979).

Since various animal models for cerebral trypanosomiasis are now available, further studies should be directed to improve the knowledge of the chemotherapeutic impact on the parasitised brain. The parasite distribution within the brain may be of particular relevance to relapses and resistance to trypanocides and particularly to Melarsoprol as observed in HAT (Buyst, 1975; Antoine, 1977; Kazyumba, 1979).

### Acknowledgments

The authors gratefully acknowledge the collaboration of Prof. W. H. R. Lumsden, Department of Protozoology, London School of Hygiene and Tropical Medicine, for providing LUMP 1237, the Department of Pathology, Radiotherapy and Medical Illustration, Hôpital cantonal, Geneva.

The proof reading by Mrs. S. E. Thomas M.D. and the secretarial assistance of Mr. Paul G. Kimani are greatly appreciated. Mrs. J. Bertrand, WHO, Geneva, was most helpful in providing some references and Mrs. M. Dermond assisted with photographic prints.

Antoine P.: Neurological and psychological studies on sleeping sickness patients and their evolution. *Ann. Soc. belge Méd. trop.* 57, 227–247 (1977).

Askonas B. A., Corsini A. C., Clayton C. E., Ogilvie B. M.: Functional depletion of T- and B-memory cells and other lymphoid cell populations during trypanosomiasis. *Immunology* 36, 313–321 (1979).

Balber A. E., Bangs J. D., Jones S. M., Proia R. L.: Inactivation or elimination of potentially trypanolytic, complement-activating immune complexes by pathogenic trypanosomes. *Infect. Immun.* 24, 617–627 (1979).

Buyst H.: The treatment of *Trypanosoma rhodesiense* sleeping sickness with special reference to its physiopathological and epidemiological basis. *Ann. Soc. belge Méd. trop.* 55, 95–104 (1975).



- Fink E., Schmidt H.: Meningoencephalitis in chronic *Trypanosoma brucei rhodesiense* infection of the white mouse. Tropenmed. Parasit. 30, 206–211 (1979).
- Fruit J., Santoro F., Afchain D., Duvallet G., Capron A.: Les immunocomplexes circulants dans la trypanosomiase Africaine humaine et expérimentale. Ann. Soc. belge Méd. trop. 57, 257–266 (1977).
- Kazyumba G. L.: L'endémie sommeiluse en République du Zaïre au cours des 25 dernières années (1952–76). Méd. Afr. noire 26, 47–52 (1979).
- Lambert P. H., Berney M., Kazyumba G. L.: Immune complexes in serum and in cerebrospinal fluid in sleeping sickness. Correlation with polyclonal B-cell activation and with intracerebral immunoglobulin synthesis. J. clin. Invest. 67, 77–85 (1981).
- Lumsden W. H. R., Herbet W. J., McNeillage G. J. C.: Techniques with trypanosomes. Churchill/Livingstone, Edinburgh 1973.
- Mattern P., Mayer G., Felici M.: Existence de formes amastigotes de *Trypanosoma gambiense* dans le tissu plexuel choroïdien de la souris infectée expérimentalement. C. R. Acad. Sci. Paris 274, 1513–1515 (1972).
- Mott F. W.: Histological observations on sleeping sickness and other trypanosome infections. Reports of Sleeping Sickness Commission No. VII, 5–46 (1906).
- Ormerod W. E., Venkantesan S.: An amastigote phase of the sleeping sickness trypanosome. Trans. roy. Soc. trop. Med. Hyg. 65, 736–741 (1971).
- Peruzzi M.: Final report of the league of nations on human trypanosomiasis. Section 5, 245–324 (1928).
- Poltera A. A.: Immunopathological and chemotherapeutic studies in experimental trypanosomiasis with special reference to the heart and brain. Trans. roy. Soc. trop. Med. Hyg. 74, 706–715 (1980).
- Poltera A. A.: Chemotherapy, relapses and CNS in experimental African trypanosomiasis. Contr. Microbiol. Immunol. 7 (in press) (1982).
- Poltera A. A., Hochman A., Lambert P. H.: *Trypanosoma brucei brucei*: the response to Melarsoprol in mice with cerebral trypanosomiasis. An immunopathological study. Clin. exp. Immunol. 46, 363–374 (1981).
- Poltera A. A., Hochman A., Rudin W., Lambert P. H.: *Trypanosoma brucei brucei*: a model for cerebral trypanosomiasis in mice. An immunological, histological and electronmicroscopic study. Clin. exp. Immunol. 40, 496–507 (1980).
- Poltera A. A., Sayer P. D., Muya B. K., Brighthouse G.: Circulating immune complexes during trypanocidal treatment with or without immunosuppressive drugs in mice and monkeys. A paper read at the 17th meeting of the International Scientific Council for Trypanosomiasis Research and Control, Arusha, October 1981 (in press) (1982).
- Roelants G. E., Pearson T. W., Morrison W. I., Mayor-Withey K. S., Lundin L. B.: Immune depression in trypanosome infected mice. IV. Kinetics of suppression and alleviation by the trypanocidal drug Berenil. Clin. exp. Immunol. 37, 457–469 (1979).
- Roubaud E., Provost A.: Manifestations neurotropes d'une souche de *Trypanosoma gambiense* chez la souris. Bull. Soc. Path. exot. 34, 48–50 (1941).
- Rouboud E., Stefanopoulo G. J., Duvalon S.: Etude chez le rat d'une souche neurotrophe de *Trypanosoma gambiense*. Bull. Soc. Path. exot. 37, 292–296 (1944).
- Rudin W., Poltera A. A., Jenni L.: An electronmicroscopic study of cerebral trypanosomiasis in rodents and primates. Contr. Microbiol. Immunol. 7 (in press) (1982).
- Sina G., Triolo N., Trova P., Clabaud J. M.: L'encéphalopathie arsénicale lors du traitement de la trypanosomiase humaine africaine à *Trypanosoma gambiense* (à propos de 16 cas). Ann. Soc. belge Méd. trop. 57, 57–74 (1977).
- Stefanopoulo G., Etévé J.: Méningo-encéphalo-myélite de la souris blanche due à une souche «neurotrophe» de *Trypanosoma gambiense*. Bull. Soc. Path. exot. 36, 43–46 (1943).
- Stefanopoulo G., Caubet P., Duvalon S.: Présence de cellules muriformes de MOTT chez les rats infectés de *Trypanosoma gambiense*. Bull. Soc. Path. exot. 37, 296–302 (1943).

- Stefanopoulo G., Caubet P., Duvalon S.: Méningoencéphalite à *Trypanosoma gambiense* (souche neurotrope) observée chez le lapin. Bull. Soc. Path. exot. 38, 271–275 (1945).
- van Marck E. A. E., Le Ray D., Beckers A., Jacob W., Wery M., Gigase P. L. J.: Light and electron microscope studies on extravascular *Trypanosoma brucei gambiense* in the brain of chronically infected rodents. Ann. Soc. belge Méd. trop. 61, 57–78 (1981a).
- van Marck E. A. E., Gigase P. L. J., Berckers A., Wery M.: Experimental infections of laboratory rodents with recently isolated stocks of *Trypanosoma brucei gambiense*. 2. Histopathological investigations. Z. Parasitenk. 64, 187–193 (1981b).
- Wery W., Weyne J., Ngimbi Nkuku Mpela, Colaert J.: Isolement de souches de *Trypanosoma gambiense* au Zaïre et leur adaptation aux animaux de laboratoire. Ann. Soc. belge Méd. trop. 57, 452–437 (1977).
- Whittle H., Greenwood B. M., Mohammed I.: Immune complexes in Gambian sleeping sickness. Trans. roy. Soc. trop. Med. Hyg. 74, 833–834 (1980).
- Zubler R. H., Lange G., Lambert P. H., Miescher P. A.: Detection of immune complexes in unheated serum by a modified 125 I-Clq binding test. Effect of heating on the binding of Clq by immune complexes and application of the test to systemic lupus erythematosus. J. Immunol. 116, 232–235 (1976).