

**Zeitschrift:** Acta Tropica  
**Herausgeber:** Schweizerisches Tropeninstitut (Basel)  
**Band:** 30 (1973)  
**Heft:** 4

**Artikel:** Ophthalmomyiasis due to "Oestrus ovis"  
**Autor:** Mareti, Zvonimir / Nadeni, Lucija / Ladavic, Josip  
**DOI:** <https://doi.org/10.5169/seals-311887>

### **Nutzungsbedingungen**

Die ETH-Bibliothek ist die Anbieterin der digitalisierten Zeitschriften auf E-Periodica. Sie besitzt keine Urheberrechte an den Zeitschriften und ist nicht verantwortlich für deren Inhalte. Die Rechte liegen in der Regel bei den Herausgebern beziehungsweise den externen Rechteinhabern. Das Veröffentlichen von Bildern in Print- und Online-Publikationen sowie auf Social Media-Kanälen oder Webseiten ist nur mit vorheriger Genehmigung der Rechteinhaber erlaubt. [Mehr erfahren](#)

### **Conditions d'utilisation**

L'ETH Library est le fournisseur des revues numérisées. Elle ne détient aucun droit d'auteur sur les revues et n'est pas responsable de leur contenu. En règle générale, les droits sont détenus par les éditeurs ou les détenteurs de droits externes. La reproduction d'images dans des publications imprimées ou en ligne ainsi que sur des canaux de médias sociaux ou des sites web n'est autorisée qu'avec l'accord préalable des détenteurs des droits. [En savoir plus](#)

### **Terms of use**

The ETH Library is the provider of the digitised journals. It does not own any copyrights to the journals and is not responsible for their content. The rights usually lie with the publishers or the external rights holders. Publishing images in print and online publications, as well as on social media channels or websites, is only permitted with the prior consent of the rights holders. [Find out more](#)

**Download PDF:** 20.08.2025

**ETH-Bibliothek Zürich, E-Periodica, <https://www.e-periodica.ch>**

# Ophthalmomyiasis due to *Oestrus ovis* \*

ZVONIMIR MARETIĆ, LUCIJA NADENIĆ, JOSIP LADAVIC and RAGIB ZEKIĆ  
Pula, Yugoslavia

Various Diptera are able to provoke an ophthalmomyiasis which due to findings of larvae may involve conjunctivae of eyelids or of the eyeball (Ophthalmomyiasis externa), or the eye itself which is called Ophthalmomyiasis interna. According to some authors within the external ophthalmomyiasis are considered also localisations of larvae on eyelids and lacrimal sac (6). The external ophthalmomyiasis is mostly provoked by flies from families Tachinidae, Sarcophagidae, Calliphoridae, Phoridae and Noestridae, while the internal ophthalmomyiasis is mostly due to *Hypoderma bovis* from the family Oestridae (6).

Our parasite, the sheep nasal bot fly, *Oestrus ovis* (suborder and family Oestridae, subfamily Oestrinae), provokes mainly the external and rarely the internal ophthalmomyiasis (14).

*Oestrus ovis* is extended through the whole Mediterranean area, including Yugoslavia (7), Italy (9–13, 15) and northern Africa, as Alger, in Asian parts of U.S.S.R., it was found in Switzerland, India, Southern Africa and in Hawaii and in North America (1, 4, 17).

The female uses to fly into the nostrils, eventually in the eye, of the sheep or the goat and deposits her freshly hatched larvae of circ. 1 mm bodylength. Due to air stream the larvae climb passively through the nose cavities, where they undergo the second larval stage. They then penetrate actively into the frontal sinuses of the animal, where they achieve their maturity. From there the sheep throws them off as adult larvae through the nostrils on the ground of the grassland, where they develop into pupae (1, 17). The duration of development can vary very much according to many still not entirely explained physiological conditions and can last from 25 days till one year. In the host a superficial inflammation develops when the larvae undergo their three stages of development. Under certain conditions the female can use also man as host depositing its larvae in its eye. The patient feels the act of depositing larvae like the fly did "struck him into the eye" and immediately after it he complains of the feeling of a foreign body or even feels that something is moving in the eye. Some hours later develops painful inflammatory reaction with periorbital oedema. While depositing of larvae the fly may damage the cornea with its legs and wings (5). In man only larvae of first stage are found as a rule, but if they penetrate into the frontonasal sinuses the larvae may develop till the second or perhaps the third stage (9). The illness is benign, and even if the larvae are not removed, the recovery issues within 20 days.

In Yugoslavia, ophthalmomyiasis due to *Oestrus ovis*, or as the author calls it, Ophthalmooestriasis externa or Conjunctivitis parasitaria has been described by NIKOLIĆ (1952) in 6 patients from south-western Hercegovina (7).

## Our patients

On June 24th, 1971 the physician of a children summer resort in Rovinj did send us J. L., a girl, aged 10, and an other girl O. G., aged 11. They complained of pain and itching in the eye, and he saw mince whitish worms in the conjunctival

---

\* Dedicated to Prof. Dr. R. Geigy for his 70th birthday.

sac. By inspection of the external parts of the eye one finds that both palpebras of both eyes were slightly swollen with conjunctival irritation and marked lacrimation. In the fornices of both eyes one sees several movable whitish larvae, which were removed by the aid of a gauze on holder. Ac. boricum 3% was instilled and Ung. Chlorocorten was put. The further course of the disease was favourable.

Enlarged photographs taken from the mince worms removed showed segmented larvae with oral hooks and a crown of spines in the first segment. The photographs were send for determination to Dr. F. Zumpt (South African Institute for Medical Research) who did determine it as first larval stage of *Oestrus ovis* – which we acknowledge with gratefulness.

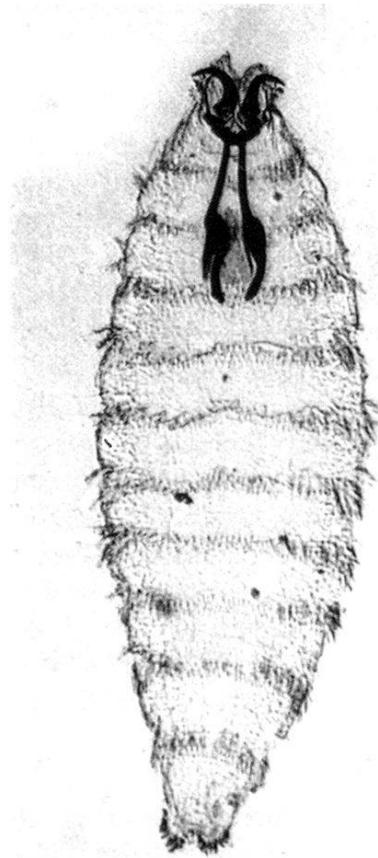


Fig. 1. *Oestrus ovis*, first larval stage.

### Discussion

Publications on myiasis in general in our country are not frequent (2, 3, 6, 7, 8, 16), and on ophthalmomyiasis one can tell that not even in world's literature too many papers were published, since as late as 1957 it was considered that they are not more than something more than a hundred (6). But that would not mean that these cases would represent a rarity, but more that not enough attention was paid to them. Differential-diagnostically it can be easily changed for blepharoconjunctivitis (7, 11, 15). Of this opinion is also NIKOLIĆ basing on his experiences in Hercegovina, and this was especially confirmed by PAMPIGLIONE (11–13). He did on base of his comprehensively undertaken research in Italy established that 85,6% of interviewed shepherds did have had this disease once or several times every year (12, 15) and from an inquiry of 5,000 physicians he




Fig. 2. *Oestrus ovis*, adult.

obtained data for 414 cases (11). *Oestrus ovis* is the most common cause of ophthalmomyiasis in man.

Both mentioned authors (7, 11) consider the ophthalmooestriasis to be an occupational disease of shepherds. The sheep or the goat are the obligatory hosts, and man only occasionally. There is also an other explanation for the oestriasis in man. When the number of sheep decreases rapidly, the fly attacks man due to the impossibility to find the natural host (7, 17). But our patients had nothing to do with sheep, neither sheep was found in the vicinity.

In man there can occur also other, though more rare forms of infestation, as nasal, oral, pharyngeal, tonsillar, laryngeal, sinusal, auricular or mixed, and complications also (10, 11). RAKUSIN described a case of deep intraocular penetration where panuveitis developed, so that the larvae had to be operatively removed from the anterior ocular chamber. Consequence of this was an atrophy of the Nervus opticus with a comprehensive destruction of retina and periretinal fibrosis (14).

### Conclusion

It is certain that ophthalmooestriasis is more frequent than it is recognized. Though it is considered as an occupational disease of shepherds, it must be kept in mind, that it occurs also in cases where patients did have no direct contact with sheep.

### References

1. BRUMPT, E. (1949). Précis de parasitologie. Vol. 2, p. 1393. – Paris: Masson & Cie.
2. CAPAR, M., SIŠUL, N., MORO-TOPIC, E. & ZEKIĆ, R. (1972). Polyserositis e myiasi. – Liječn. vjesn. 94, 189.
3. ČUPAK, K. (1964). Slučaj Ophthalmomyiasis externa. – Arh. zašt. majke i djeteta 8, 25.
4. DU TOIT, R. & MEYER, H. (1960). A case in South Africa of ocular myiasis in man due to first-stage larvae of the nasal bot fly of the sheep (*Oestrus ovis* L.). – S. Afr. med. J. 34, 581.

5. HOFFMANN, B. L. & GOLDSCHMID, J. M. (1970). Ophthalmomyiasis caused by *Oestrus ovis* L. (Diptera: Oestridae) in Rhodesia. – S. Afr. med. J. 44, 644.
6. JURKO, S. (1957). Ophthalmomyiasis interna anterior. – Med. Arh. 11, 57.
7. NIKOLIĆ, N. (1952). Ophthalmooestriasis externa (Conjunctivitis parasitaria), profesionalna bolest ovčara. – Arh. Hig. Rada 3, 315.
8. OBERITER, V., VUKOVIĆ, V., KRŠNJAVI, B. (1966). Myiasis bei einem Kinde und das Vorkommen der Myiasis in Jugoslawien. – Z. Tropenmed. Parasit. 17, 361.
9. PAMPIGLIONE, S. (1957). Sulla miasi dei seni frontali da "*Oestrus ovis*" nell'uomo. – Riv. Ig. San. publ. 13, 731.
10. PAMPIGLIONE, S. (1958). Le miasi da "*Oestrus ovis*" nell'uomo in Italia, malattia dei pastori. – Riv. Att. med. 23, 1.
11. PAMPIGLIONE, S. (1958). Indagine epidemiologica sulla miasi congiuntivale umana da *Oestrus ovis* in Italia. I. – Pensiero sci. 9, 242.
12. PAMPIGLIONE, S. (1958). Indagine epidemiologica sulla miasi umana da *Oestrus ovis* in Italia. II. – Pensiero sci. 9, 1.
13. PAMPIGLIONE, S. (1965). Note su *Oestrus ovis* L. (Diptera, Oestridae) e descrizione di alcuni casi di miasi nell'uomo. – Ann. Ist. Sup. San. 1, 73.
14. RAKUSIN, W. (1970). Ocular myiasis interna caused by the sheep nasal bot fly (*Oestrus ovis* L.). – S. Afr. med. J. 44, 1155.
15. SACCÀ, G., GABRIELLI, L. & STELLA, E. (1965). Note su *Oestrus ovis* L. (Diptera, Oestridae) e descrizione di alcuni casi di miasi nell'uomo. – Ann. Inst. Sup. San. 73, 94.
16. VUKOVIĆ, V., OBERITER, V. & KRŠNJAVI, B. (1966). Humana mijaza u našoj zemlji (s prikazom jednog slučaja hipodermoze). – Zdrav. nov. 19, 32.
17. ZUMPT, F. (1963). Ophthalmomyiasis in man, with special reference to the situation in Southern Africa. – S. Afr. med. J. 37, 425.