

Zeitschrift: Acta Tropica
Herausgeber: Schweizerisches Tropeninstitut (Basel)
Band: 30 (1973)
Heft: 4

Artikel: Detection of "Trypanosoma theileri" in Ethiopian cattle ticks
Autor: Burgdorfer, W. / Schmidt, M.L. / Hoogstraal, H.
DOI: <https://doi.org/10.5169/seals-311883>

Nutzungsbedingungen

Die ETH-Bibliothek ist die Anbieterin der digitalisierten Zeitschriften auf E-Periodica. Sie besitzt keine Urheberrechte an den Zeitschriften und ist nicht verantwortlich für deren Inhalte. Die Rechte liegen in der Regel bei den Herausgebern beziehungsweise den externen Rechteinhabern. Das Veröffentlichen von Bildern in Print- und Online-Publikationen sowie auf Social Media-Kanälen oder Webseiten ist nur mit vorheriger Genehmigung der Rechteinhaber erlaubt. [Mehr erfahren](#)

Conditions d'utilisation

L'ETH Library est le fournisseur des revues numérisées. Elle ne détient aucun droit d'auteur sur les revues et n'est pas responsable de leur contenu. En règle générale, les droits sont détenus par les éditeurs ou les détenteurs de droits externes. La reproduction d'images dans des publications imprimées ou en ligne ainsi que sur des canaux de médias sociaux ou des sites web n'est autorisée qu'avec l'accord préalable des détenteurs des droits. [En savoir plus](#)

Terms of use

The ETH Library is the provider of the digitised journals. It does not own any copyrights to the journals and is not responsible for their content. The rights usually lie with the publishers or the external rights holders. Publishing images in print and online publications, as well as on social media channels or websites, is only permitted with the prior consent of the rights holders. [Find out more](#)

Download PDF: 14.01.2026

ETH-Bibliothek Zürich, E-Periodica, <https://www.e-periodica.ch>

Detection of *Trypanosoma theileri* in Ethiopian Cattle Ticks

W. BURGDORFER¹, M. L. SCHMIDT² and H. HOOGSTRAAL³

Introduction

To investigate the hypothesis that ticks and cattle play a role in an extra-human cycle of the epidemic typhus agent, *Rickettsia prowazeki*, ticks taken off cattle in various provinces of Ethiopia were examined for this rickettsia. During this work, several *Rhipicephalus pulchellus* and one *Boophilus decoloratus* were found infected with a trypanosome. Identification of this organism as *Trypanosoma theileri* and its distribution in these ticks are the subjects of this communication.

Materials and Methods

Adult *R. pulchellus* were taken off cattle (Boran breed) near Neghele, Sidamo Province, in May of 1971. *Boophilus decoloratus* were removed in Addis Ababa from Arussi Mountain cattle that originated from the Gelemso area in Harar Province.

Immediately after collection, the ticks were placed in plastic tubes with moistened plaster of Paris, and shipped to the Rocky Mountain Laboratory for examination for rickettsial agents. For this purpose, hemolymph obtained from each tick by amputating the distal portion of one or more legs was smeared on a microscope slide (BURGDORFER, 1970). After heat fixation, the smears were stained by GIMÉNEZ' (1964) method and examined by conventional microscopy. From all the trypanosome-infected ticks, additional hemolymph was taken and stained with Giemsa. Some of these ticks were then dissected for preparation and examination of Giemsa-stained tissue smears. Remaining tissues from each of these ticks were triturated in 0.85 % solution of NaCl, and 0.25 ml of the suspensions were injected intraperitoneally into each of two adult Swiss mice, meadow voles (*Microtus pennsylvanicus*), and domestic rabbits. To determine susceptibility of these animals to the trypanosome, Giemsa-stained thick blood drops, prepared daily, were examined microscopically.

To determine possible occurrence of transovarial passage of trypanosomes to the progeny of infected ticks, five female *R. pulchellus* were placed together with

¹ U.S. Department of Health, Education, and Welfare, Public Health Service, National Institutes of Health, National Institute of Allergy and Infectious Diseases, Rocky Mountain Laboratory, Hamilton, Montana 59840, USA.

² U.S. Naval Medical Research Unit No. 3, Field Facility c/o American Embassy, Addis Ababa, Ethiopia.

³ U.S. Naval Medical Research Unit No. 3, USIS, c/o Spanish Embassy, Cairo, Arab Republic of Egypt. From Work Units MR041.09.01-0037A6HJ and MF12.524.009-0029BF6I, Bureau of Medicine and Surgery, Department of the Navy, Washington, D.C. The opinions and assertions contained herein are the private ones of the authors and are not to be construed as official or as reflecting the views of the Department of the Navy or of the naval service at large.

normal males on guinea pigs for feeding and mating. Replete females were held for oviposition in glass vials at room temperature and 78% relative humidity. Smears of eggs and of resulting larvae, nymphs and adults were stained with Giemsa and examined microscopically for trypanosomes.

Results

(a) Microscopic Examination of Hemolymph and Tissues of Infected Ticks

Of 258 *R. pulchellus*, 19 (7.4%), five males and fourteen females, and one (1.4%) of 69 *B. decoloratus* females were positive for trypanosomes by the hemolymph test. In both tick species, morphologic characteristics of the trypomastigote stage of this flagellate agreed with those described for *Trypanosoma theileri*: length varying from about 50 to 120 μ , long pointed posterior end, cytoplasm granular and often heavily vacuolized, nucleus about centrally located, medium-sized circular to oval kinetoplast far from posterior end, prominent undulating membrane, and free flagellum (Fig. 1).

Body fluid of most infected ticks contained enormous masses of long, slender epimastigotes which were often arranged in typical rosettes (Fig. 2) consisting of numerous individual or dividing organisms. Also present were transition forms between epimastigote and trypomastigote stages (Fig. 3). Typical trypomastigotes were not numerous; amastigotes, sphaeromastigotes and promastigotes were rarely detected in the hemolymph. However, in two *R. pulchellus*, the leishmanialike amastigotes (Fig. 4) and sphaeromastigotes (Figs. 5 and 6) were abundant and appeared associated with plasmatocytes, although their intracellular position could not always be determined with certainty.

All tick organs were infected to varying degrees, with ovary exhibiting the most massive invasion. Here, all developmental stages of *T. theileri* could be detected. Intracellular leishmanialike forms appeared localized in epithelial cells (Fig. 7), whereas epimastigotes and trypomastigotes, the latter less abundant, occurred throughout the various ovarian tissues. Some areas had enormous accumulations of heavily vacuolized trypanosomes in development from epi- to trypomastigote stages (Fig. 8); the kinetoplast of these organisms was usually lateral to the nucleus.

Salivary gland tissues generally were moderately infected with transition forms varying from sphaero- to trypomastigotes. The latter were somewhat shorter than trypanosomes in ovary or hemolymph, and possibly represent metacyclic trypanosomes.

Moderate invasion by trypanosomes was noted also in connective tissues and in the epithelium of Malpighian tubules. The majority of organisms seen here were sphaero- and epimastigotes. These developmental stages were predominant also in muscle tissues.

(b) Microscopic Examination of Eggs and Progeny of Infected Ticks

Although numerous smears of ovarian tissues from nine flat or partially engorged *R. pulchellus* and from the single *B. decoloratus* were examined, trypanosomes in oocytes could not be established with certainty. Unfortunately, only two of the five replete *R. pulchellus* oviposited. Despite massive development of *T. theileri* in ovarian tissues of these females, none of 50 freshly deposited eggs and none of 50 eggs in which larval appendages were detectable harbored trypo-

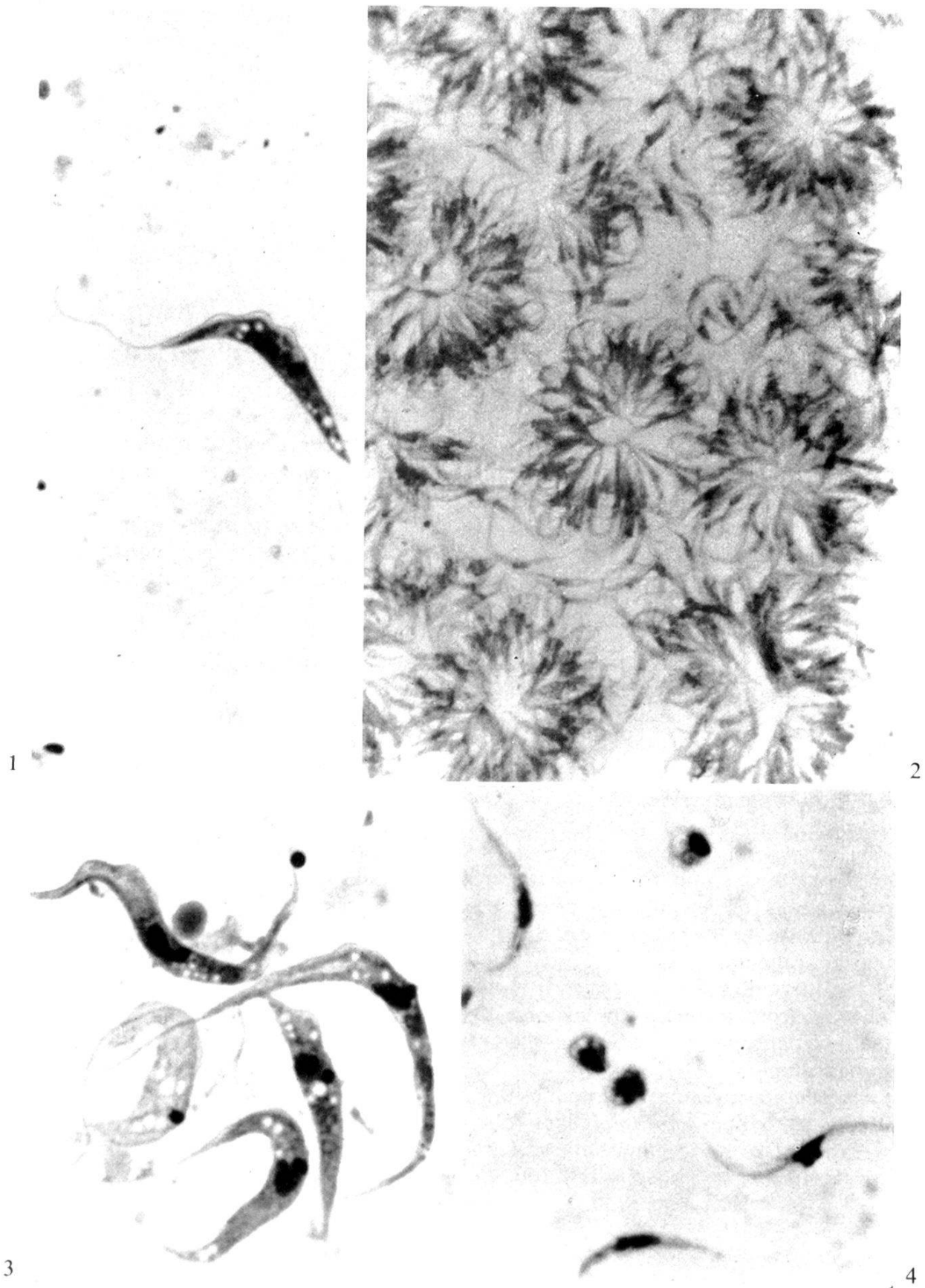

Fig. 1. Trypomastigote form of *T. theileri* in hemolymph of *R. pulchellus* (Giemsa stain, $\times 1,680$).

Fig. 2. Rosettelike accumulations of epimastigotes of *T. theileri* in *R. pulchellus* hemolymph (Giemsa stain, $\times 840$).

mastigotes or any other developmental stages of *T. theileri*. Similarly negative were smears from each of 25 freshly hatched larvae, 25 starved larvae, 25 nymphs and 25 adults from each of these parental females.

(c) *Susceptibility of Laboratory Animals to T. theileri*

Swiss mice, meadow voles and domestic rabbits did not develop parasitemias or clinical manifestations during a 14-day observation period after injection of heavily infected tick tissues.

Discussion

Trypanosoma theileri is a cosmopolitan parasite of cattle, and has been described from every continent where cattle are raised. It is generally assumed that it is transmitted by certain blood-sucking arthropods, particularly tabanid flies. Ingested with a blood meal, it undergoes cyclical development in the insect's gut. The infective stages are then excreted during subsequent feedings and pass through the bite wound or skin abrasions.

O'FARRELL (1913) described a crithidialike flagellate in hemolymph and tissues of the cattle tick, *Hyalomma aegyptium*⁴. Not aware of its identity with *T. theileri*, he considered it to be a parasitic tick flagellate, nonpathogenic for vertebrate hosts, and called it *Crithidia hyalommae*. O'FARRELL noted the propensity of this organism to invade ovarian tissues and claimed its passage via eggs to the ticks' progeny. Although WENYON (1926) suggested that *C. hyalommae* might represent a developmental form of *T. theileri*, it was not until 1932 that CARPANO, who observed this organism in a single *Hyalomma* and in infected cattle, established identity of O'FARRELL's *C. hyalommae* with *T. theileri*. He postulated that the *Hyalomma*, in addition to other hematophagous arthropods, may be the vector capable of transmitting this organism by bite as well as via infective fecal material. More recently, ARIFDZHANOV & NIKITINA (1961) detected the same organism in 25 of 110 adult *Hyalomma a. anatolicum* collected from cattle barn in Tashkent. Referring to the trypanosomes as *Crithidia hyalomma* (O'FARRELL, 1913) these authors gave a detailed description of the various developmental stages in the tissues of this tick.

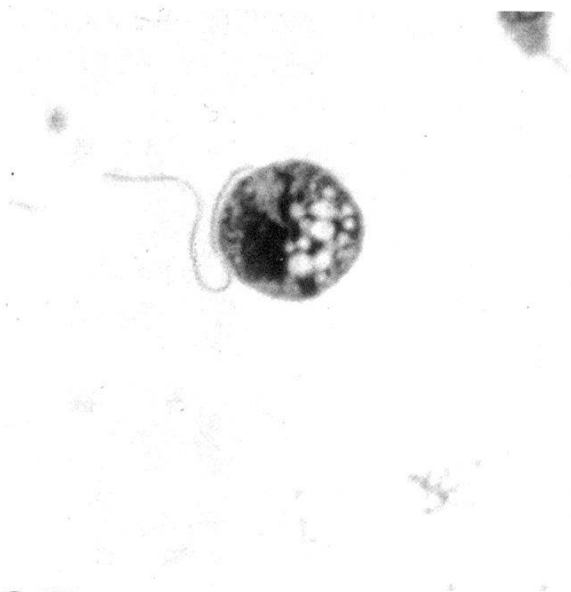The hypothesis that ticks may be vectors of *T. theileri* has not found wide acceptance and is rarely mentioned in today's textbooks. HOARE (1972) does not consider *Hyalomma* as a vector of *T. theileri* because, so far, the infective trypomastigotes (metatrypanosomes) have not been described in these ticks.

In the present study, which was limited to microscopic examination of Giemsa-stained tissue smears of 19 naturally infected *R. pulchellus* and of a single *B. decoloratus*, all developmental stages of *T. theileri* were detected. Presence of trypomastigotes in salivary glands, in particular, suggests that these ticks may be

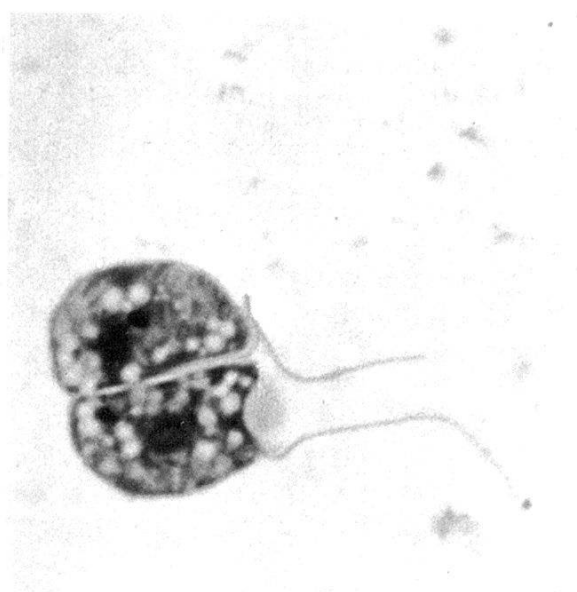
⁴ In O'FARRELL's time, all *Hyalomma* of the Sudan were lumped under the name *H. aegyptium*, which today is recognized as the tortoise *Hyalomma* not occurring in the Sudan.

Fig. 3. *T. theileri* in transition from epismastigote to trypomastigote stages in *B. decoloratus* hemolymph (Giemsa stain, $\times 1,680$).

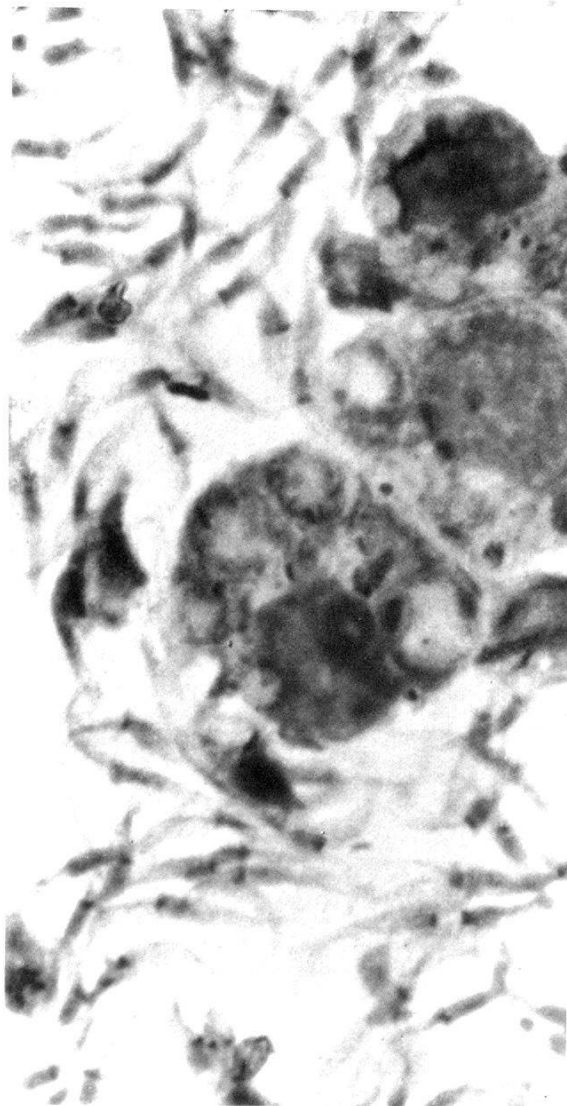
Fig. 4. Amastigotes of *T. theileri* in hemolymph of a *R. pulchellus* which also has a coccidial infection (Giemsa stain, $\times 1,680$).



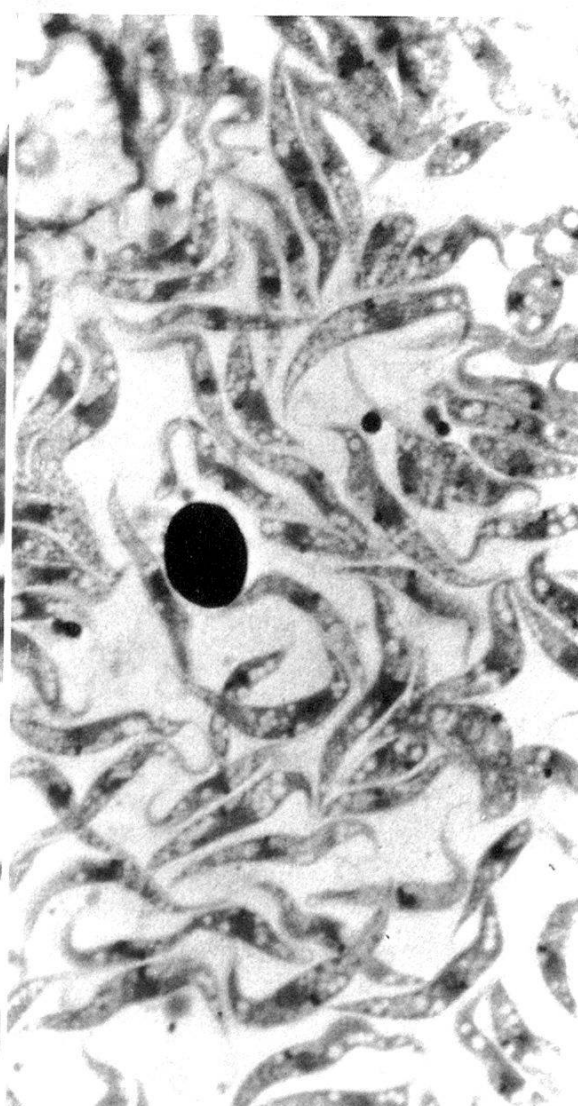
5



6



7



8

Fig. 5. Sphaeromastigote of *T. theileri* in smear of salivary gland tissue of *R. pulchellus* (Giemsa stain, $\times 1,680$).

Fig. 6. Dividing sphaeromastigote of *T. theileri* in smear of salivary gland tissue of *R. pulchellus* (Giemsa stain, $\times 1,680$).

capable of transmitting by bite and may indeed be involved in perpetuating this organism among cattle in Ethiopia.

The remarkable propensity of *T. theileri* to massively grow in ovarian tissues is in agreement with O'Farrell's observations, although we were unable to detect organisms in oocytes, and there was no evidence of trypanosomal infections in progeny of two infected *R. pulchellus*.

Our observations are too limited to formulate a scheme regarding development of *T. theileri* in ticks. A dynamic study with detailed histologic examination is necessary to establish the tissues involved in the cyclical development of this organism. Also, it remains to be clarified whether infected ticks are capable of transmitting *T. theileri* by bite.

The Zebra tick, *R. pulchellus*, is a three-host tick that attacks domestic and a large variety of wild mammals. Because larvae and nymphs feed on the same hosts as adults, this tick could be a significant means by which *T. theileri* is perpetuated among cattle. The blue tick, *B. decoloratus*, on the other hand, is a one-host tick. As such it is of no significance as a vector of *T. theileri* unless the trypanosomes pass via eggs to the progeny of infected females.

Although considered a member of the nonpathogenic trypanosomes, *T. theileri*, either alone or in association with protozoan, bacterial and viral agents has been suggested as the cause of disease or debility in cattle (reviewed by HERBERT, 1964, and LUMSDEN & WELLS, 1968). There is no information on the incidence of this trypanosome in Ethiopian cattle, and, as far as we know, no overt disease has ever been associated with *T. theileri* in that country.

References

- ARIFDZHANOV, K. A. & NIKITINA, R. E. (1961). Detection of *Crithidia hyalomma* (O'Farrell 1913) in *Hyalomma a. anatolicum* (Koch 1844) ticks. – (In Russian.) Zool. Zhur. 40, 20–24. (In English: NAMRU-3-T617.)
- BURGDORFER, W. (1970). Hemolymph test – a technique for detection of rickettsiae in ticks. – Amer. J. trop. Med. Hyg. 19, 1010–1014.
- CARPANO, M. (1932). Localisations du *Trypanosoma theileri* dans les organes internes des bovins. Son cycle évolutif. – Ann. Parasit. hum. comp. 10, 305–322.
- GIMÉNEZ, D. F. (1964). Staining rickettsiae in yolk-sac cultures. – Stain Technol. 39, 135–140.
- HERBERT, I. V. (1964). *Trypanosoma theileri*, Laveran, 1902. – Vet. Bull. 34, 563–570.
- HOARE, C. A. (1972). The trypanosomes of mammals. – Oxford and Edinburgh: Blackwell Scientific Publications.
- LUMSDEN, W. H. R. & WELLS, E. A. (1968). Trypanosomiasis. In: WEINMAN, D. & RISTIC, M. (ed.). Infectious Blood Diseases of Man and Animals. Vol. 2. – New York, London: Academic Press.
- O'FARRELL, W. R. (1913). Hereditary infection, with special reference to its occurrence in *Hyalomma aegyptium* infected with *Crithidia hyalommae*. – Ann. trop. Med. Parasit. 7, 545–556.
- WENYON, C. M. (1926). Protozoology. – London: Baillière, Tindall & Cox.

Fig. 7. Leishmanialike inclusions of *T. theileri* in ovarian epithelial cells of *R. pulchellus* (Giemsa stain, $\times 1,680$).

Fig. 8. Smear of ovarian tissue with *T. theileri* in transition from epimastigote to trypomastigote forms (Giemsa stain, $\times 843$).

Summary

Trypanosoma theileri was detected in 19 of 258 adult *Rhipicephalus pulchellus* and in 1 of 69 *Boophilus decoloratus* taken off cattle in Ethiopia. All developmental stages of this trypanosome were found in Giemsa-stained smears prepared from hemolymph and various organs of these ticks. The ticks' body fluid appeared to provide optimal conditions for massive growth and multiplication of epimastigotes, whereas all tissues, but particularly those of the ovary, were heavily infected with organisms ranging from amastigote to trypomastigote stages. Presence of trypomastigotes in salivary gland tissues of both *R. pulchellus* and *B. decoloratus* suggests that these ticks may be capable of transmitting this organism by bite. Despite massive invasion of ovarian tissues, there was no evidence of trans-ovarial passage of *T. theileri* to the progeny of two infected *R. pulchellus*.

Swiss mice, meadow voles (*Microtus pennsylvanicus*) and domestic rabbits were not susceptible to this trypanosome.