

**Zeitschrift:** Acta Tropica  
**Herausgeber:** Schweizerisches Tropeninstitut (Basel)  
**Band:** 29 (1972)  
**Heft:** 3

**Artikel:** Sparganosis in the Masailand  
**Autor:** Schmid, H. / Watschinger, H.  
**DOI:** <https://doi.org/10.5169/seals-311800>

### **Nutzungsbedingungen**

Die ETH-Bibliothek ist die Anbieterin der digitalisierten Zeitschriften auf E-Periodica. Sie besitzt keine Urheberrechte an den Zeitschriften und ist nicht verantwortlich für deren Inhalte. Die Rechte liegen in der Regel bei den Herausgebern beziehungsweise den externen Rechteinhabern. Das Veröffentlichen von Bildern in Print- und Online-Publikationen sowie auf Social Media-Kanälen oder Webseiten ist nur mit vorheriger Genehmigung der Rechteinhaber erlaubt. [Mehr erfahren](#)

### **Conditions d'utilisation**

L'ETH Library est le fournisseur des revues numérisées. Elle ne détient aucun droit d'auteur sur les revues et n'est pas responsable de leur contenu. En règle générale, les droits sont détenus par les éditeurs ou les détenteurs de droits externes. La reproduction d'images dans des publications imprimées ou en ligne ainsi que sur des canaux de médias sociaux ou des sites web n'est autorisée qu'avec l'accord préalable des détenteurs des droits. [En savoir plus](#)

### **Terms of use**

The ETH Library is the provider of the digitised journals. It does not own any copyrights to the journals and is not responsible for their content. The rights usually lie with the publishers or the external rights holders. Publishing images in print and online publications, as well as on social media channels or websites, is only permitted with the prior consent of the rights holders. [Find out more](#)

**Download PDF:** 20.08.2025

**ETH-Bibliothek Zürich, E-Periodica, <https://www.e-periodica.ch>**

# Sparganosis in the Masailand

H. SCHMID \* and H. WATSCHINGER \*\*

## Introduction

Sparganosis is the general term for infections due to the plerocercoid larval stage (sparganum = plerocercoid) of cestodes of the family Diphyllbothriocephalidae. In most cases classification of the larvae cannot be done. It would need to rear the adult strobila in a definitive animal host. The plerocercoid larvae thus morphologically indistinguishable have therefore received the artificial generic term "spargana" coined by DIESING 1845 (after LAPAGE 1968). Man is a common definitive host of the fish tapeworm (*Diphyllbothrium latum*) in temperate and arctic climates. In Africa parasitic infestations by this species is not known. There are, however, numerous reports of other species of the family Diphyllbothriocephalidae in different wild and domesticated carnivores (BAER 1959, BAYLIS 1937, HUDSON 1933, BUCK et al. 1959). A wide range of animals acts as natural intermediate hosts of the plerocercoid larvae and man may do so incidentally.

In this paper we are reporting special aspects of sparganosis in the Masailand with a detailed description of three cases which have been seen and treated at Wasso Hospital close to Serengeti National Park in the middle of the Masailand, a limited area with a high density of wild life and scattered nomadic human communities.

## Case reports

### *Case 1*

The subject was a male Masai (Nashoi, 32 years) from Sakala. The presenting illness started 8 months before admission with itching and gradually increasing pain and swelling of the left lateral retromalleolar region. When the tumorous mass had reached the size of a hen's egg it was further elongated backwards bending around the heel and extending to the medial retromalleolar region. There it grew to the same size and shape as laterally being again distinctly oval in shape. The patient described wriggling sensations which were probably due to movements of the parasite during the time of expansion from one side to the other. Up to this stage of development the movement of the ankle joint was not very much hampered. Two months before admission the swelling became increasingly tense and painful forcing the patient to limp. This finally led him to seek treatment on the 15th of September 1970 at Wasso Hospital.

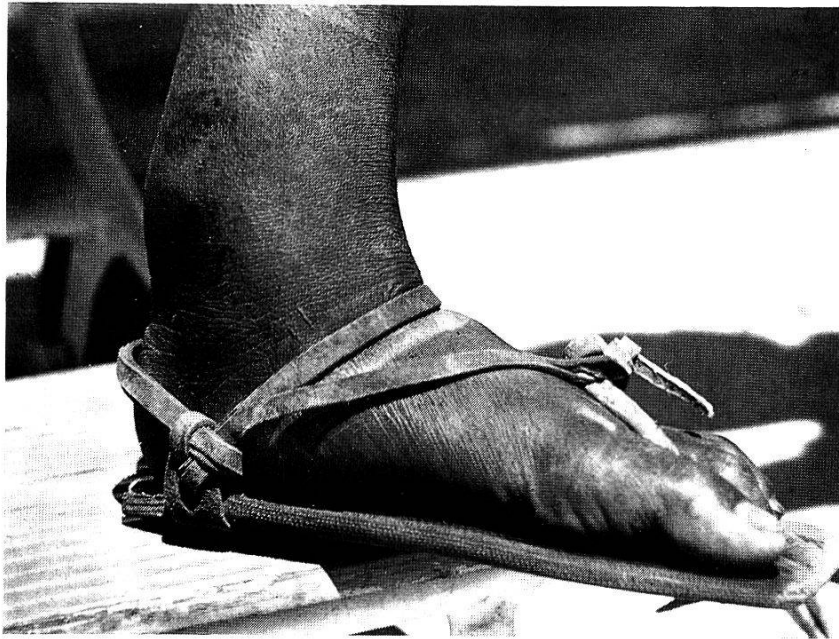### *Physical examination*

(Fig. 1.) The patient presented with two oval tumorous masses involving both retromalleolar regions (lateral aspect 6 × 3 cm, medial aspect 5 × 3 cm). They were bound to each other by a cord-like swelling of about 2 cm thickness overlying the tendon of Achilles; the whole tumorous mass thus encased the heel. The swelling was oedematous, reddened, fluctuating and painful to touch. Besides the peculiar elongated shape of the tumor the features were indistinguishable from a pyogenic abscess.

---

\* Department of Pathology, University of Dar es Salaam.

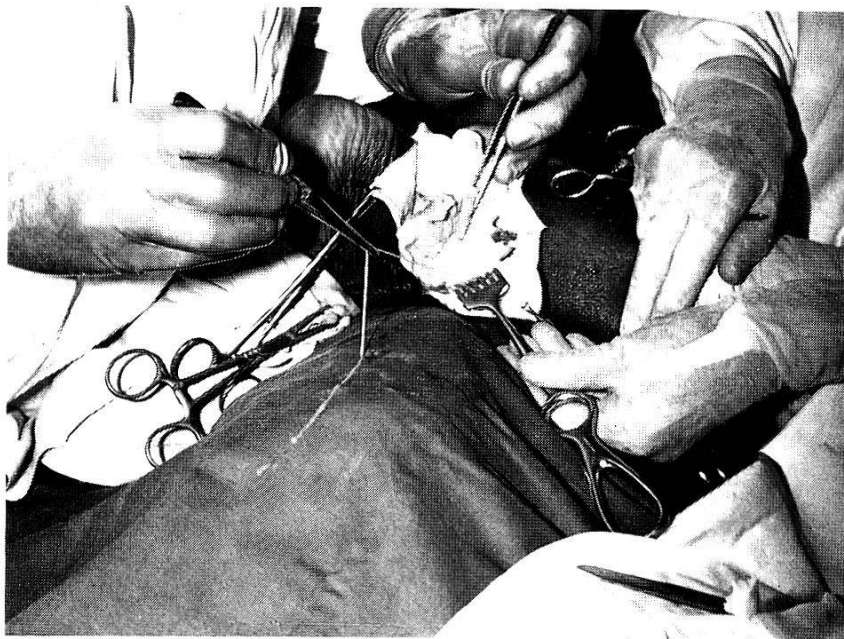
\*\* Wasso Hospital, Loliondo, Tanzania.



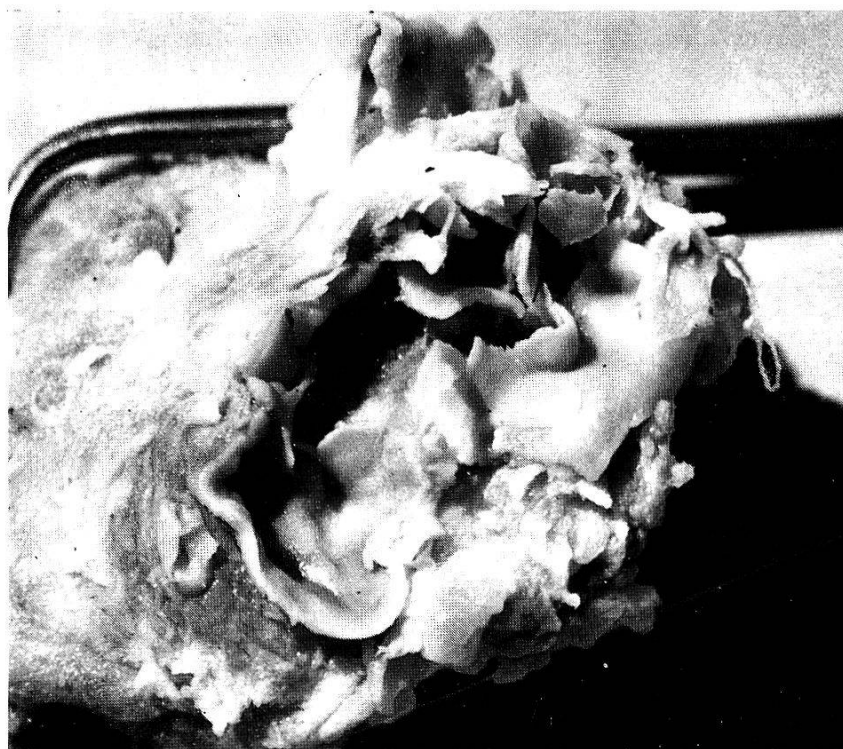
*Fig. 1.* Medial aspect of left ankle. Fluctuant retromalleolar swelling (note typical home made footgear of Masai). Case 1, Nashoi, male 32 years.

*Surgical examination of specimen*

(Fig. 2.) In the operating theatre approximately 10 ccm of pus and caseous discharge was released on both sides and a coiled up "worm" mass was revealed, composed of 6, respectively 4 narrow, flat, white "worms" of various lengths up to 10 cm. Some were seen to crawl sluggishly, others were motionless. The bulk was lying free in a cavity of the size of a dove's egg (Fig. 3), others were entangled in between shreds and bands of the wall whilst some were partially infiltrating



*Fig. 2.* Surgical removal: the cyst just has become detached from fibrous adhesions with the surrounding tissues. To show the parasite the wall of the cavity is split and one of the Plerocercoids stretched out by the forceps of the right hand of the surgeon in the left upper corner. Case 1, Nashoi, male 32 years.



*Fig. 3. Opened cyst. Thick fibrous outer and smooth membranelike inner lining. (4 ×.) Case 1, Nashoi, male 32 years.*

the surrounding tissue. The attempts to remove entirely the tough fibrous tissue of more than 1 cm thickness and to extract all the worms failed. Inflammatory fibrous tissue deeply penetrated the medial side between the retinacula and the tendons of the peronei. The wound was stitched after insertion of a drain. Healing took place with considerable scarring.

#### *Case 2*

The patient was a male Masai (Malogwa, 12 years) from Mondarossi. He consulted the doctor (in May 1966) for a slightly painful swelling of his right foot. It had started three months previously on the lateral aspect of the foot in the premalleolar region. The swelling was intermittently increasing and decreasing in size at first without showing any inflammation. One month later, when it had reached the size of a plum, it ruptured spontaneously releasing some discharge. The fistula thus formed healed rapidly over approximately two weeks. The patient was never seriously impeded by the lesion.

#### *Physical examination*

The patient presented a single sharply outlined oval swelling measuring 5 × 3 cm in the right premalleolar region overlaying the bony prominence of the cuboid bone. It was situated subcutaneously and firmly attached to the tissue beneath. The covering skin was not inflamed.

#### *Surgical examination of specimen*

When the swelling was opened a small amount of turbid watery fluid escaped and out of a cystlike cavity three coiled up, white, nonsegmented narrow, flat "worms" each of 6 to 8 cm length were removed. The wall of the cavity was 4 mm

thick, the inner lining was shiny membranelike but not detachable. The outer layers were attached to the underlying fascial coverings by some fibrous bands which also involved the tendons of the superficial extensors. Stitches were inserted and the wound healed rapidly.

### *Case 3*

The patient was a male Masai (Olongishei, 50 years) from Arrash, attending the hospital in November 1970. Approximately 10 months before he had noticed a swelling on his right elbow. Initially it was just a narrow slightly reddened ridge. The patient attributed it to an external superficial injury. The swelling, however, steadily increased and four months after the date of onset it had reached the size of a plum. In the following months alternating with periods of remission the swelling became itchy and painful, and two months before admission to the hospital the patient noted for the first time considerable redness and heat.

#### *Physical examination*


The patient presented an oval swelling of 4 to 2 cm situated between the olecranon and the medial epicondyle of the right arm. It was inflamed, fluctuating, fixed to the underlying tissue and to the epidermis. Touching and passive extension was painful. The patient was sent to the operating theatre with the diagnosis of a purulent bursitis.

#### *Surgical examination of specimen*

Incision displayed pus and, to the surgeons surprise, a coiled up "worm" mass, consisting of three flat nonsegmented "worms" of respectively 8, 6 and 3 cm. They were enclosed in a cystlike cavity whose wall was approximately 6 mm thick. Its fibrous outer layer blended imperceptibly into the superficial fascial coverings and was strongly adherent to them. Some debris was removed from inside the cavity, a drain inserted and the wound closed. The small burselike cavity became obliterated by granulation tissue within a few days without any complications.

### **The parasite (Fig. 4)**

Grossly the removed larvae were morphologically equal, ivory-white, ribbon-like, unsegmented and somewhat crinkled in shape, measuring from 3 to 10 cm in length and 2 mm in width, thickness 0.5 mm. Head and tail were indistinguishable to the naked eye, except when the "worm" was moving. There was, however, in some specimens clubbing of the anterior end by contraction and splitting of this terminal portion. Microscopically this gives the impression of a mouth opening with lips and cuticular flaps but corresponds (shown in longitudinal sections) to the invaginated scolex. In transverse sections the deeply eosinophilic cuticle was found to overlay a loose subcuticle followed by a parenchymal cell layer underneath. A few longitudinal and transversal muscle bands were lying superficially. There was no internal organisation demonstrable.



*Fig. 4.* Sparganid larva. Ribbonlike structure with pseudosegmentation by contraction visible in the anterior third and head (left side end). (3 ×.)

### **Histopathology**

In all three specimens the principal architecture of the wall encapsulating the tapeworm larvae is composed of three layers. The innermost lining (visible to the naked eye as a smooth membrane, Fig. 3) consists of granulation tissue. It is followed by highly vascularized but only moderately infiltrated fibrous tissue. The poorly defined boundary with healthy tissue is formed by a capsule of dense collagenous fibres. This basic pattern varies according to the stage of deterioration of the larvae and to the grade of reaction of the host.

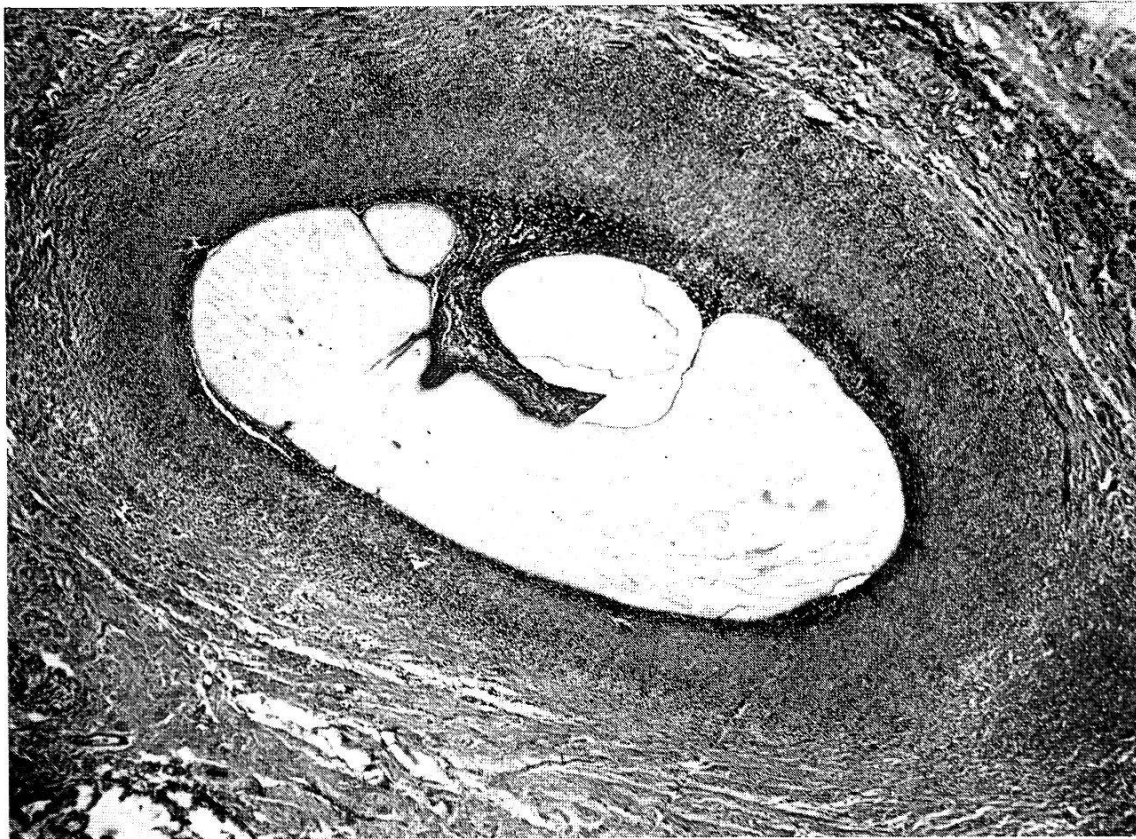
The larvae of case 2 show a perfectly well preserved cuticle. Flattened fibroblasts of the granulation tissue tightly ensheath the larval surface imitating a mesothelial surface (Fig. 5). Granulation tissue and outer fibrous capsule are infiltrated by numerous plasmocytes suggesting a high degree of cell mediated immunity (Fig. 6). In striking contrast to case 2 in specimen 1 and 3 there is infiltration by neutrophil leucocytes which is pronounced throughout the wall. These features correspond to a pyogenic abscess with formation of a pyogenic membrane. There are, in addition, numerous scattered eosinophils and histiocytic macrophages indicating the allergic and clearing reaction elicited by the breakdown products of the disintegrating parasite. The cuticle of the larvae has been melted away by leucocytes and considerable amounts of foreign antigenic substance may be released through these leaks (Fig. 7).

### **Comment**

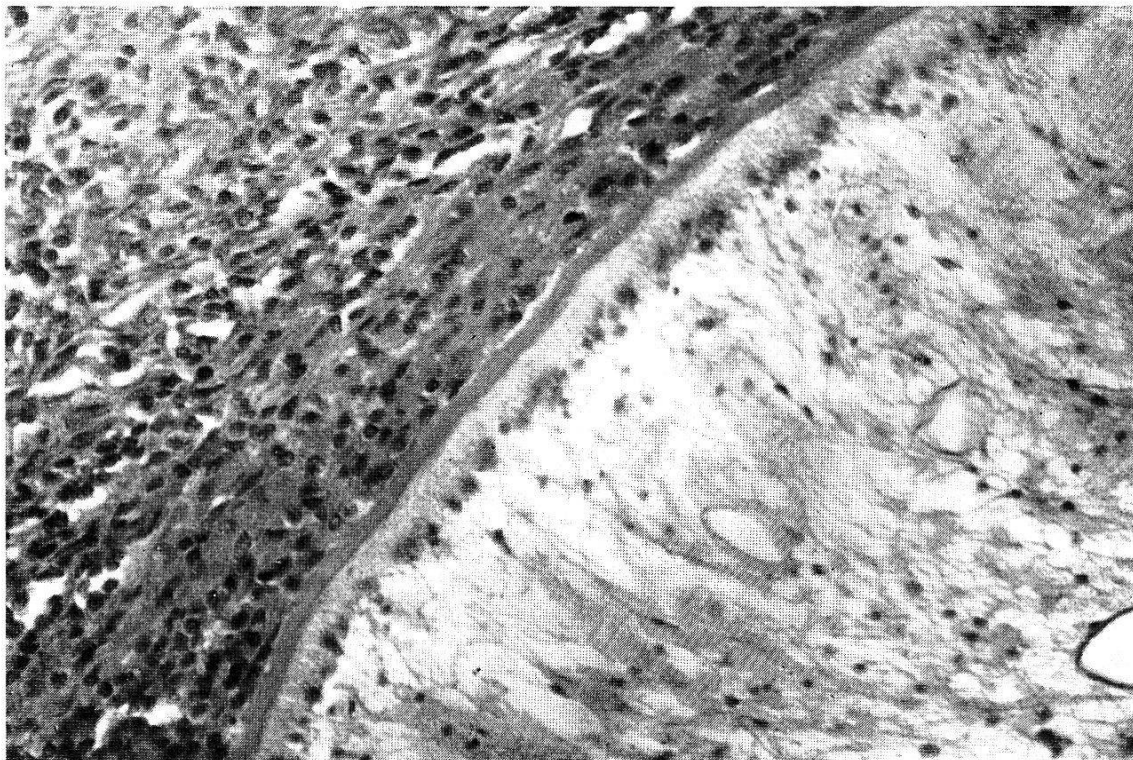
*Case review with special attention to East Africa  
and the Masailand*

Human sparganosis has a wide geographical distribution although especially associated with the Far East, having been reported chiefly

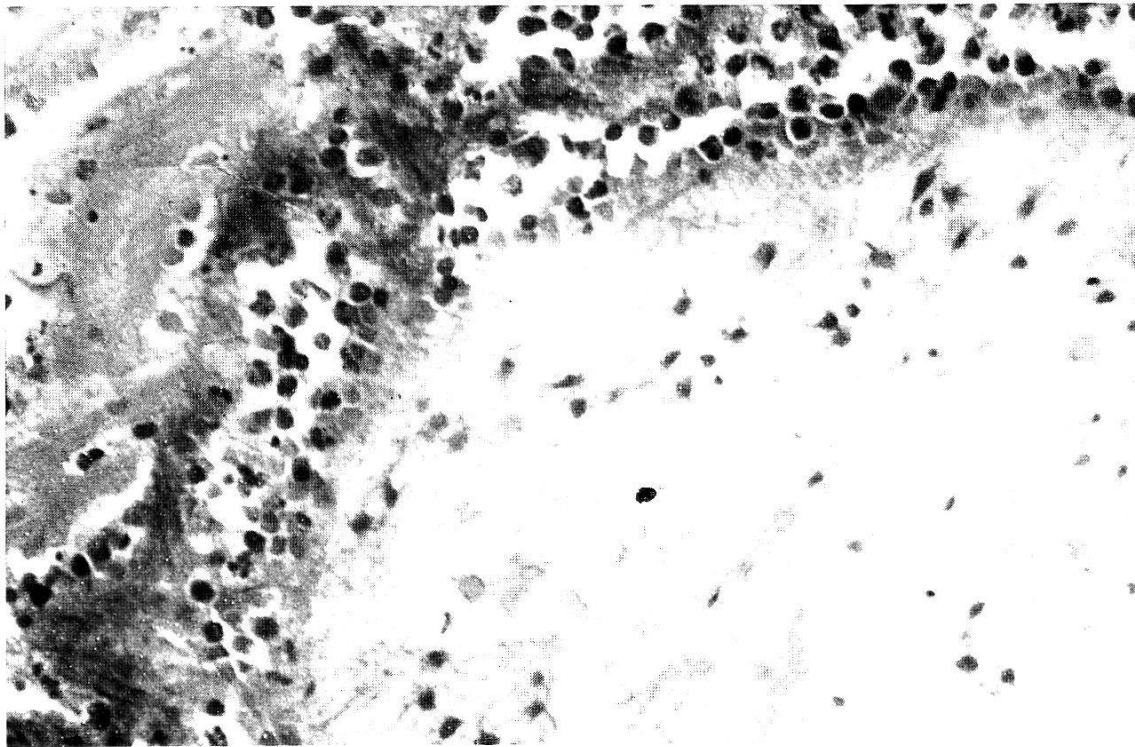




*Fig. 5.* Fibroblastic ensheathment of sparganum (20  $\times$ , HE). The coiled up larva is cut at three different levels. Details of larval coverings and surrounding host capsule are given in Fig. 6. Case 2, Malogwa, male, 12 years.



*Fig. 6.* Fibroblastic ensheathment of sparganum (right lower corner) intermingled with numerous scattered plasmacells. The larval body covered by an intact cuticle is showing a spongy mesenchymal tissue with interlacing muscle fibres. (30  $\times$ , HE.) Case 2, Malogwa, male, 12 years.



*Fig. 7.* Fragmentation of the larval cuticle by neutrophil leucocytes. The lower right corner analogous to Fig. 6 corresponds to the body of the disintegrating larva surrounded by leucocytic exsudate (left upper corner) (30 ×, HE). Case 3, Olongishei, male, 50 years.

from Japan (MIYAKE 1904), Korea (WEINSTEIN et al. 1954), Indonesia (BONNE 1942), China (CAMPBELL et al. 1936) and Indochina (HOUDERMER 1934). It is also sporadically encountered in Australia (CLELAND 1918, SANDARS 1954), Europe (PUJATTI 1953), South- and North America (SWARTZWELDER 1964, MUELLER 1966). A most comprehensive summary is given by HUANG 1962.

For Africa (East Africa excluded) 6 human cases have been reported, from Gabon (HARANT 1948), French Equatorial Africa (DESCHIENS 1953), Rhodesia (ALVES 1954), Congo (FAIN & PIRAUX 1959), Liberia (BRUIJNING 1960) and Madagascar (BRYGOO 1961). For the distribution of lesions see table I.

The relevant details of cases observed in East Africa are given in table II. Besides these 8 publications the existence of sparganosis has only been confirmed and briefly mentioned on the following occasions: NELSON (1965) received spargana from 3 Kenyan Masais and from one Tanzanian Masai from the Serengeti plains, all four presenting with abscesses of the ankle. Furthermore, he was informed (by CLYDE) of three similar cases in Tanzanian Masais from the Serengeti. One of us, acting for 8 years as "Doctor of the Masais", has gained the impression from several personal communications with medical staff in the Masailand that sparganum infections of the ankle are fairly frequently seen in the area.



Table I. Site of lesions in African-Sparganosis

Site of lesions	Number of cases	
	Africa (including East Africa)	East Africa
<i>Subcutaneous</i>		
Ankle region	16 (!)	16 (!)
Thigh	3	1
Chest	1	—
Elbow	1	1
<i>Inter or Intramuscular</i>		
Popliteal muscle	2	1
Rectus abdominis muscle	1	—
<i>Others</i>		
Hernia (spermatic cord)	2	2
Intestines	1	1
Eye	2	2
<i>Generalized</i>	1	—
Total	30	24

Thus, including all these cases, we can draw the following conclusions: Firstly, comparing the total of 30 cases in Africa with the total of 24 cases in East Africa, that the disease is prevalent in East Africa, and within East Africa prevalent in the Masailand. Out of 24 East African sparganoses 16 are found in Masais or Pokots. Both are ethnologically closely related, seminomadic cattle-breeders with almost equal customs, living in the same environmental conditions. Secondly, that there is a peculiar distribution of lesions in East African sparganosis. From 24 cases 17 present with ankle lesions and all but one are Masais or Pokots.

*The connections between the life cycle of the parasite  
and the mode of transmission*

Two main groups of sparganoses can be distinguished: (1) *Sparganum mansoni* infections (adult: *Diphyllbothrium mansoni* SCHEUBE 1881 after PIEKARSKY 1954), common in the Far East. (2) *Sparganum mansonioides* infections (adult: *Diphyllbothrium mansonioides* MUELLER 1938), common in the United States. Classification of the closely related species by minor morphological varieties is the field of the specialist helminthologist (WARDLE & McLEOD 1952).

The sexually mature cestode lives in domesticated and wild carnivores. The eggs embryonate in water into the ciliated larvae (coracidium) which is taken up by a copepod (Cyclops) where it develops to pro- and plerocercoids. The copepods are eaten by mammals, birds, amphibians,

*Table 2. Detailed account on published cases of Sparganosis in East-Africa*

Author	Year	Place	Tribe	Sex	Age (years)	Site and nature of lesion	Reference
SAMBON, B.	1907	Kenya	Masai	male	20	Abscess of the size of fist right thigh	Proc. zool. Soc. London; 282
DE MEILLON, B.	1943	Uganda	Muganda	male	40	Incidentally found in the sac (spermatic cord) of inguinal hernia at operation	S. afr. med. J. 17, 289
KIREMERWA, D. N.	1956	Uganda	Lango	male	45	Cyst-like swelling of bulbar conjunctiva, medial canthus	E. afr. med. J. 33, 37
BUCK, C.	1959	Uganda	Muganda	male	50	Incidentally found in the sac (spermatic cord) of inguinal hernia at operation	Trans. roy. Soc. trop. Med. Hyg. 53, 303
JONES, D. W. E.	1962	Uganda	(Bantu) Muganda	male	56	Tumour of descending colon	Brit. J. Ophth. 46, 123
COX, P. S. V.	1962	Kenya	Suk	male	12	Abscess left lateral ankle	Trans. roy. Soc. trop. Med. Hyg. 48, 87
FOSTER, R.	1964	Tanzania	Mfiome	female	40	Swelling left lateral ankle	E. afr. med. J. 42, 2
COX, P. S. V.	1965	Kenya	Pokot	5 males	adult	Abscesses of lateral ankle	E. afr. med. J. 42, 6
			1 male	adult		Abscess of popliteal muscle	(correspondence)

and reptiles which in that way accumulate the plerocercoid larvae or spargana and may become highly infective (TAKAHASHI).

Sparganosis may be transmitted to man by drinking cyclops infected water (MUELLER 1938, 1966) or any of the following practices: eating half cooked chicken (Japan, YOKOGAWA 1930), by eating raw snakes in the superstitious belief that this will combat fever (Korea, WEINSTEIN 1954), by the habit of steaming tadpoles (Indonesia, HUANG 1962), or frogs (Hongkong, Vietnam, HOUEMER 1934) over rice, and finally of applying poultices from flesh of the above-named animals onto inflamed eyes or sores of the skin. Infected wild and domesticated pigs might be the source of infection in the United States (CORKUM 1966) and in Africa (DINNIK 1969).

### Sparganosis in the Masailand

The bulk of sparganum infections in the Masailand seems to be localized to the ankle region. One is tempted to suggest that the lesions described were acquired by standing in ponds containing cyclops infected water. Direct infection by proceroid larvae through the unbroken skin is possible, as shown by YOKOGAWA (1930) in the monkey. Comparative pathology, however, allows another conceivable interpretation (see sparganosis in wild animals). In herbivores as in hyaenas the site of predilection of the lesion was similar to those of the 16 Masais or Pokots namely around the ankle joint. The form of elongated nodes of fibrous tissue in close contact with the tendon sheaths are identical. It can be regarded as a result of the form of reaction at an anatomical site where the migrating larvae are most likely to be trapped similar to the phenomenon occurring in onchocerciasis over bony prominencies.

Larval stages of cestodes in general (WEINMANN 1969) and spargana in particular (MUELLER 1961) are unusually immunogenic. *Sparganum mansonoides* infections in monkeys induced a condition similar to elephantiasis of the legs, related to the growth of fibrous tissue and obstruction of lymphatic channels elicited by the migrating larvae. In monkeys previously vaccinated with antigens the hosts' reaction was sufficiently strong enough to wall off spargana in tough cysts preventing migration and elephantiasis. If one compares the above reactions with the described cases of clearly circumscribed thick walled lesions of the ankle (Fig. 6) in the absence of any lymphatic obstruction one is bound to assume that infection has taken place in previously immunized subjects.

In NELSON's (1965) survey on cestode transmission in wild animals attention was drawn to the spotted hyaena (*Crocuta crocuta*). Out of 22 hyaenas examined in the Masailand 14 found to harbour

*Diphyllbothrium pretoriense* belonging to the mansonii-mansonioides group. An earlier report from BAYLIS (1937) describes the findings of both adults (*D. pretoriense*) and spargana in a spotted hyaena in Tanganyika. Diphyllbothriidae have also been found in the Masai-dogs (NELSON 1965). DINNIK (1969) confirms the frequent and heavy infestation of Serengeti-hyaenas simultaneously by cestodes and spargana. In addition he discovered spargana in various antelopes, in the buffalo, the zebra, the lion and the leopard. In the wart-hog spargana have been found frequently and in a heavy load of parasites widespread all over the body with preference to structures of the head (neck-head musculature, tongue, floor of mouth), findings which alarm connoisseurs of "Ngiri" meat (warthog) in East Africa.

NELSON (1965) conceived the idea of a probable connection between the hyaenas and the still used custom of the Masais of carrying their dead into the bush. He attempted to postulate man as an obligatory intermediate host of sparganid larvae, the adult cestode being maintained in nature by hyaenas. However, the wide range of demonstrated infected animals allows to state that the hyaena in its function as scavenger acts (besides becoming definitive host) as a cumulative intermediate host of sparganid larvae taken in by the flesh of various herbivores. The presence of both stages of development in the hyaena confirms the Euryxenia of the spargana, the ability to maintain the larval stage through a number of hosts (KOTLAN 1960).

Despite the wide range of infected eatable game the infection of Masais and Pokots does not fit into the picture because they feed almost exclusively on cattle (milk, blood and meat) and never eat game meat. Infections as acquired in the Far East by consumption or application of raw flesh of amphibians or reptiles is entirely out of the question. Two sources of infection remain possible: cattle and a copepod in the water. I was assured by veterinarians of the region that sparganosis in cattle is not known. They admit, however, that sporadic cases may easily escape detection as no regular meat inspection can be done.

According to my superficial survey of 6 waterholes cyclops were present in two of them. The average number in several specimens taken was 2 per deciliter. In dry seasons several of these ponds dry out entirely while in the few remaining a considerable accumulation of copepods can be expected and certainly these few accessible sources of water are becoming very much frequented by man and animals.

Sparganosis in the Masailand is no doubt a zoonosis in which water (cyclops = first intermediate host) constitutes the most probable link between canidae (hyaena, dog = definitive hosts) and man (incidental second intermediate host). Transmission to man is essentially the same as to the innumerable different herbivores which form the inexhaustible reservoir of common second intermediate hosts of sparganid larvae.



## References

- ALVES, W. D., GELFAND, M. & WEINBERG, R. (1954). A case of sparganosis in an African from Portuguese East Africa. – Trans. roy. Soc. trop. Med. Hyg. 48, 87–88.
- BAER, J. G. (1955). Un nouveau cas de parasitisme d'un enfant en Afrique orientale par le cestode *Inermicapsifer arvianthidis* (Kofend, 1917). – Acta trop. 12, 174–176.
- BAER, J. G. (1956). The taxonomic position of *Taenia madagascariensis* Davaine, 1870, a tapeworm parasite of man and rodents. – Ann. trop. Med. Parasit. 50, 152–156.
- BAER, J. G. (1959). Helminthes parasites. 163 pp. ill. – Rep. Explor. Parcs Nat. Congo belge. Fasc. 1.
- BAER, J. G. & FAIN, A. (1955). Cestodes. – Rep. Explor. Parcs Nat. de l'Upemba. Fasc. 36.
- BAYLIS, H. A. (1937). Note on *Acuaria (Echinuria) decorata* Cram, 1927 (nematode). – Ann. Mag. nat. Hist. Ser. 10, 20, 436–438.
- BONNE, C. (1942). Researches on sparganosis in the Netherlands East India. – Amer. J. trop. Med. Hyg. 22, 643–645.
- BRUIJNING, C. F. A. & DE JONGH, R. T. (1960). A case of human sparganosis in Liberia. – Trop. geogr. Med. 12, 356–358.
- BRYGOO, E. R. & CATALA, P. (1961). Premier cas de sparganose humaine à Madagascar. – Arch. Inst. Pasteur Madagascar 29, 75–77.
- BUCK, S. C., PESTER, F. R. N. & BUCKLEY, J. J. C. (1959). 1. “*Sparganum*” from man, Uganda. 2. “*Tetrahyridium*” from genet cat, Kenya. – Trans. roy. Soc. trop. med. Hyg. 53, 303–304.
- CAMPBELL, H. E., WEBSTER, J. L. H. & LI, S. Y. (1936). Human sparganosis in the Foochow area. – China med. J. Suppl. I, 423–433.
- CLELAND, J. B. (1918). The occurrence of *Sparganum* (larval cestode) in the subcutaneous tissues of man in Australia. – Med. J. Austral. 2, 239–240.
- CORKUM, K. C. (1966). Sparganosis in some vertebrates of Louisiana and observations on a human infection. – J. Parasit. 52, 444–448.
- COX, P. S. V. (1965). Six cases of sparganosis from South Karamoja. – E. afr. med. J. 42, 319–320.
- DESCHIENS, R. et al. (1953). Sur un nouveau cas africain de sparganose humaine. – Bull. Soc. Path. exot. 46, 958–961.
- DIESING (1845). In: LAPAGE, G. Veterinary parasitology. 2nd ed. p. 442–443. – Edinburgh and London: Oliver and Boyd 1968.
- DINNIK, J. A. & SACHS, R. (1969). Zystizerkose, Echinokokkose und Sparganose bei wildlebenden Herbivoren in Ostafrika. – Vet. med. Nachr. Nr. 2, 112–122.
- FAIN, A. & PIRAUX, A. (1959). Sparganose chez l'homme et les animaux au Ruanda-Burundi. – Bull. Soc. Path. exot. 52, 804–808.
- FAUST, E. C. (1965). Clinical parasitology, p. 622–626, Philadelphia: Lea & Febiger.
- HARANT, H., LAPEYSSONNIE, L. & LANCIER (1948). Sparganose kystique chez un Noir du Gabon. – Bull. Soc. Path. exot. 41, 666–667.
- HOUEMER, D. & CORNET, E. (1934). Les sparganoses animales oculaires en Indo-Chine et la sparganose. – Ann. Ocul. 171, 311–338.
- HUANG, C. T. & KIRK, R. (1962). Human sparganosis in Hong Kong. – J. trop. Med. Hyg. 65, 133–138.
- HUDSON, J. R. (1933). A list of cestodes known to occur in East African mammals, birds and reptiles. – J. East Afr. Uganda nat. Hist. Soc. Nos. 49–50, 205–217.
- KOTLAN, A. (1960). Helminthology, pp. 199–226. Budapest: Academiae Kiado.
- MIYAKE, H. (1904). Beiträge zur Kenntnis des *Bothriocephalus liguloides*. – Mitt. Grenzgeb. Med. Chir. 13, 145–154.

- MUELLER, J. F. (1938). Studies on *Sparganum mansonoides* and *Sparganum proliferum*. – Amer. J. trop. Med. 18, 303–328.
- MUELLER, J. F. (1961). The laboratory propagation of *Spirometra mansonoides* as an experimental tool. V. Behavior of the Sparganum in and out of the mouse host, and formation of immune precipitates. – J. Parasit. 47, 879–881.
- MUELLER, J. F. (1966). In: MCCAULEY, J. F. (ed.) Host-parasite relationships, pp. 15–58. – Corvallis: Oregon State University Press.
- MUELLER, J. F. (1966). The laboratory propagation of *Spirometra mansonoides* (MUELLER, 1935) as an experimental tool. VII. Improved techniques and additional notes on the biology of the cestode. – J. Parasit. 52, 437–443.
- NELSON, G. S., PESTER, F. R. N. & RICKMAN, R. (1965). The significance of wild animals in the transmission of cestodes of medical importance in Kenya. – Trans. roy. Soc. trop. Med. Hyg. 59, 507–524.
- PUJATTI, D. (1953). Un caso di sparganosi umana. – Riv. Parassit. 14, 213–217.
- SACHS, R. & SACHS, C. (1968). A survey of parasitic infestation of wild herbivores in the Serengeti region in northern Tanzania and the Lake Rukwa region in southern Tanzania. – Bull. epizoot. Dis. Afr. 10, 145.
- SANDARS, D. F. (1954). A Sparganum from a Queensland woman. – Med. J. Austral. 2, 817–818.
- SCHEUBE. Quoted in PIEKARSKY: Parasitologie. Berlin: Springer 1954.
- SWARTZWELDER, J. C., BEAVER, P. C. & HOOD, M. W. (1964). Sparganosis in southern United States. – Amer. J. trop. Med. Hyg. 13, 43–47.
- WARDLE, R. A. & MCCLEOD, J. A. (1952). The zoology of tapeworms. pp. 1–780. – Minneapolis: Univ. Minnesota Press.
- WEINMANN, J. C. (1969). London: Academic Press, pp. 301–320.
- WEINSTEIN, P. P., KRAWCZYK, H. J. & PEERS, J. H. (1954). Sparganosis in Korea. – Amer. J. trop. Med. Hyg. 3, 112–129.
- YOKOGAWA, S. & KOBAYASHI, H. (1930). On the species of *Diphyllbothrium mansonii* sensu lato, and on the infectious mode of human sparganosis. – Far Eastern Ass. trop. Med. Trans. 8th Congress, Siam, 1930, vol. 2, pp. 214–226.

### Zusammenfassung

Beschrieben werden drei Fälle von Sparganose in Masais. Nach Durchsicht der Literatur und unter Einbezug jeglicher Informationen wird es klar, daß Sparganose innerhalb Afrikas im Masailand prevalent ist. Sie zeigt sich dort vorherrschend in Form von Schwellungen im Bereiche des Sprunggelenkes, möglicherweise bedingt durch die Art des Eintrittes der Larve. Der Zusammenhang mit einer Reihe von mit Sparganose infiziertem Wild wird diskutiert im Lichte neuerer Resultate veterinärmedizinischer Forschung in der Serengeti.

### Résumé

Trois cas de sparganoses chez les Masais sont décrits. Après une étude bibliographique et après avoir recueilli toutes les informations possibles, il apparaît nettement que la sparganose africaine est particulièrement fréquente dans le pays Masai. Elle se manifeste principalement sous la forme d'une enflure dans la région du jarret, probablement due au mode d'entrée de la larve. Le rapport entre sparganose humaine et sparganose animale est discuté à la lumière de nouveaux résultats obtenus sur une série de gibier dans le cadre de recherches en médecine vétérinaire effectuées dans la Serengeti.