

# **Cytokeratin filaments of the liver of BALB/C-Mice as a sensitive model for liver damages : computer-aided characterization with the help of the image analysing system "IBAS"**

Autor(en): **Steinmann, J. / Kohler, M. / Aufderheide, M.**

Objektyp: **Article**

Zeitschrift: **Schweizer Archiv für Tierheilkunde SAT : die Fachzeitschrift für Tierärztinnen und Tierärzte = Archives Suisses de Médecine Vétérinaire ASMV : la revue professionnelle des vétérinaires**

Band (Jahr): **132 (1990)**

Heft 8

PDF erstellt am: **14.05.2024**

Persistenter Link: <https://doi.org/10.5169/seals-593705>

## **Nutzungsbedingungen**

Die ETH-Bibliothek ist Anbieterin der digitalisierten Zeitschriften. Sie besitzt keine Urheberrechte an den Inhalten der Zeitschriften. Die Rechte liegen in der Regel bei den Herausgebern.

Die auf der Plattform e-periodica veröffentlichten Dokumente stehen für nicht-kommerzielle Zwecke in Lehre und Forschung sowie für die private Nutzung frei zur Verfügung. Einzelne Dateien oder Ausdrucke aus diesem Angebot können zusammen mit diesen Nutzungsbedingungen und den korrekten Herkunftsbezeichnungen weitergegeben werden.

Das Veröffentlichen von Bildern in Print- und Online-Publikationen ist nur mit vorheriger Genehmigung der Rechteinhaber erlaubt. Die systematische Speicherung von Teilen des elektronischen Angebots auf anderen Servern bedarf ebenfalls des schriftlichen Einverständnisses der Rechteinhaber.

## **Haftungsausschluss**

Alle Angaben erfolgen ohne Gewähr für Vollständigkeit oder Richtigkeit. Es wird keine Haftung übernommen für Schäden durch die Verwendung von Informationen aus diesem Online-Angebot oder durch das Fehlen von Informationen. Dies gilt auch für Inhalte Dritter, die über dieses Angebot zugänglich sind.

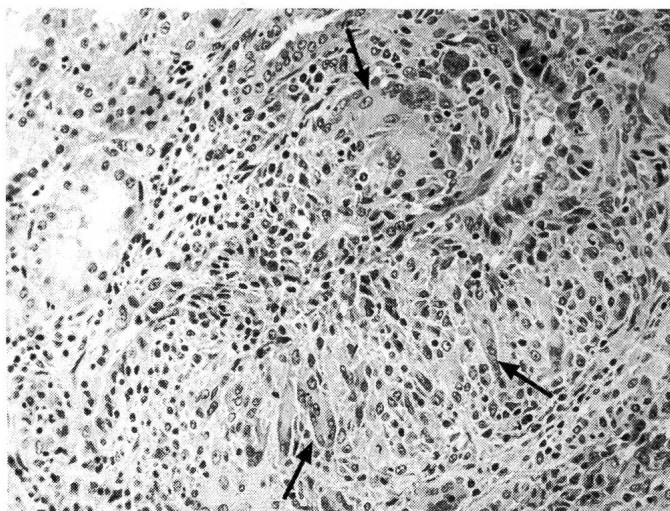


Fig. 1: Granulomatous reaction with the presence of multinucleated giant cells (arrows). Hematoxylin and eosin, 160x.

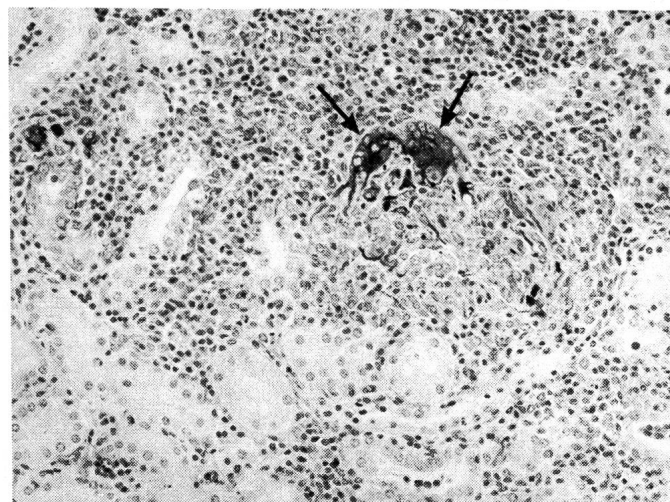


Fig. 2: Intense immunoreactivity for vimentin is detectable in the cytoplasm of two giant cells (arrows). Immunoperoxidase for vimentin, hematoxylin counterstain, 200x.

ted in the cytoplasm of degenerating tubular cells. In few cases leptospiral antigen was detected in the cytoplasm of giant cells. Moreover, these cells showed a variable positive reaction when tested with the monoclonal antibody against vimentin (fig. 2). In 4 out of 12 cases isolation attempts for leptospire were carried out. All the 4 cases resulted positive and the isolates were belonging to the *pomona* serogroup.

The presence of multinucleated giant cells in renal lesions strikingly suggestive of granulomata has been described in cattle naturally or experimentally infected with serovar *pomona* (1, 2). These giant cells were considered to develop from tubular epithelium. However, in our

cases some findings suggest the monocytic-macrophagic origin of these cells. In fact their cytoplasm was PAS positive, reacted positively to vimentin immunolabelling and they were frequently observed adjoining to degenerating tubules. Therefore, it may be suggested that the granulomatous-like reaction might be directed against tubular structures containing leptospiral antigen.

## References

1. Hadlow W. J., Stoenner H. G. (1955): Am. J. Vet. Res. 16, 45–56.
- 2. Spradbrow P. B., Seawright A. A. (1963): Austral. Vet. J. 39, 423–433.

Hannover Medical School, Inst. Experimental Pathology, FRG

## CYTOKERATIN FILAMENTS OF THE LIVER OF BALB/C-MICE AS A SENSITIVE MODEL FOR LIVER DAMAGES. COMPUTER-AIDED CHARACTERIZATION WITH THE HELP OF THE IMAGE ANALYSING SYSTEM «IBAS»

J. Steinmann, M. Kohler, M. Aufderheide, U. Mohr

The cytoskeleton represents a complex structural network which is of major importance both for the structural integrity and the physiologic processes of the cell (1; 2; 3). Damages of the cytoke-  
 ratin filament organisation and dysregulation of the keratin metabolism are regarded as responsible mechanisms leading to alteration of cell function, cell death or transformation (4; 5).

The aim of the present investigation was to test whether liver-damaging influences can be detected through changes in the liver cytoke-  
 ratin filaments as one important component of the liver cytoskeleton. The iron storage behaviour of the liver was investigated as a comparative marker for induced liver alterations (data not shown).

## Material and methods

In the animal experiment 10 male and 10 female mice per group were treated according to UCHIDA and HIRONO (14) with dimethyl-

nitrosamine (DMNA/Phenobarbital, group II) or colchizine (group III), respectively. The control group (group I) remained untreated. The histologic changes in different locations of the liver tissue were characterized by light and fluorescence microscopy (primary antibody AB: Antikeratin Bio Yeda, secondary AB: AMCA-Anti-guinea pig) and keratin alterations were quantified with the image analysing system «IBAS» (Zeiss). After image-preparing steps, areas without tissue components were eliminated to get the reference area. Subdividing the grey value spectrum of the remaining picture into phases with grey values ranging from 0–90, 91–150 and 151–255 it was possible to discriminate weakly, moderately and intensively fluorescing keratin components and to measure their corresponding area. The area percentage of the reference area and the areas with low (LKF<sub>ind</sub>), moderate MKF<sub>ind</sub>) and high fluorescence intensity (HKF<sub>ind</sub>) were defined as keratin indices of the corresponding fluorescence

intensity. For statistical evaluation an ANOVA-test with the SAS-system (software release No 148270010) was carried out.

## Results

Group II developed hepatocellular adenomas with an overall tumor incidence of 55% (11/20). 36% of the tumor bearing animals showed multiple adenomas. The colchizine-treated group showed some intranuclear inclusion bodies. Investigation of the liver cytokeratin filaments in the DMNA group by indirect immunofluorescence showed a marked tendency towards keratinization of the liver cells with different morphologic features. This strong keratinization did not indicate any sex-dependent behavior and could be measured quantitatively in the form of a highly significant increase of the parameter HKF<sub>Ind</sub> compared to the control ( $p < 0.001$ ). The colchizine group did not display any structural changes compared with the control group, but image analysis of the keratin filaments revealed that the males of the colchizine group had significantly greater values for the parameter LKF<sub>Ind</sub> whereas the values for the parameter HKF<sub>Ind</sub> were significantly smaller than for the control males ( $p < 0.001$ ). No group showed lobe-specific differences concerning the induced keratin alterations (see figure 1).

## Discussion

In the liver cells of the DMNA-treated group a general condensation of the cytoplasmic keratin network could be observed. It was partly accompanied by both non-filamentous keratin conglomerates which were in close contact to the cytoplasmic network and with a general irregular thickening of the pericytoplasmic keratin bands with a clod-like morphology.

Thus the classical concept of Mallory body (MB) formation, the best known pathologic keratin alteration in liver cells, (6; 7; 8; 9; 11; 12; 13) has to be extended in as far that MB formation can also be a combination of keratin conglomeration which leads to polymorphic non-filamentous structures and a condensation of the cytoplasmic

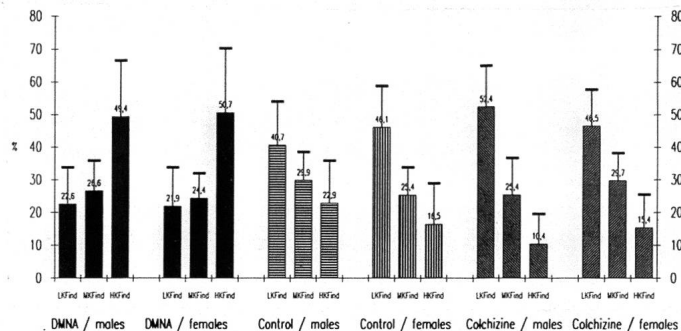


Fig. 1: Area percentage (%) of the different keratin indices of both sexes of the control, DMNA and colchizine groups

keratin network. Besides this keratinization, a general loss of keratin components can be a further expression of toxic damages of liver cells, as observed after colchizine treatment. Liver cytokeratin filaments could be morphologically and quantitatively characterized as sensitive indicators for induced liver damages.

## References

1. Fey E. G. et al. (1884): J. Cell Biol. 98, 1973–1984.
2. Fey E. G., Penman S. (1985): Hepatology 5, (1), 152–158.
3. Gerace L. (1986): Trends biochem. 11, 443–446.
4. Borenfreund E. et al. (1981): Hepatology 1, (5), 408–415.
5. Mukunda B. R. (1987): Human Pathol. 18, (1).
6. Christoffersen P. (1972): Acta path. microbiol. scand. Section A 80.
7. Denk H. et al. (1979): Proc. Natl. Acad. Scie. USA 76, (8), 4112–4116.
8. Denk H. et al. (1981): Hepatology 9–20.
9. Denk H., Franke W. W. (1981): Europ. J. Cell Biol. 23, 241–249.
10. Kimoff R. J., Huang S. N. (1981): Lab. Invest. 45.
11. French S. W. (1983): Pathol. Lab. Med. 107.
12. Okanoue T.M. et al. (1985): Lab. Invest. 53, (5), 534–540.
13. Mukunda B. R. (1987): Human Pathol. 18, (1).
14. Uchida E. Hirono E. (1979): Gann. 70, 639–644.

Institute of Pathology, Hannover Veterinary School, FRG

## MORPHOLOGICAL CHARACTERISATION OF BOVINE MESOTHELIOMA

N. Stockhofe-Zurwieden, M. Stöber, J. Pohlenz

Mesotheliomas are rare tumors in the bovine species with an incidence of about 1.6% (Klopfer et al., 1983). Generally they are described as diffuse tumorous proliferations on the peritoneal surface but they also occur on the pleural and pericardial serosa.

## Material and methods

In this retrospective study 13 cases of bovine mesotheliomas of the last 16 years were re-evaluated. 10 of the 13 cases were necropsied, from 3 cases only biopsy specimens were available. The material had been fixed in 10% formalin. Paraffin-embedded tissues stained with hematoxylin-eosin were examined by light microscopy. For additional histochemical studies tissue sections were stained with Periodic-acid-Schiff (PAS) with and without diastase digestion, alcian-blue and Meyers mucicarmine. To detect ferruginous bodies sections

were stained with Turnbull-blue. Electronmicroscopical investigations were carried out in two cases on glutaraldehyde (5%) fixed tissue.

## Results

Out of the 13 cases 5 animals were younger than 10 weeks, 3 animals between 4 months and 1 year and 5 animals were older than 5 years. The latter group consisted of cows only, whereas the first two groups included 5 males and 1 heifer.

The peritoneal cavity was predominantly affected. The tumor spread over the visceral and parietal surface of the serosa. The scrotal cavity was involved in 4 bull calves, whereas in 6 cases the pleural, pericardial and peritoneal serosa contained tumors. Macroscopically the tumors revealed a diffuse distribution pattern with some of them having a pedunculated growth and others being sessile on the surface.