

# Granulomatous-like reaction in renal leptospirosis of swine

Autor(en): **Scanziani, E. / Sironi, G. / Caniatti, M.**

Objekttyp: **Article**

Zeitschrift: **Schweizer Archiv für Tierheilkunde SAT : die Fachzeitschrift für Tierärztinnen und Tierärzte = Archives Suisses de Médecine Vétérinaire ASMV : la revue professionnelle des vétérinaires**

Band (Jahr): **132 (1990)**

Heft 8

PDF erstellt am: **15.05.2024**

Persistenter Link: <https://doi.org/10.5169/seals-593704>

## **Nutzungsbedingungen**

Die ETH-Bibliothek ist Anbieterin der digitalisierten Zeitschriften. Sie besitzt keine Urheberrechte an den Inhalten der Zeitschriften. Die Rechte liegen in der Regel bei den Herausgebern.

Die auf der Plattform e-periodica veröffentlichten Dokumente stehen für nicht-kommerzielle Zwecke in Lehre und Forschung sowie für die private Nutzung frei zur Verfügung. Einzelne Dateien oder Ausdrucke aus diesem Angebot können zusammen mit diesen Nutzungsbedingungen und den korrekten Herkunftsbezeichnungen weitergegeben werden.

Das Veröffentlichen von Bildern in Print- und Online-Publikationen ist nur mit vorheriger Genehmigung der Rechteinhaber erlaubt. Die systematische Speicherung von Teilen des elektronischen Angebots auf anderen Servern bedarf ebenfalls des schriftlichen Einverständnisses der Rechteinhaber.

## **Haftungsausschluss**

Alle Angaben erfolgen ohne Gewähr für Vollständigkeit oder Richtigkeit. Es wird keine Haftung übernommen für Schäden durch die Verwendung von Informationen aus diesem Online-Angebot oder durch das Fehlen von Informationen. Dies gilt auch für Inhalte Dritter, die über dieses Angebot zugänglich sind.

injected intradermally with 100 µl of undiluted and 1:5 diluted zymosan-activated plasma (ZAP), bovine C5a, and  $10^{-13}$  M E. coli O 55 B:5 endotoxin (LPS) into the base of the tail. Pyrogen free saline (PFS) served as a control. 4 hrs later 6mm skin biopsies were punched out under local anesthesia and the tissue samples fixed in 4% formaldehyde, embedded in paraffin, processed routinely and stained with H&E and Lendrums chromotrop 3R.

By using a set score (0 to 4) for randomized evaluation of the inflammatory infiltrate in the upper (from the epidermis to the deepest adnexal structures) and lower (from the deepest adnexal structures downwards) dermis, we semiquantified the granulocyte number in each section. The scores for the two areas were then added to provide a total score for the section (possible range 0 to 8). The relative amount of PMN and eosinophils was evaluated by counting 200 cells, 100 in the upper dermis and 100 in the lower dermis, which allowed to calculate the corrected score (PMN only).

While few extravascular granulocytes were found 4 hours after injection of PFS in both age groups, all chemotaxins used induced a significant inflammatory reaction at the same time point in neonates and adults. Undiluted ZAP was more active than diluted ZAP, and the total intradermal granulocyte score was comparable in both age groups. The total intradermal granulocyte score after LPS was slightly but nonsignificantly higher in newborn calves, whereas C5a induced a significantly ( $P < 0.05$ ) stronger reaction in neonates. In newborn calves the inflammatory infiltrate was almost exclusively of neutrophilic (PMN) origin whereas in adults, a significant percentage of the cellular reaction consisted of eosinophils. The corrected score therefore provides a more differentiated pattern of reactivity. All three chemotactic agonists at all doses tested induced a significantly ( $P < 0.05$ ) more intense *neutrophil* infiltration in neonatal calves whereas the difference in the score values was not different in the PFS treated sites (see Fig. 1).

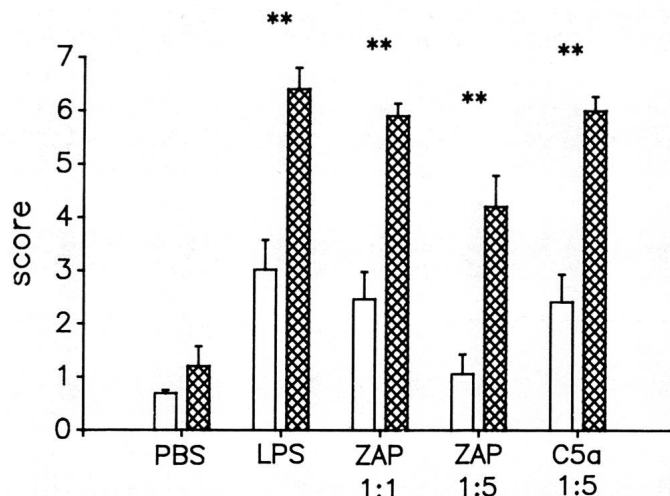


Fig. 1: Total score of neutrophil infiltrate in bovine skin 4 hours after injection of agonists or saline. The columns and the bars represent the mean  $\pm$  SEM of experiments done in five animals. Open bars: adult bovines; hatched bars: newborn calves. (Adults vs. newborns: \*\* $P < 0.01$ ).

The presented data indicate that the enhanced motility of neonatal PMN encountered *in vitro* correlates with the finding of this *in vivo* study. The functional repertoire of neutrophils and eosinophils differs, but many aspects of it still remains to be analyzed. Especially the details of eosinophil functions within an inflammatory tissue are still not well known, although the participation of this cell in allergic and parasitic processes is well recognized. Further studies should help to elucidate the competence of host defense in newborn calves *in vivo*.

Ist. Anatomia Patologica Veterinaria e Patologia Aviare, Università degli Studi, Milano, Italy

## GRANULOMATOUS-LIKE REACTION IN RENAL LEPTOSPIROSIS OF SWINE

E. Scanziani, G. Sironi, M. Caniatti

From January 1989 to March 1990 kidneys of 129 market weight pigs belonging to 25 different groups of animals were sampled at slaughterhouse and histologically examined. In these groups there was a high incidence of multifocal interstitial nephritis. Leptospiral infection was diagnosed on the basis of serology and/or bacteriological culture, and/or immunohistological staining.

Histologically, subacute to chronic interstitial nephritis was present in most of the kidneys. In mildly affected kidneys focal lymphocytic infiltration was present. In severely affected kidneys there were large foci consisting of lymphocytes and a variable number of neutrophils. Fibrosis, including scattered leukocytes, degenerating and regenerating tubules, was the main finding observed in chronic lesions.

In twelve cases granulomatous-like lesions were seen. Serial sections from these cases were stained with hematoxylin and eosin, periodic acid-Schiff (PAS), Ziehl-Neelsen and Gomori's Silver impregnation

and immunohistochemically tested with primary antisera against *Leptospira interrogans* serovar *pomona* (courtesy Dr. P. Mortarino) and vimentin (Dakopatts).

These granulomatous-like lesions were characterized by the presence of cells with large cytoplasm, some of them fused in small syncytia. Moreover, there were multinucleated giant cells which resembled those of the foreign body type (fig. 1). The number of giant cells varied greatly from one case to the next. Tubules partially disrupted and isolated tubular cells were commonly seen. Some giant cells were seen adhering to the basement membrane of tubules undergoing regressive changes. Lymphocytes were present both at the periphery of granulomas and in non granulomatous infiltrative foci. Ziehl-Neelsen stain consistently failed to detect acid-fast bacteria. PAS positive staining was observed in giant cells although this reaction varied greatly from one cell to the next. Immunoperoxidase for leptospiral antigen resulted positive in 10 out of 12 cases. The amount of leptospiral antigen was low; positive reaction was frequently detected

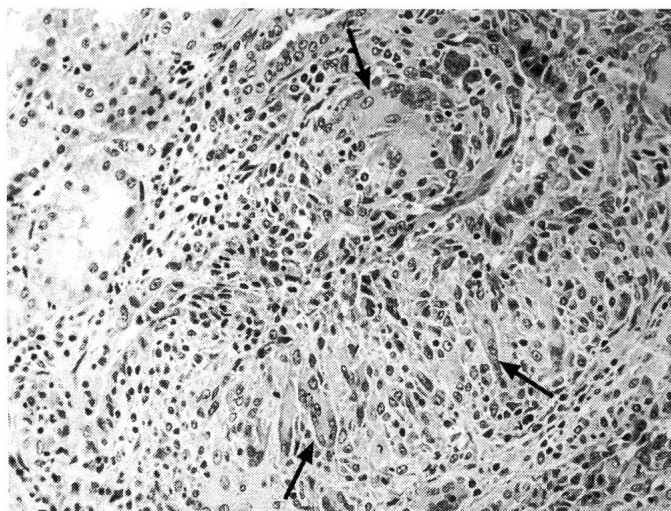


Fig. 1: Granulomatous reaction with the presence of multinucleated giant cells (arrows). Hematoxylin and eosin, 160x.

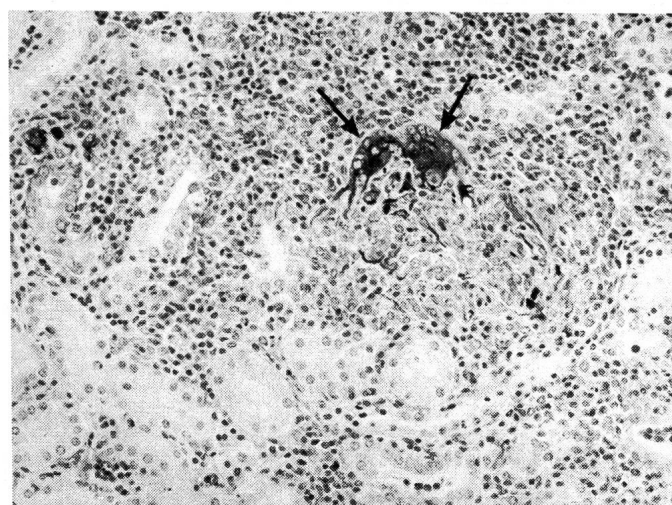


Fig. 2: Intense immunoreactivity for vimentin is detectable in the cytoplasm of two giant cells (arrows). Immunoperoxidase for vimentin, hematoxylin counterstain, 200x.

ted in the cytoplasm of degenerating tubular cells. In few cases leptospiral antigen was detected in the cytoplasm of giant cells. Moreover, these cells showed a variable positive reaction when tested with the monoclonal antibody against vimentin (fig. 2). In 4 out of 12 cases isolation attempts for leptospire were carried out. All the 4 cases resulted positive and the isolates were belonging to the *pomona* serogroup.

The presence of multinucleated giant cells in renal lesions strikingly suggestive of granulomata has been described in cattle naturally or experimentally infected with serovar *pomona* (1, 2). These giant cells were considered to develop from tubular epithelium. However, in our

cases some findings suggest the monocytic-macrophagic origin of these cells. In fact their cytoplasm was PAS positive, reacted positively to vimentin immunolabelling and they were frequently observed adjoining to degenerating tubules. Therefore, it may be suggested that the granulomatous-like reaction might be directed against tubular structures containing leptospiral antigen.

## References

1. Hadlow W. J., Stoenner H. G. (1955): Am. J. Vet. Res. 16, 45–56.
- 2. Spradbrow P. B., Seawright A. A. (1963): Austral. Vet. J. 39, 423–433.

Hannover Medical School, Inst. Experimental Pathology, FRG

## CYTOKERATIN FILAMENTS OF THE LIVER OF BALB/C-MICE AS A SENSITIVE MODEL FOR LIVER DAMAGES. COMPUTER-AIDED CHARACTERIZATION WITH THE HELP OF THE IMAGE ANALYSING SYSTEM «IBAS»

J. Steinmann, M. Kohler, M. Aufderheide, U. Mohr

The cytoskeleton represents a complex structural network which is of major importance both for the structural integrity and the physiologic processes of the cell (1; 2; 3). Damages of the cytoke-  
 ratin filament organisation and dysregulation of the keratin metabolism are regarded as responsible mechanisms leading to alteration of cell function, cell death or transformation (4; 5).

The aim of the present investigation was to test whether liver-damaging influences can be detected through changes in the liver cytoke-  
 ratin filaments as one important component of the liver cytoskeleton. The iron storage behaviour of the liver was investigated as a comparative marker for induced liver alterations (data not shown).

## Material and methods

In the animal experiment 10 male and 10 female mice per group were treated according to UCHIDA and HIRONO (14) with dimethyl-

nitrosamine (DMNA/Phenobarbital, group II) or colchizine (group III), respectively. The control group (group I) remained untreated. The histologic changes in different locations of the liver tissue were characterized by light and fluorescence microscopy (primary antibody AB: Antikeratin Bio Yeda, secondary AB: AMCA-Anti-guinea pig) and keratin alterations were quantified with the image analysing system «IBAS» (Zeiss). After image-preparing steps, areas without tissue components were eliminated to get the reference area. Subdividing the grey value spectrum of the remaining picture into phases with grey values ranging from 0–90, 91–150 and 151–255 it was possible to discriminate weakly, moderately and intensively fluorescing keratin components and to measure their corresponding area. The area percentage of the reference area and the areas with low (LKF<sub>ind</sub>), moderate MKF<sub>ind</sub>) and high fluorescence intensity (HKF<sub>ind</sub>) were defined as keratin indices of the corresponding fluorescence